



AALBORG UNIVERSITY
DENMARK

Aalborg Universitet

Confabulation resilience of the developing brain

A brief review

Christensen, Julie Nyvang; Sørensen, Thomas Alrik

Published in:
Journal of the International Neuropsychological Society

DOI (link to publication from Publisher):
[10.1017/S1355617719000134](https://doi.org/10.1017/S1355617719000134)

Publication date:
2019

Document Version
Publisher's PDF, also known as Version of record

[Link to publication from Aalborg University](#)

Citation for published version (APA):
Christensen, J. N., & Sørensen, T. A. (2019). Confabulation resilience of the developing brain: A brief review. *Journal of the International Neuropsychological Society*, 25(4), 426-431.
<https://doi.org/10.1017/S1355617719000134>

General rights

Copyright and moral rights for the publications made accessible in the public portal are retained by the authors and/or other copyright owners and it is a condition of accessing publications that users recognise and abide by the legal requirements associated with these rights.

- Users may download and print one copy of any publication from the public portal for the purpose of private study or research.
- You may not further distribute the material or use it for any profit-making activity or commercial gain
- You may freely distribute the URL identifying the publication in the public portal -

Take down policy

If you believe that this document breaches copyright please contact us at vbn@aub.aau.dk providing details, and we will remove access to the work immediately and investigate your claim.

SHORT REVIEW

Confabulation Resilience of the Developing Brain: A Brief Review



INS is approved by the American Psychological Association to sponsor Continuing Education for psychologists. INS maintains responsibility for this program and its content.

Julie Nyvang Christensen,¹ AND Thomas Alrik Sørensen²

¹Department of Neurology, Rigshospitalet, Copenhagen University Hospital, Glostrup, Denmark

²Aalborg University & Sino-Danish Center for Education and Research, Aalborg, Denmark

(RECEIVED July 21, 2018; FINAL REVISION January 9, 2019; ACCEPTED January 10, 2019)

Abstract

Objectives: To investigate a possible confabulation resilience of the developing brain. **Methods:** We performed a literature search on confabulation in PubMed and identified all empirical studies of children and adolescents under the age of 18. **Results:** The analysis identified only three case studies of confabulation in children under the age of 18 of 286 empirical studies of confabulation. This reveals a striking discrepancy in the number of reported cases caused by brain injury between children and adults. We hypothesize that there may be a resilience toward confabulation in the developing brain and present three tentative explanations regarding the possible underlying mechanisms. **Conclusions:** Additional awareness on the scarcity of reported cases of confabulation in children could lead to important insights on the nature of confabulation and greater understanding of the resilience and plasticity of the developing brain. (*JINS*, 2019, 25, 426–431)

Keywords: Acquired brain injury, Memory, Plasticity, Development, Children, Adolescents

INTRODUCTION

In the literature on confabulation caused by brain injury, there is a striking discrepancy in the number of cases of confabulations in adults compared to children. This discrepancy seems to support our clinical impression where we generally do not encounter the phenomenon in children. It has even been suggested that confabulation simply does not occur in children following head injury (Bowman & Blau, 1940). We propose that a focus on this discrepancy could potentially reveal important insights into the plasticity and resilience of the developing brain during childhood and adolescence and may yield a better understanding of the phenomenon itself.

The term “confabulation” seems to be used primarily in two slightly different contexts in the scientific literature, one focusing on confabulations following brain injury and the other related to forensic psychology, suggestibility, and research on the volatile nature of memory. Here, we distinguish between stories that seemingly arise from a limited memory access following a brain injury, and those that are based on access to memories that have been changed or

modified in otherwise healthy individuals. The focus of this review will be on the former.

Confabulation following brain injury is a condition where patients unintentionally, and in a non-confused state, seem to invent stories (or statements) that have little or no basis in present reality, but which the patients nevertheless perceive as real. This behavior is typically linked to an amnesic syndrome, and a degree of amnesia has been suggested as a necessary condition for the diagnosis of confabulation (Gilboa, 2010). Most lesion studies suggest involvement of orbitofrontal cortex, medial prefrontal cortex, the basal forebrain, or thalamus, especially the dorsomedial nucleus of thalamus (Gilboa & Moscovitch, 2002), and Schnider (2003) argues that confabulation occurs due to damage to an anterior limbic circuit, which includes the orbitofrontal cortex and structures associated with this area.

A common explanation of the phenomenon is that the lack of access to memory content drives the cognitive system to invent *ad hoc* explanations to fill in the gaps in memory of amnesic people (American Psychiatric Association, 1994). However, whether this explanation is correct has still to be convincingly determined. Several suggestions concerning the nature of confabulating behavior based on both lesion (Gilboa & Moscovitch, 2002; Schnider, 2003), clinical (Dalla Barba, 1993a) and experimental (Nahum, Bouzerda-Wahlen,

Correspondence and reprint requests to: Julie Nyvang Christensen, Department of Neurology, Rigshospitalet, Copenhagen University Hospital, Valdemar Hansens Vej 1-23 DK-2600 Glostrup, Denmark. E-mail julie.nyvang.christensen@regionh.dk

Guggisberg, Ptak, & Schnider, 2012) data have been proposed. The phenomenon has yet to be fully understood and research is still attempting to reveal the basic mechanisms involved.

Furthermore, confabulations seem to arise from a diverse variety of etiologies. They can be seen in degenerative diseases such as Alzheimer's dementia (La Corte, Serra, Attali, Boissé, & Dalla Barba, 2010), in atrophy linked to malnutrition in, for example, Wernicke-Korsakoff's syndrome (Borzutsky, Fujiwara, Brand, & Markowitsch, 2008; Dalla Barba, Cipolotti, & Denes, 1990), and in infections such as syphilis and herpes simplex encephalitis (Gilboa & Moscovitch, 2002). Additionally, confabulations can also be caused by traumatic brain injury or by more focal lesions such as tumors and stroke. In particular, stroke due to a ruptured aneurism in the anterior communicating artery seems to cause patients to confabulate (Gilboa & Moscovitch, 2002; Schnider, von Daniken, & Gutbrod, 1996).

The rarity of the phenomenon in general, and the fact that it often naturally subsides in more chronic stages (Gilboa & Moscovitch, 2002), may explain the limited number of studies on the topic. To our knowledge, there are only two multi-case-studies of the time course of confabulation (Dalla Barba, Brazzarola, Marangoni, Barbera, & Zannoni, 2017; Schnider, Ptak, von Däniken, & Remonda, 2000) and none that stretches for more than approximately a year. Only few single-case studies report confabulations more than 1-year post-injury.

METHOD AND RESULTS

In our literature search, we found 286 articles reporting on different empirical studies of confabulation caused by brain injury. Only three of these describe cases of children or adolescents, revealing a clear discrepancy in the number of articles concerning adults as compared to children under 18 years of age (Figure 1).

The three studies we have been able to find are all single-case reports and are briefly summarized here (Figure 2).

1. Case report by Meguro et al. (1999): A girl aged 9 suffered a traumatic brain injury in 1995. She was assessed by Meguro and colleagues approximately 1–2 years later. Here, she suffered from anterograde amnesia, as well as a retrograde amnesia for 1 year before the accident. Her confabulations occurred if provoked by questions concerning events in episodic memory and were characterized by misplacement of memories in their temporal context together with an erroneous combination of existing memories. During a further follow-up examination, approximately 10 years later, the patient was still amnesic. However, her confabulations had vanished (Y. Meguro, personal communication, 2017). MRI scan of her brain at the time of the accident revealed bilateral hyperintensities in hippocampal areas and parts of splenium. During her follow-up examination 10 years later a new MRI scan was made, which did not show any

overt signs of lesioning, and the original authors speculate that her problems reside in diffuse axonal injury (Y. Meguro, personal communication, 2017).

2. Case report by Thomas-Antérion, Truche, Sciersere, and Extier (2012): A young girl aged 12 suffered a traumatic brain injury in 2001. An MR scan of her brain revealed diffuse damage, with bifrontal contusion and a thin corpus callosum, left frontal porencephaly, and ventricular dilatation. She expressed both an anterograde amnesia and an executive dysfunctioning. In 2009, she was examined at a rehabilitation center, where it was described that she was marked with spontaneous confabulation. The confabulations were characterized as plausible, and often they became evident only when verification failed.
3. Case report by Cohen et al. (2011): A 17-year-old girl suffered cardiac arrest due to overdose of benzonatate as part of a suicide attempt. After resuscitation an MR scan of her brain revealed diffuse infarcts in both the basal ganglia and the occipital lobes, and showed signs of white matter hypoxia in the frontal lobes compatible with anoxic injuries. Twenty days following her cardiac arrest, she still had no purposeful extra-ocular movement, tracking, response to confrontation, or ability to close her eyes. In addition to suffering blindness caused by injury to the occipital areas, the patient generated generalized confabulations. Nevertheless, the type of confabulation is not further specified, and it is uncertain whether the confabulations may be exclusively visual confabulations, as a response to cortical blindness found in Anton's syndrome (e.g., Maddula, Lutton, & Keegan, 2009). There is no report of any form of amnesia.

The case reported by Cohen et al. (2011) may be a borderline case since there is no report of amnesia or specification of the type of confabulation. Furthermore, cortical blindness might point to other syndromes caused by brain injury such as Anton's syndrome. Moreover, the suicide attempt could reflect a pre-existing psychiatric disease. Within the psychiatric literature the term "confabulation" is sometimes used to describe statements based on delusions, which may or may not be the case here. Finally, the patient could arguably be classified as a young adult (age 17) rather than a child, in developmental terms. Despite these uncertainties, we have included the report as the brain is still developing at this age (especially the frontal lobes, which have been related to confabulation, as described in the introduction). Moreover, based on the case-description provided in the report, we cannot with full certainty conclude that the patient in fact does not suffer from confabulation due to her brain injury.

Even though there are several suggestive similarities among the three patients it is difficult to generalize. However, to summarize, all are female, two cases have injuries to the frontal lobes, two have amnesia, and two have brain injury due to traumatic causes. However, whether these three cases are representative for the occurrence of confabulation in

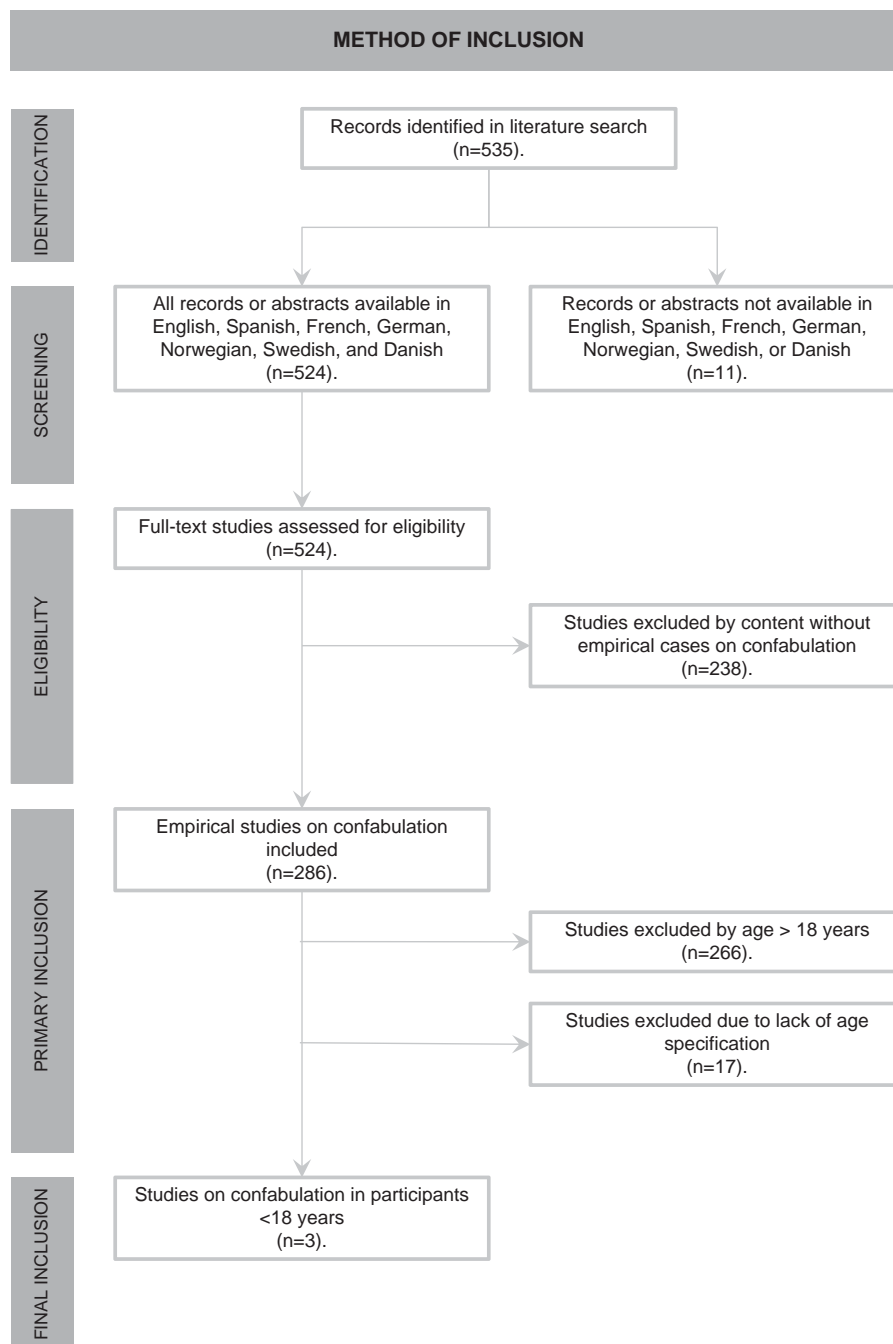


Fig. 1. Flowchart on the process of isolating cases of confabulation in children and adolescents (PubMed database search using the keyword: confabulat*, March 26, 2018).

children in general is difficult to say with any certainty. Nevertheless, they do demonstrate the scarcity of the phenomenon in the literature.

DISCUSSION

As several etiologies leading patients to confabulate do not occur in children, or at least have lower incidence rates (e.g., Alzheimer's disease and Wernicke-Korsakoff's syndrome caused by alcohol abuse and stroke), a discrepancy in the

reports is to be expected. However, several etiologies do, in fact, occur in children (e.g., tumors, stroke, encephalitis, and Wernicke-Korsakoff's syndrome due malnutrition in anorexia nervosa). Regarding tumors, confabulations are most often reported in relations to craniopharyngiomas (Schneider, 2008), which are most common in children in the age of 5 to 14 years (Garré & Cama, 2007). Considering the number of possible etiologies that do occur in children, it is striking that confabulations in children are so rarely seen in the clinic and in the reported literature. Based on the number of etiologies that may affect children, it does not seem sufficient to assume that age-

Case	Gender	Age at injury	Type of injury	Lesions	Imaging at time of injury	Symptoms
Meguro et al. (1999)	Female	9	Traumatic	Bilateral hyperintensities in hippocampal areas and parts of splenium	MRI	Symptoms 1-2 years post injury: Anterograde and retrograde amnesia for one year prior to the accident. Confabulations occurred if provoked by questions to events in episodic memory and were characterised by misplacement of memories in their temporal context together with an erroneous combination of existing memories. During a follow-up examination approximately 10 years later, the patient was still amnesic, however, her confabulations had vanished.
Thomas-Ant�erion et al. (2012)	Female	12	Traumatic	Diffuse damage, with bifrontal contusion and thin corpus callosum, left frontal porencephaly and ventricular dilatation	MRI	Anterograde amnesia, including executive dysfunction. Symptoms 8 years post injury: Spontaneous confabulation. The confabulations were characterised as plausible, and often they became evident only when verification failed.
Cohen et al. (2011)	Female	17	Anoxia due to cardiac arrest	Diffuse infarcts in both basal ganglia, the occipital lobes, including signs of white matter hypoxia in the frontal lobes compatible with anoxic injuries	MRI	Symptoms 20 days post injury: No purposeful extra-ocular movement, tracking, response to confrontation, or ability to close her eyes. In addition to blindness caused by injury to the occipital areas the patient generated generalized confabulations (not further described).

Fig. 2. Table describing the three identified cases of confabulation in children.

related problems such as Alzheimer's disease, and Wernicke-Korsakoff's syndrome due to alcohol abuse, can fully account for the scarcity of reports on confabulation in children.

Naturally, this discrepancy may be the result of a clinical bias where testing for confabulation in children is not included in the standard assessment and, therefore, is rarely reported. Nevertheless, considering the striking behavior of adult patients who confabulate, one would imagine that clinicians would have reported the behavior in children as well, had it been observed.

Possibly, clinicians might claim that there may not be a bias at all, because children naturally confabulate all the time. However, we believe that this would be a misconception. First of all, healthy children's fabricated stories are not caused by, or related to, limited memory access, as is the case with confabulations caused by brain injury. Second, the memory of children (as well as adults) is suggestible, but studies reveal that in none-suggestible environments children are not prone to faulty or distorted memory (Bruck & Ceci, 2012). Third, a recent study has shown that even children at the age of seven have efficacious mechanisms of reality filtering and thus are capable of keeping thoughts and behavior in phase with reality (Liverani et al., 2017), a breakdown in this mechanism has been linked to confabulation in several studies (Schnider, Nahum, & Ptak, 2017).

We believe that the discrepancy between the number of reported cases regarding confabulation in children and adults represents qualitative differences between the child's and the adult's brain affected by brain injury where the young brain is less susceptible to confabulations. Further research on this topic, including a clinical focus on reporting cases of confabulation in children, may lead to a better understanding of the governing mechanisms in confabulations caused by brain injury as well as the developing brain, for example, what are the aspects of the developing brain that seemingly protect children from developing confabulations?

Since we have not been able to find any research on this specific topic, we propose three tentative hypotheses on why children may be resilient to this particular condition. These could serve as different research avenues leading, not only to a better understanding of the nature of confabulations, but also to which mechanisms in the developing brain might provide resilience against confabulatory behavior.

The first hypothesis relates directly to the well-established differences in the degree of plasticity in the human brain in the course of a lifespan, particularly the high plasticity throughout childhood and early adolescence may shed light on why we do not see confabulation in children. Here one may speculate whether a remission of an already transient phenomenon (i.e., confabulations) occurs even faster in the developing brain, compared to the adult, or even aging, brain. The three studies included here do not clearly support this hypothesis, as confabulations are evident years post injury in both case one and two, nevertheless, due to the very low number of reported cases we cannot discount the possibility that these cases are especially severe since they have made their way into scientific literature.

One reason why more cases have not been reported could, in fact, be due to fast remission after injury in children and young adults. This speculation could gain some support based on other symptoms of brain injury where the developing brain recovers more rapidly than the adult brain. One such example is that young children who suffer even severe damage in language areas of the left hemisphere have shown a remarkable plasticity and rapid recovery, where areas of the right hemisphere may even take over language function following an injury (Ellison & Semrud-Clikeman, 2007; Kolb & Fantie, 2009). Thus, a high degree of neural plasticity could serve as a protecting factor from developing confabulation.

Second, damage to specific parts of the prefrontal cortex has previously been associated with confabulation (Gilboa & Moscovitch, 2002; Schneider, 2003), and particularly the prefrontal cortex is known to be still maturing during

adolescence and even into early adulthood (Lenroot & Giedd, 2006). Perhaps the late development of the prefrontal cortex might be acting as an additional protective factor against confabulation arising during childhood.

Finally, a third hypothesis relates to the content of confabulations, as the majority of confabulations consist of some form of generic memories or scripts, for example, the patient's habits or repeated personal events (Dalla Barba et al., 2017). Due to cumulative experience, adults naturally have more elaborated and well-established episodic scripts than do children. These well-established episodic scripts, or memories, might be better preserved or more readily accessible for adults following some degree of amnesia caused by brain injury, which in turn may give rise to confabulations. Despite the intuitive appeal of this account, it fails to explain the rarer fantastic confabulations, where the content of the confabulations is unrealistic or has supernatural content. There is still an ongoing debate whether plausible and fantastic confabulation are distinct forms of confabulation (Nahum, 2012) or opposite extremes of a continuum (Dalla Barba, 1993b).

For the present, these remain tentative speculations. However, with additional awareness of the age-related discrepancy in the prevalence of confabulation in children and adults, we hope to gain a better understanding not only of confabulations themselves, but also of the resilience and plasticity of the developing brain, which seem to serve as a protective factor during childhood and adolescence against symptoms of brain injury such as confabulation.

A way forward would be to establish a consortium investigating confabulations across age spans with specific attention to children. The investigation should include a clinical screening for confabulation using a standardized test battery (e.g., a short version of The Confabulation Battery originally developed by Dalla Barba and colleagues, 2018). This would enable mapping of age-related differences, etiologies, and lesion types and how they interact.

ACKNOWLEDGMENTS

We thank Dr. Yuko Meguro for helping us to access her original report and for discussing the case with us in more detail, and Dr. Tom Teasdale for his superlative proofreading of our manuscript. Neither of the authors has any potential conflicts of interest to report and neither has received financial support for this work.

REFERENCES

- American Psychiatric Association. (1994). *DSM-IV. Diagnostic and statistical manual of mental disorders*, (4th ed.). Washington, DC: American Psychiatric Association.
- Borzutzky, S., Fujiwara, E., Brand, M., & Markowitsch, H. (2008). Confabulations in Alcoholic Korsakoff patients. *Neuropsychologia*, *46*, 3133–3143.
- Bowman, K. M., & Blau, A. (1940). Psychotic states following head and brain injury in adults and children. In S. Brock (Ed.), *Injuries of the skull, brain and spinal cord: Neuro-psychiatric surgical and medico-legal aspects* (pp. 309–360). London: Ballière Tindal, & Cox.

- Bruck, M., & Ceci, S. J. (2012). Forensic developmental psychology in the courtroom. In D. Faust (Ed.), *Coping with psychiatric and psychological testimony*. (6th ed., pp. 723–736). Oxford University Press.
- Cohen, V., Jellinek, S. P., Stansfield, L., Truong, H., Baseluos, C., & Marshall, J. P. (2011). Cardiac arrest with residual blindness after overdose of Tessalon® (Benzonatate Perles). *The Journal of Emergency Medicine*, *41*(2), 166–171.
- Dalla Barba, G. (1993a). Different patterns of confabulation. *Cortex*, *29*(4), 567–581.
- Dalla Barba, G. (1993b). Confabulation: Knowledge and recollective experience. *Cognitive Neuropsychology*, *10*(1), 1–20.
- Dalla Barba, G., Cipolotti, L., & Denes, G. (1990). Autobiographical memory loss and confabulation in Korsakoff's syndrome: A case report. *Cortex*, *26*, 525–534.
- Dalla Barba, G., Brazzarola, M., Marangoni, S., Barbera, C., & Zannoni, I. (2017). A longitudinal study of confabulation. *Cortex*, *87*, 44–51.
- Dalla Barba, G., Guerin, B., Brazzarola, M., Marangoni, S., Barbera, C., & La Corte, V. (2018). The confabulation battery: Instructions and international data from normal participants. *Neuropsychological Rehabilitation*, *21*, 1–12.
- Ellison, P. A., & Semrud-Clikeman, M. (2007). *Child neuropsychology. Assessment and intervention for neurodevelopmental disorders*. New York: Springer.
- Garré, M. L., & Cama, A. (2007). Craniopharyngeoma: Modern concepts in pathogenesis and treatment. *Current Opinions in Pediatrics*, *19*(4), 471–479.
- Gilboa, A. (2010). Strategic retrieval, confabulations and delusions: Theory and data. *Cognitive Neuropsychiatry*, *15*(1), 145–180.
- Gilboa, A., & Moscovitch, M. (2002). The cognitive neuroscience and confabulation: A review and a model. In A. D. Baddeley, M. D. Kopelman, & B. Wilson (Eds.), *The handbook of memory disorders* (2nd ed., pp. 315–342). New York: John Wiley & Sons Ltd.
- Kolb, B., & Fantie, B. D. (2009). Development of the child's brain and behavior. In C. R. Reynolds & E. Fletcher-Janzen (Eds.), *Handbook of Clinical Child Neuropsychology* (3rd ed., pp. 19–46). New York: Springer.
- La Corte, V., Serra, M., Attali, E., Boissé, M. F., & Dalla Barba, G. (2010). Confabulation in Alzheimer's disease and amnesia: A qualitative account and a new taxonomy. *Journal of the International Neuropsychological Society*, *16*(6), 967–974.
- Lenroot, R. K., & Giedd, J. N. (2006). Brain development in children and adolescents: Insights from anatomical magnetic resonance imaging. *Neuroscience and Biobehavioral Reviews*, *30* (6), 718–729.
- Liverani, M. C., Manuel, A. L., Nahum, L., Guardabassi, V., Tomasetto, C., & Schnider, A. (2017). Children's sense of reality: The development of orbitofrontal reality filtering. *Child Neuropsychology*, *23*(4), 408–421.
- Maddala, M., Lutton, S., & Keegan, B. (2009). Anton's syndrome due to cerebrovascular disease: A case report. *Journal of Medical Case Reports*, *3*(1), 9028.
- Meguro, Y., Suzuki, K., Tsukjura, T., Fujii, T., Yamadori, A., & Kudoh, M. (1999). Episodic and semantic memory after brain injury in a child. *No To Shinkei*, *51*(11), 985–990.
- Nahum, L., Bouzerda-Wahlen, A., Guggisberg, A., Ptak, R., & Schnider, A. (2012). Forms of confabulation: Dissociations and associations. *Neuropsychologia*, *65*, 2524–2534.
- Schnider, A. (2003). Spontaneous confabulation and the adaption of thought to ongoing reality. *Nature Reviews Neuroscience*, *4*, 662–671.

- Schnider, A. (2008). *The confabulation mind – How the brain creates reality*. Oxford, UK: Oxford University Press.
- Schnider, A., Nahum, L., & Ptak, R. (2017). What does extinction have to do with confabulation? *Cortex*, 87, 5–15.
- Schnider, A., Ptak, R., von Däniken, C., & Remonda, L. (2000). Recovery from spontaneous confabulations parallels recovery of temporal confusion in memory. *Neurology* 55(1), 74–83.
- Schnider, A., von Daniken, C., & Gutbrod, K. (1996). The mechanisms of spontaneous and provoked confabulations. *Brain*, 119(4), 1365–1375.
- Thomas-Antérion, C., Truche, A., Sciessere, K., & Extier, C. (2012). Spontaneous confabulations and behavioral and cognitive dysexecutive syndrome. *Annals of Physical and Rehabilitation Medicine*. 55(1), 44–52.