



AALBORG UNIVERSITY
DENMARK

Aalborg Universitet

Radiographic signs of acetabular retroversion using a low-dose slot-scanning radiographic system (EOS[®])

Mussmann, B.; Jensen, C.; Bensen, A. S.; Torfing, T.; Ovesen, O.; Overgaard, S.

Published in:
Radiography

DOI (link to publication from Publisher):
[10.1016/j.radi.2019.01.001](https://doi.org/10.1016/j.radi.2019.01.001)

Creative Commons License
CC BY-NC-ND 4.0

Publication date:
2019

Document Version
Accepted author manuscript, peer reviewed version

[Link to publication from Aalborg University](#)

Citation for published version (APA):

Mussmann, B., Jensen, C., Bensen, A. S., Torfing, T., Ovesen, O., & Overgaard, S. (2019). Radiographic signs of acetabular retroversion using a low-dose slot-scanning radiographic system (EOS[®]). *Radiography*, 25(3), E53-E57. <https://doi.org/10.1016/j.radi.2019.01.001>

General rights

Copyright and moral rights for the publications made accessible in the public portal are retained by the authors and/or other copyright owners and it is a condition of accessing publications that users recognise and abide by the legal requirements associated with these rights.

- Users may download and print one copy of any publication from the public portal for the purpose of private study or research.
- You may not further distribute the material or use it for any profit-making activity or commercial gain
- You may freely distribute the URL identifying the publication in the public portal -

Take down policy

If you believe that this document breaches copyright please contact us at vbn@aub.aau.dk providing details, and we will remove access to the work immediately and investigate your claim.

Radiographic signs of acetabular retroversion using a low-dose slot-scanning radiographic system (EOS[®]).

Introduction

Assessment of acetabular retroversion is currently based on conventional anteroposterior (AP) X-ray of the pelvis using the cross-over sign (COS)¹, the posterior-wall-sign (PWS)² and the ischial-spine-sign (ISS)³ as the gold standard for evaluation and comparison. Retroversion of the acetabulum has been proposed to contribute to femoro-acetabular pincer impingement (FAI) and development of osteoarthritis⁴⁻⁷ and thus, radiographic imaging is important in the clinical assessment. FAI is a clinical diagnose where retroversion of the acetabulum may be a cause. Retroversion is a complex 3-dimensional expression where the opening of the superior part of acetabulum is oriented posteriorly instead of anteriorly. Thus, COS describes the expression and PWS and ISS are signs of rotation of the whole acetabular complex. Since symptoms of FAI often start at young age with groin pain during activity young individuals risk exposure to repeated radiation, as they are referred for repeated X-rays for diagnosis, monitoring, surgical planning and postoperative follow-up. The pelvic region is relatively sensitive to radiation, particularly in children and adolescents and thus, radiation exposure should be as low as reasonably achievable. Previous experimental and clinical research in other anatomical areas has proven the dose reduction potential of the low-dose radiographic system (EOS) as compared to conventional digital radiography systems⁸⁻¹³. The main difference between conventional radiography and EOS is the nature of image acquisition; EOS being a full-body slot-scanner with the option to acquire orthogonal views simultaneously using very low radiation dose associated with the proportional multi-wire chamber detector¹⁴. Few studies have compared EOS-images of the pelvis with

conventional X-rays¹⁵⁻¹⁷ and to our knowledge no studies have made this comparison in a population of patients with retroversion of the acetabulum. The primary aim of this study was to compare radiographic parameters for retroversion of the acetabulum based on conventional X-rays of the pelvis and EOS and secondarily, to compare the absorbed equivalent radiation doses between the two modalities.

Methods

Orthopedic outpatients diagnosed with acetabular retroversion by one of three senior orthopedic surgeons specialized in hip surgery were consecutively recruited from the clinic. Acetabular retroversion was defined as presence of COS on conventional AP X-ray of the pelvis. Individuals who met all the inclusion and none of the exclusion criteria were offered participation in the study (Table 1).

X-rays

Conventional AP X-ray of the pelvis was performed with the participants in standing position with the arms crossed in front of the chest and the legs slightly abducted so the feet could meet in 15 degrees of inward rotation. The X-ray beam was perpendicular to the detector and focused 2-3 cm above the pubic symphysis with a focus-detector distance of 115 cm. The beam collimation included the iliac rim, the pubic bone and the greater trochanter bilaterally. The images were acquired using 70-87 kVp and automatic exposure control.

EOS-images

AP EOS-images of the pelvis were performed in the same position as described for conventional X-rays. The focus detector distance was 130 cm (cannot be altered in EOS) and the irradiated area was

identical to that of pelvic X-ray. Scans were acquired using 104-125 kVp and 320-400 mA depending on patient size.

Outcome measures

X-rays and EOS-images of the pelvis were assessed for COS, PWS and ISS radiographic signs of retroversion (Fig. 1) and ratios for COS and PWS were calculated (Fig. 2). Dose-Area-Product (DAP) for AP conventional X-rays and EOS-images was collected after each image was acquired. An orthopedic surgeon in training (A) conducted all measurements after special training by an experienced musculoskeletal radiologist (B) using GE Centricity PACS 4.0 (GE Healthcare, Barrington, IL, US).

Statistical Analysis

All continuous data were normally distributed as tested by visual evaluation of Q-Q-plots and by the Shapiro-Wilks normality test. Results are reported as mean, standard deviation, range and/or percentage. Differences between radiation doses were analyzed using Student's t-test. The level of significance was set at $p < 0.05$ for all statistical analyses. Comparison between COS-ratio and PWS-ratio in X-rays and EOS-images was performed using Bland-Altman plots including limits of agreement. All analyses were performed using STATA/SE 14.0 (StataCorp. LP, College Station, TX, USA).

Ethics

The study was performed in accordance with the ethical standards in the 1964 Declaration of Helsinki and was approved by the local Ethical Committee (S-20140033) and The Danish Data Protection Agency before initiation of the study. The EOS examination was not part of the regular

imaging regime and thus, radiation risk estimates were calculated by the regional physicist using PCXMC 2.0 dose assessment software (STUK, Helsinki, FI). For the patient group included in the study the estimated risk of exposure induced cancer death ranged from 0.0008 to 0.0006% translating into an estimated loss of life expectancy of 0.9 to 1.9 hours. The risks associated with the study were considered acceptable by the local Ethical Committee as well as by the participants.

Results

In total 101 individuals were assessed for eligibility (Fig. 3). Forty-four of those did not meet all the inclusion criteria and 23 were excluded, resulting in 34 participants and 68 hips available for analysis. The majority of the participants were females (74%) with an average age of 24 years and four had previous PAO on the contralateral hip (Table 2).

Retroversion of the acetabulum

The absolute agreement between the two modalities regarding COS, PWS and ISS were 91% (62 hips), 84% (57 hips) and 76% (52 hips) respectively (Table 3). No statistically significant differences between COS-ratios and PWS-ratios for X-ray and EOS were found (Table 4). Bland-Altman Limits of Agreement were narrow, i.e. -16 to 14% for COS-ratio and -18 to 15% for PWS-ratio (Fig. 4).

Radiation dose

The X-ray mean DAP was 1,053 mGy*cm² (range 186 to 3,814) and 593 mGy*cm² (range 452 to 821) on EOS (p=0.003), and the mean radiation dose for AP-projections was reduced by 44% when using EOS.

Discussion

To our knowledge, this study is the first prospective cohort study investigating whether EOS and X-ray are comparable in the assessment of retroversion of the acetabulum. The results suggest that EOS may be used as a diagnostic tool to identify radiological signs of acetabular retroversion with the benefit of a significant reduction in radiation dose.

X-ray vs. EOS

Despite uncertainty about the reliability of using X-ray for retroversion assessment raised by Wassilew et al.¹⁸ it is still widely accepted that the radiological diagnosis of acetabular retroversion on AP projections of the pelvis is based on the presence of COS¹, PWS² and ISS³ with COS being the cardinal sign of retroversion. Furthermore, the COS-ratio and PWS-ratio describe the severity of retroversion. Identification of primarily COS and PWS are of great clinical importance to the hip surgeon when treatment is decided.

The EOS-images showed high levels of agreement for the presence of retroversion parameters and no significant differences between their ratios compared to X-ray suggesting that EOS may be used to identify radiological signs of retroversion of the acetabulum. Other studies that compared acetabular parameters on conventional X-rays of the pelvis with EOS¹⁵⁻¹⁷ all reported strong or excellent correlations between the two modalities regarding different acetabular parameters, pelvic morphology at different degrees of pelvic tilt, rotation and body position. Bittersohl et al.¹⁶ and Monazzam et al.¹⁷, who measured the effects of different degrees of pelvic tilt and rotation on parameters describing acetabular and pelvic morphology on cadaveric pelvis, reported Pearson's correlation coefficients ranging from 0.64 to 0.99 and intermodality intraclass correlation coefficients ranging from 0.93 to 0.98 between the two modalities, respectively. Lazennec et al.¹⁵, who measured pelvic tilt and acetabular cup orientation in 50 patients with total hip replacement in

standing and sitting positions found Spearman Rank correlation coefficients ranging from 0.82 to 0.98.

Radiation dose

The study demonstrated that using EOS significantly reduces the radiation dose (44%) compared with conventional X-ray. A study by Chiron et al reported similar dose reduction using EOS versus pelvic x-ray¹³. Other studies also reported significant reductions in radiation dose using EOS, but most of them reported entrance skin dose reductions in other anatomical regions and in children¹⁹⁻²¹. Therefore, they are not directly comparable to our study. Other dose reduction strategies in DR may narrow the radiation dose gap between DR and EOS, i.e. increasing focus-detector distance or using grid-less technology with iterative anti-scatter correction. However, the effect of those strategies on radiographic signs of acetabular retroversion has not yet been examined and may be subject to further studies.

Strengths and limitations

The study is strengthened by the prospective design with participants consecutively recruited to avoid selection bias. Furthermore, all participants went through a standardized setup, i.e. examined and included by one of three senior orthopedic surgeons specialized in hip surgery in patients with acetabular retroversion.

The study also has limitations. The sample size is relatively small and for practical reasons X-ray and EOS examinations were performed on two separate days and by two different radiographers. Strictly standardized protocols were used for both X-ray and EOS, but minor variations in the positioning of the participants may have occurred. However, such variation could occur even if the X-ray and EOS examinations were performed consecutively because the images would be acquired in separate rooms. Finally, the study was not designed to assess technical or subjective image

quality parameters except for the inherent fact that acceptable diagnostic image quality is imperative for visualization of the acetabular parameters measured. Therefore, the study cannot address if EOS could potentially replace conventional pelvic radiography in general.

In conclusion, high levels of agreement between conventional X-ray and EOS were found for all parameters. Our study indicates that AP EOS projections of the pelvis provide diagnostic qualities similar to conventional X-ray in a population of patients with retroversion of the acetabulum and reduce radiation by 44 %. Therefore, we suggest that EOS may be used for assessment of acetabular retroversion, but further studies are needed to assess sensitivity and specificity of EOS in diagnosing acetabular retroversion.

References

1. Jamali AA, Mladenov K, Meyer DC, et al. Anteroposterior pelvic radiographs to assess acetabular retroversion: high validity of the "cross-over-sign". *J Orthop Res* 2007;25:758-765.
2. Reynolds D, Lucas J, Klaue K. Retroversion of the acetabulum. A cause of hip pain. *J Bone Joint Surg Br* 1999;81:281-288.
3. Kalberer F, Sierra RJ, Madan SS, et al. Ischial spine projection into the pelvis : a new sign for acetabular retroversion. *Clin Orthop Relat Res* 2008;466:677-683.
4. Kim WY, Hutchinson CE, Andrew JG, et al. The relationship between acetabular retroversion and osteoarthritis of the hip. *J Bone Joint Surg Br* 2006;88:727-729.
5. Tannast M, Siebenrock KA, Anderson SE. Femoroacetabular impingement: radiographic diagnosis--what the radiologist should know. *Radiologia (Roma)* 2008;50:271-284.

6. Tonnis D, Heinecke A. Acetabular and femoral anteversion: relationship with osteoarthritis of the hip. *J Bone Joint Surg Am* 1999;81:1747-1770.
7. Troelsen A, Soballe K. Idiopathic osteoarthritis of the hip. *Ugeskr Laeger* 2007;169:390.
8. C (reference blinded – contains author identifying information)
9. Clavel AH, Monnin P, Létang JM, et al. Characterising the EOS Slot-Scanning system with the effective detective quantum efficiency. *Radiat Prot Dosimetry* 2016;169:319-324.
10. Escott BG, Ravi B, Weathermon AC, et al. EOS low-dose radiography: a reliable and accurate upright assessment of lower-limb lengths. *J Bone Joint Surg Am* 2013;95:e1831-1837.
11. Morel B, Moueddeb S, Blondiaux E, et al. Dose, image quality and spine modeling assessment of biplanar EOS micro-dose radiographs for the follow-up of in-brace adolescent idiopathic scoliosis patients. *Eur Spine J* 2018;27:1082-1088.
12. Yvert M, Diallo A, Bessou P, et al. Radiography of scoliosis: Comparative dose levels and image quality between a dynamic flat-panel detector and a slot-scanning device (EOS system). *Diagn Interv Imaging* 2015;96:1177-1188.
13. Chiron P, Demoulin L, Wytrykowski K, et al. Radiation dose and magnification in pelvic X-ray: EOS imaging system versus plain radiographs. *Orthop Traumatol Surg Res* 2017;103:1155-1159.
14. Illes T, Somoskeoy S. The EOS imaging system and its uses in daily orthopaedic practice. *Int Orthop*. 2012; 36:1325-1331.
15. Lazennec JY, Rousseau MA, Rangel A, et al. Pelvis and total hip arthroplasty acetabular component orientations in sitting and standing positions: measurements reproducibility with EOS imaging system versus conventional radiographies. *Orthop Traumatol Surg Res* 2011;97:373-380.

16. Bittersohl B, Freitas J, Zaps D, et al. EOS imaging of the human pelvis: reliability, validity, and controlled comparison with radiography. *J Bone Joint Surg Am* 2013;95:e581-589.
17. Monazzam S, Agashe M, Hosalkar HS. Reliability of overcoverage parameters with varying morphologic pincer features: comparison of EOS(R) and radiography. *Clin Orthop Relat Res* 2013;471:2578-2585.
18. Wassilew GI, Heller MO, Diederichs G, et al. Standardized AP radiographs do not provide reliable diagnostic measures for the assessment of acetabular retroversion. *J Orthop Res* 2012;30:1369-1376.
19. Deschenes S, Charron G, Beaudoin G, et al. Diagnostic imaging of spinal deformities: reducing patients radiation dose with a new slot-scanning X-ray imager. *Spine (Phila Pa 1976)* 2010;35:989-994.
20. Dietrich TJ, Pfirrmann CW, Schwab A, et al. Comparison of radiation dose, workflow, patient comfort and financial break-even of standard digital radiography and a novel biplanar low-dose X-ray system for upright full-length lower limb and whole spine radiography. *Skeletal Radiol* 2013;42:959-967.
21. Kalifa G, Charpak Y, Maccia C, et al. Evaluation of a new low-dose digital x-ray device: first dosimetric and clinical results in children. *Pediatr Radiol* 1998;28:557-561.

Tables

Table 1: Criteria for the participants in the study. COS = Cross-over-sign; AP = Antero-Posterior; PAO = Periacetabular osteotomy; FOI = Foramen obturator index

Inclusion criteria	Exclusion criteria
Age 18-50 years	Previous surgical arthrodesis of the lumbar spine
One or more radiographic signs of retroversion of the acetabulum (COS must be present) on conventional AP X-ray of the pelvis in standing position	Excessive rotation of the pelvis on standing AP X-ray (FOI < 0.8 or > 1.2)
Previous fracture and/or surgery (except PAO on the contralateral site) on the proximal femur or pelvis	Other conditions that prevent patients from carrying out the examination
Secondary hip dysplasia related to previous Legg-Calvé Perthes disease	Decline to participate
	Inability to speak or read Danish
	Inability to participate for other reasons

Table 2: Baseline characteristics for participants in the study

Characteristic	n=34
Female, n (%)	25 (74)
Previous PAO on the contralateral hip (%)	4 (12)
Age (year), mean (range)	24 (18-43)
Weight (kg), mean (range)	71 (55-96)
Height (cm) , mean (range)	174 (157-190)

PAO = Periacetabular osteotomy

Table 3: Diagnostic accuracy of cross-over-sign (COS), posterior-wall-sign (PWS) and ischial-spine-sign (ISS) using EOS and pelvic X-ray (reference)

Characteristic	COS	PWS	ISS
Radiographic sign present on X-Ray and EOS, n	57	36	36
Radiographic sign not present in either modality	5	21	16
Radiographic sign present in EOS only	4	9	14
Radiographic sign present in X-ray only	2	2	2
Absolute agreement, n (%)	62 (91)	57 (84)	52 (76)

Table 4. Mean ratios for Crossover sign (COS) and Posterior Wall Sign (PWS) in X-ray and EOS.

	X-ray	EOS	p-value
	% (range)	% (range)	
COS-ratio n=57	24.3 (6 to 52)	23.7 (9 to 45)	0.53
PWS-ratio n=36	20.6 (7 to 56)	19.0 (6 to 46)	0.27

Figure 1. Radiographic signs of acetabular retroversion in AP projections with examples using a pelvic EOS image. Left: Cross-over sign; present when the anterior rim line of the [acetabulum](#) is lateral to the posterior rim line in the cranial part and medial in the distal part of the acetabulum. Middle: Posterior wall sign; present if the rim line of the posterior wall is projected medial to the center of the [femoral head](#). Right: Ischial spine sign; present if the ischial spine extends medial to the pelvic ring into the [pelvic cavity](#).

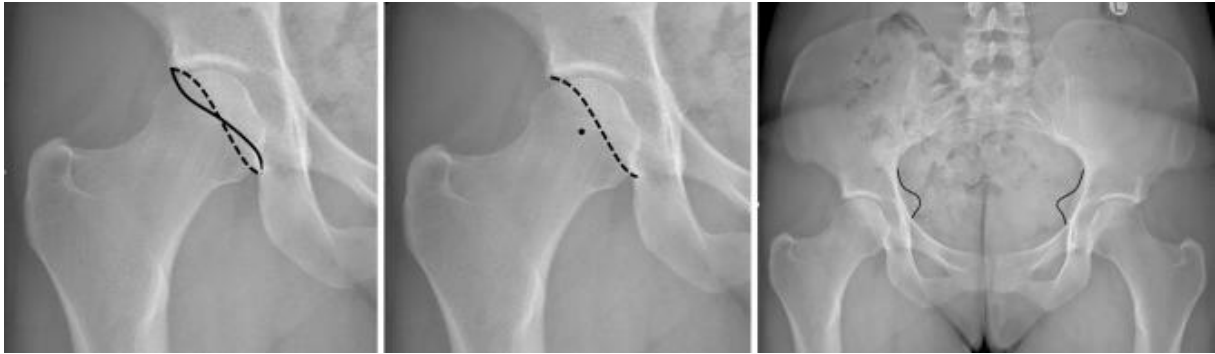


Figure 2. Left: Cross-over ratio; the ratio between; (a) the length of the lateral overlap of the anterior rim line of the retroverted [acetabulum](#) and (a + b) the full length of the lateral acetabular opening. Right: Posterior wall ratio; the ratio between the two horizontal lengths; (a) the center of the [femoral head](#) to the posterior wall, (b) the radius of the femoral head.

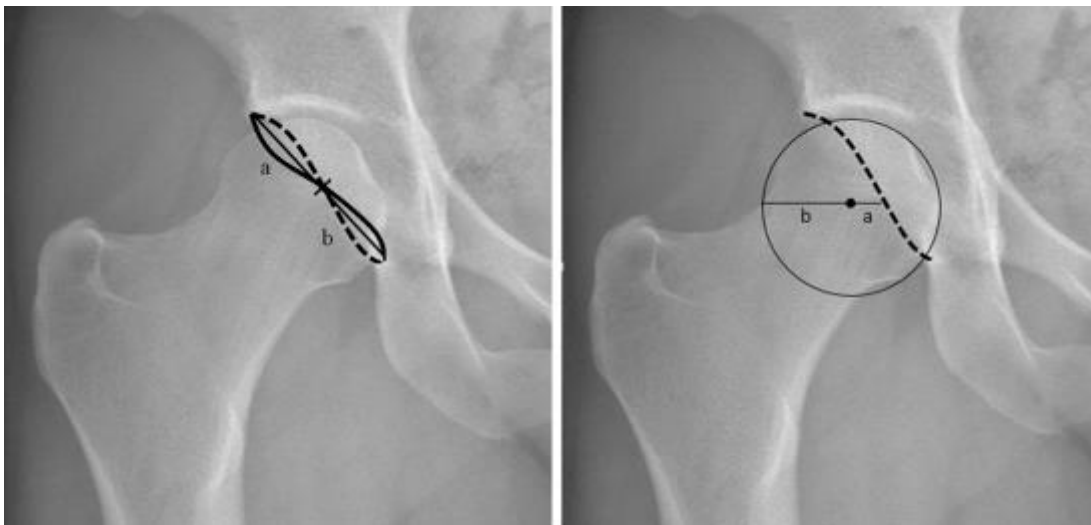


Figure 3. Flow-chart for the study.

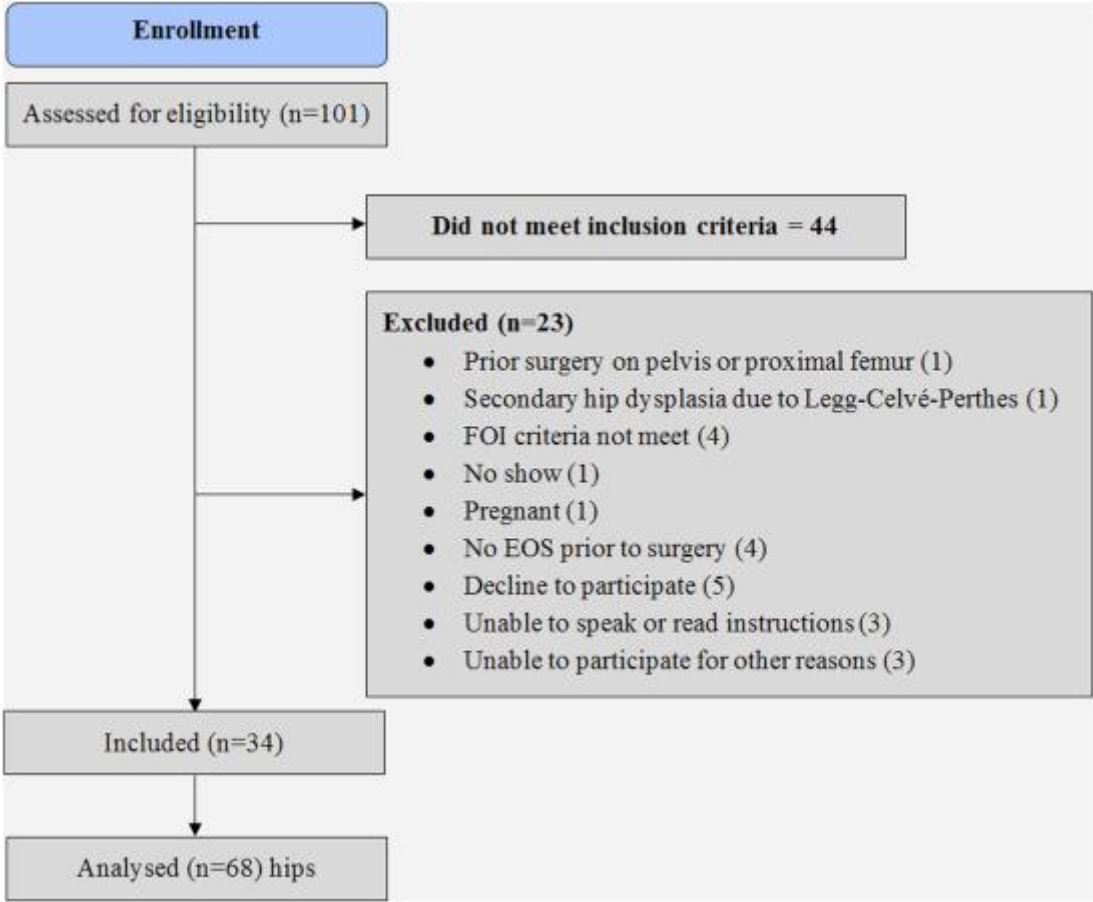


Figure 4. [Bland–Altman plots](#) comparing COS-ratio (left) and PWS-ratio (Right) measured using X-ray and EOS. Horizontal lines indicate limits of agreement and the mean difference between the measurements.

