

**Bone-to-implant contact after maxillary sinus floor augmentation with Bio-Oss and autogenous bone in different ratios in mini pigs**

Jensen, Thomas; Schou, Søren; Gundersen, Hans Jørgen Gottlieb; Forman, Julie Lyng; Terheyden, Hendrik; Holmstrup, Palle

*Published in:*  
Clinical Oral Implants Research

*DOI (link to publication from Publisher):*  
[10.1111/j.1600-0501.2012.02438.x](https://doi.org/10.1111/j.1600-0501.2012.02438.x)

*Publication date:*  
2013

*Document Version*  
Early version, also known as pre-print

[Link to publication from Aalborg University](#)

*Citation for published version (APA):*

Jensen, T., Schou, S., Gundersen, H. J. G., Forman, J. L., Terheyden, H., & Holmstrup, P. (2013). Bone-to-implant contact after maxillary sinus floor augmentation with Bio-Oss and autogenous bone in different ratios in mini pigs. *Clinical Oral Implants Research*, 24(6), 635-44. <https://doi.org/10.1111/j.1600-0501.2012.02438.x>

**General rights**

Copyright and moral rights for the publications made accessible in the public portal are retained by the authors and/or other copyright owners and it is a condition of accessing publications that users recognise and abide by the legal requirements associated with these rights.

- Users may download and print one copy of any publication from the public portal for the purpose of private study or research.
- You may not further distribute the material or use it for any profit-making activity or commercial gain
- You may freely distribute the URL identifying the publication in the public portal -

**Take down policy**

If you believe that this document breaches copyright please contact us at [vbn@aub.aau.dk](mailto:vbn@aub.aau.dk) providing details, and we will remove access to the work immediately and investigate your claim.



Thomas Jensen  
 Søren Schou  
 Hans Jørgen G. Gundersen  
 Julie Lyng Forman  
 Hendrik Terheyden  
 Palle Holmstrup

# Bone-to-implant contact after maxillary sinus floor augmentation with Bio-Oss and autogenous bone in different ratios in mini pigs

## Authors' affiliations:

Thomas Jensen, Department of Oral and Maxillofacial Surgery, Aalborg Hospital, Aarhus University Hospital, Aalborg, Denmark  
 Søren Schou, Department of Oral and Maxillofacial Surgery and Oral Pathology, School of Dentistry, Aarhus University, Aarhus, Denmark  
 Hans Jørgen G. Gundersen, Stereology and Electron Microscopy Research Laboratory, Aarhus Hospital, Aarhus University Hospital, Aarhus, Denmark  
 Julie Lyng Forman, Department of Biostatistics, University of Copenhagen, Copenhagen, Denmark  
 Hendrik Terheyden, Department of Oral and Maxillofacial Surgery, Red Cross Hospital Kassel, Kassel, Germany  
 Palle Holmstrup, Departments of Periodontology, Schools of Dentistry, Universities of Copenhagen and Aarhus, Copenhagen, Denmark

## Corresponding author:

Dr. Thomas Jensen  
 Department of Oral and Maxillofacial Surgery  
 Aalborg Hospital, Aarhus University Hospital  
 18-22 Hobrovej  
 DK-9000 Aalborg  
 Denmark  
 Tel.: +45 99 32 28 00  
 fax: +45 99 32 28 05  
 e-mail: thomas.jensen@rn.dk

**Key words:** alveolar ridge augmentation, bone substitutes, bone transplantation, dental implants, histology, maxillary sinus

## Abstract

**Objectives:** The objective was to test the hypotheses: (i) no differences in bone-to-implant contact formation, and (ii) no differences between the use of autogenous mandibular or iliac bone grafts, when autogenous bone, Bio-Oss mixed with autogenous bone, or Bio-Oss is used as graft for the maxillary sinus floor augmentation.

**Material and methods:** Bilateral sinus floor augmentation was performed in 40 mini pigs with: (A) 100% autogenous bone, (B) 75% autogenous bone and 25% Bio-Oss, (C) 50% autogenous bone and 50% Bio-Oss, (D) 25% autogenous bone and 75% Bio-Oss, or (E) 100% Bio-Oss. Autogenous bone was harvested from the iliac crest or the mandible and the graft composition was selected at random and placed concomitant with the implant placement. The animals were euthanized 12 weeks after surgery. Bone-to-implant contact was estimated by stereological methods and summarized as median percentage with 95% confidence interval (CI). Bone-to-implant contact formation was evaluated by fluorochrome labelling and assessed by median odds ratios (OR) with 95% (CI).

**Results:** Median bone-to-implant contact was: (A) 42.9% (95% CI: 32.1–54.5%), (B) 37.8% (95% CI: 27.1–49.9%), (C) 43.9% (95% CI: 32.6–55.9%), (D) 30.2% (95% CI: 21.6–40.3%), and (E) 13.9% (95% CI: 11.4–16.9%). Bone-to-implant contact was significantly higher for A, B, C, D as compared to E ( $P < 0.0001$ ). Bone-to-implant contact was not significantly influenced by the ratio of Bio-Oss and autogenous bone ( $P = 0.19$ ) or the origin of the autogenous bone ( $P = 0.72$ ). Fluorochrome labelling revealed extensive variation in bone-to-implant contact formation over time. The labelling at weeks 2–3 was significantly increased with A compared to E (OR = 8.1 CI: 5.0–13.1,  $P < 0.0001$ ), whereas E showed a significantly increased labelling at weeks 8–9 compared to A (OR = 0.5 CI: 0.3–0.7,  $P = 0.0028$ ).

**Conclusions:** The hypothesis of no differences in bone-to-implant contact between the various treatment modalities was rejected since the bone-to-implant contact was significantly increased with autogenous bone or Bio-Oss mixed with autogenous bone as compared to Bio-Oss. Early bone-to-implant contact formation was more advanced with autogenous bone. No differences between the use of mandibular or iliac bone grafts were observed since the bone-to-implant contact was not significantly influenced by the origin of the bone graft.

A bone substitute of bovine origin (Bio-Oss; Geistlich Pharma AG, Wolhusen, Switzerland) (BO) is frequently used alone or in combination with autogenous bone for maxillary sinus floor augmentation, and the treatment outcome has been reported in several reviews (Wallace & Froum 2003; del Fabbro et al. 2004; Browaeys et al. 2007; Pjetursson et al. 2008; Chiapasco et al. 2009; Jensen & Terheyden 2009; Nkenke & Stelzle 2009; Esposito et al. 2010; Jensen et al. 2012). The

volumetric changes of the graft after maxillary sinus floor augmentation with BO and autogenous bone from the iliac crest or the mandible in different ratios have recently been evaluated radiographically by computed tomographies in 40 mini pigs after 12 weeks (Jensen et al. 2011). Three-dimensional unbiased stereological estimates documented that the volumetric stability of the graft was significantly influenced by the ratio of BO and autogenous bone, but not by the origin of the

**Date:**  
 Accepted 29 January 2012

## To cite this article:

Jensen T, Schou S, Gundersen HJG, Forman JL, Terheyden H, Holmstrup P. Bone-to-implant contact after maxillary sinus floor augmentation with Bio-Oss and autogenous bone in different ratios in minipigs.  
*Clin. Oral Impl. Res.* 24, 2013, 635–644  
 doi: 10.1111/j.1600-0501.2012.02438.x

autogenous bone, i.e. mandibular bone and iliac bone. However, the bone-to-implant contact formation after maxillary sinus floor augmentation with different ratios of BO and autogenous bone has never been compared within the same study. Therefore, the objective of the present study was to test the hypotheses of: (i) no differences in bone-to-implant contact formation, and (ii) no differences between the use of mandibular or iliac bone grafts, when autogenous bone, BO mixed with autogenous bone, or BO is used as graft for the maxillary sinus floor augmentation in mini pigs.

## Material and methods

The material and experimental design have been described previously in detail (Jensen et al. 2011). A total of 40 adult female Göttingen minipigs (Ellegaard Göttingen Minipigs A/S, Dalmose, Denmark) were randomly divided into two groups of 20 animals. The treatment sequence of the animals was selected at random by drawing a number between one and 20. Maxillary sinus floor augmentation was performed bilaterally in conjunction with implant placement using autogenous bone harvested from either the iliac crest (Group 1) or the mandible (Group 2) and mixed with BO in different ratios at random. The allocation of graft and number of sinuses is outlined in Tables 1 and 2.

### Surgical procedure

Bone graft harvesting from iliac crest

A skin incision was made above the iliac crest and the tissues were dissected to expose the lateral surface of the posterior iliac crest. A cortico-cancellous bone graft involving the entire posterior iliac crest was harvested with

**Table 1. Allocation of graft and number of sinuses**

Autogenous bone from iliac crest (Group 1)		
Sinus no.	Iliac bone (%)	Bio-Oss (%)
(n = 8)	100	0
(n = 8)	75	25
(n = 8)	50	50
(n = 8)	25	75
(n = 8)	0	100
Autogenous bone from mandible (Group 2)		
Sinus no.	Mandibular bone (%)	Bio-Oss (%)
(n = 8)	100	0
(n = 8)	75	25
(n = 8)	50	50
(n = 8)	25	75
(n = 8)	0	100

**Table 2. Randomized selection of graft**

Animal no.	Right maxillary sinus	Left maxillary sinus
1	1	2
2	1	3
3	1	4
4	1	5
5	2	1
6	3	1
7	4	1
8	5	1
9	2	3
10	2	4
11	2	5
12	3	2
13	4	2
14	5	2
15	3	4
16	3	5
17	4	3
18	5	3
19	4	5
20	5	4

1: 100% autogenous bone.  
 2: 75% autogenous bone and 25% Bio-Oss.  
 3: 50% autogenous bone and 50% Bio-Oss.  
 4: 25% autogenous bone and 75% Bio-Oss.  
 5: 100% Bio-Oss.

fissure bur during continuous cooling with sterile saline solution and chisel.

Bone graft harvesting from mandible

The lateral and inferior mandibular border was exposed through a submandibular skin incision and the tissues were dissected to expose the mandible. The mental foramen including the neurovascular bundle was identified and protected. A 6 × 1.5 cm cortical bone graft involving the lateral and inferior cortex was harvested with fissure bur during continuous cooling with sterile saline solution and chisel.

Bone graft

The harvested bone was particulated by a bone-mill (Roswitha Quéting DentalProdukte, Leimen, Germany) with 3-mm perforations to obtain bone graft particles with a size of 0.5–2 mm<sup>3</sup>. To achieve a standardized total graft volume of 5 cm<sup>3</sup> in each maxillary sinus, four stainless steel measuring cups with volumes of 5, 3.75, 2.50, and 1.25 cm<sup>3</sup>, respectively, were used. The selected ratio of autogenous bone and Bio-Oss (particle size: 1–2 mm) was mixed and soaked in autogenous blood from an ear vein until use.

Maxillary sinus floor augmentation and implant placement

Maxillary sinus floor augmentation and implant placement were performed according to the procedure previously described (Terheyden et al. 1999). Briefly, the lateral maxillary sinus wall was exposed through a skin incision below the lower eyelid. A 1 × 1 cm

window to the maxillary sinus was created with bur, and the Schneiderian membrane was carefully elevated with blunt dissectors. The maxillary sinus wall just posterior to the window created was reduced to a thickness of 5 mm and an implant bed was successively prepared by 2-mm and 3-mm twist drills at 800 rpm. An oral implant (Brånemark, 4.0 × 15 mm, RP, TiUnite; Nobel Biocare AB, Sweden) was inserted with primary stability and a cover screw. The graft selected was packed around the implant, and the created window was covered by a membrane (Bio-Gide; Geistlich Pharma AG, Wolhusen, Switzerland, 25 × 25 mm).

### Sequential fluorochrome labelling

The bone-to-implant formation was assessed by sequential fluorochrome labelling using four calcium-binding fluorescent dyes according to Table 3 (Terheyden et al. 1999). The fluorochromes were administered by intraperitoneal injection under sedation with a mixture of 30 mg ketamine (Ketaminol; Intervet International B.V., Boxmeer, The Netherlands) and 2 mg xylazine (Rompun; Bayer HealthCare AG, Leverkusen, Germany) administered intramuscularly.

### Euthanasia and perfusion

The animals were euthanized after 12 weeks and perfused by Ringer and formaldehyde solutions according to the procedure described previously for cynomolgus monkeys (Schou et al. 2002, 2003). The mini pigs were deeply anaesthetized and a midsternal incision followed by a sternal split was performed. Pars abdominalis aortae and vena cava inferior were clamped and a 5-mm incision was made in the left cardiac ventricle. A perfusion tube with a 5-mm outer diameter was inserted and the right cardiac atrium was perforated. The perfusion was performed through the inserted infusion tube with 10 l neutral buffered Ringer solution (2500 ml/min, 20°C) containing heparin (Heparin 5.000 IE/l; Løvens Kemiske Fabrik, Ballerup, Denmark) and procaine hydrochloride (Procaine hydrochloride 1 g/l; Sigma, St. Louise, MO, USA). Heparin and procaine were added to prevent blood coagulation and vessel contraction. The perfusion with Ringer solution was directly continued with 10 l 10% neutral buffered formaldehyde solution (2500 ml/min, 20°C). The perfusion equipment consisted of four glass bottles (Duran Laboratory Bottle; Schott Glas 5.000 ml, Mainz, Germany), two with Ringer solution and two with formaldehyde solution. An adjustable air-pressure pump (Air Cadet; Cole-Parmer

**Table 3.** Intraperitoneal injection of fluorochromes

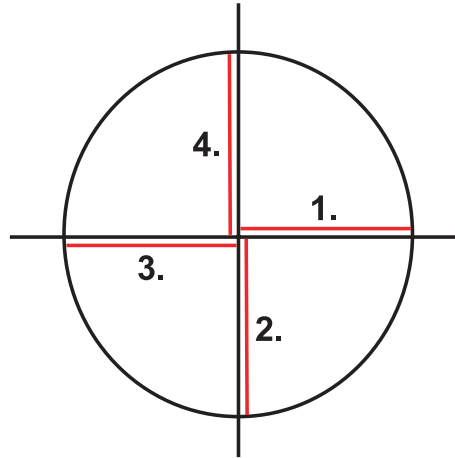
Week	Fluorochromes	Dose (ml/kg body weight)
2	Xylenol orange (6% in 2% NaHCO <sub>3</sub> solution)	1.5
3	Xylenol orange (6% in 2% NaHCO <sub>3</sub> solution)	1.5
4	Calcein green (1% in 2% NaHCO <sub>3</sub> solution)	5.0
5	Calcein green (1% in 2% NaHCO <sub>3</sub> solution)	5.0
6	Alizarincomplexon (3% in 2% NaHCO <sub>3</sub> solution)	0.8
7	Alizarincomplexon (3% in 2% NaHCO <sub>3</sub> solution)	0.8
8	Doxycycline	1.0
9	Doxycycline	1.0

Instrument, Barrington, IL, USA) was first attached to the two bottles with Ringer solution by plastic tubes. A plastic tube from each bottle was attached to a tap, thereby enabling continuous flow of Ringer solution followed by formaldehyde solution through the perfusion tube. Two tissue blocks containing each of the maxillary sinuses were resected and stored in neutral buffered formaldehyde solution at 20°C until initiation of the histological procedures.

#### Histology and fluorescence microscopy

To provide blinding of the histological and stereological evaluation, the tissue specimens were coded before undecalcified sections of the maxillary sinuses including the inserted implants were prepared using the cutting-grinding procedure (300 CP Band Saw System; EXAKT Apparatebau, Norderstedt, Germany). The tissue blocks were initially trimmed to contain exclusively the implant and the augmented region using the band saw and an X-ray-guided technique (Schou et al. 2002, 2003). The specimens were dehydrated in ethanol and embedded in methyl methacrylate-based resin (Technovit 7200 VLC; Kulzer, Friedrichsdorf, Germany) by including a 30-min vacuum period. The specimens were randomly rotated around the vertical implant axis and divided into two tissue blocks longitudinally to the vertical implant axis by the band saw and the X-ray-guided technique. Each of the two tissue blocks were finally divided perpendicular to the previous cutting direction longitudinally to the vertical implant axis. Consequently, each tissue block was divided into four parts (Fig. 1). One section with a thickness of 30 µm was obtained from each of the four locations. A new section was prepared, if the first was lost during the grinding procedure.

The sections were initially analyzed using a fluorescence microscope (Leica DM5000B; Leica Geosystems AG, Heerbrugg, Switzerland) equipped with Leica Application Suite (Version 2.8.1; Leica Geosystems AG). The xylenol orange, calcein green, alizarincomplexon, and doxycycline fluorescence were detected at 546, 505, 530, and 390 nm wavelengths, respectively. The sections were digi-

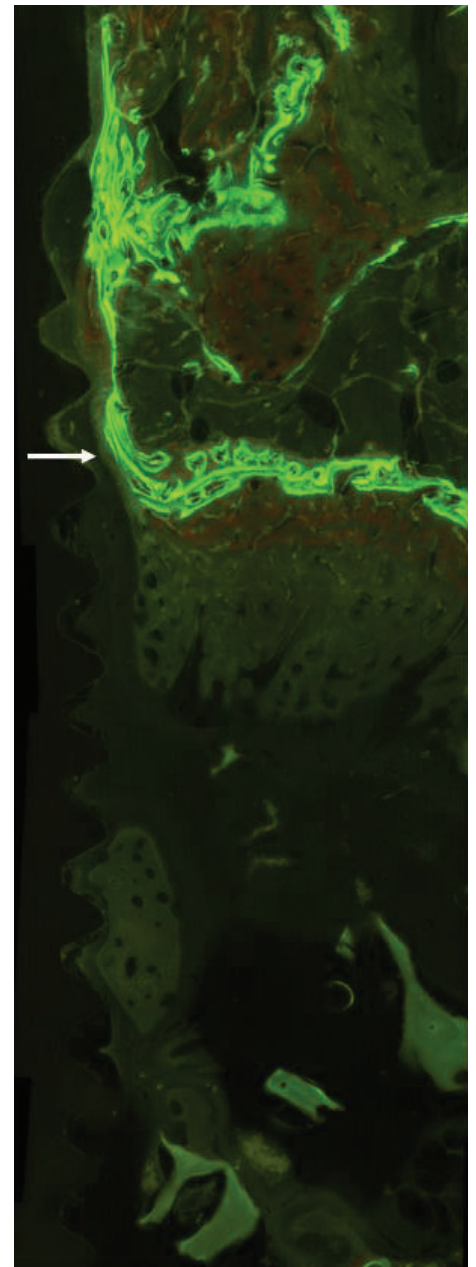


**Fig. 1.** Each specimen was randomly rotated around the vertical implant axis and divided into two tissue blocks longitudinally to the vertical implant axis. Each of the two tissue blocks were finally divided perpendicular to the previous cutting direction longitudinally to the vertical implant axis. Consequently, each tissue block was divided into four parts. One section was obtained from each of the four parts (1, 2, 3, and 4).

tized by taking 20–40 individual digital images of each section. The individual fluorochrome images of each section were transferred to a desktop and aligned into one image involving the entire implant surface with surrounding tissue using a panoramic stitching software program (PTGui Pro, Version 9.0.3; New House Internet Services B.V., Rotterdam, The Netherlands).

Staining was performed with Stevenel's blue and alizarin red S (Cerro et al. 1980; Maniopoulos et al. 1986) before coverslipping with glass coverslips and Technovit 7200 VLC. The sections were scanned (NanoZoomer Digital Pathology, 2.0, System C9600; Hamamatsu Photonics K.K., Higashi-ku, Japan) and transferred to a desktop. Thus, two images were obtained from each section, namely one fluorochrome image and one histological image stained with Stevenel's blue and alizarin red S.

The fluorochrome image was made slightly transparent and superimposed onto the histological image using Adobe Photoshop (Version CS2, 9.0; Adobe Systems, San Jose, CA, USA). Identical magnification of the two images was ensured by adjusting the magnification of the



**Fig. 2.** The demarcation of the original border of the maxillary sinus was approximated by the fluorochrome labelling (arrow) and the intraoperatively standardized maxillary sinus wall thickness of 5 mm.

fluorochrome image. The demarcation of the original border of the maxillary sinus was approximated based on the fluorochrome labelling and the preoperative standardization of the maxillary sinus wall thickness (Fig. 2). As previously described, the sinus wall was reduced to a thickness of 5 mm before implant placement (Jensen et al. 2011).

A general description of the fluorochrome images as well as the histological images was performed initially.

The proportion (%) of bone-to-implant contact was estimated on the four sections. A



fixed systematic set of straight parallel test lines was superimposed at random over the two images perpendicular to the vertical implant axis with the first line positioned at a random vertical position allowing a total of 100–200 test lines on the four sections to hit the implant surface within the augmented region (Fig. 3) (Weibel 1979; Gundersen et al. 1981; Schou et al. 2003). Presence or absence of bone-to-implant contact was registered at all intersections between test lines and the implant surface within the previous maxillary sinus at  $\times 1.4$  magnification. Moreover, the color of the fluorochrome labelling was recorded for each intersection.

The proportion  $S_s$  (%) of the implant surface covered by regenerated bone within the previous maxillary sinus was estimated using the following equation:

$$S_s(\text{bone/implant, maxillary sinus}) = \frac{\sum_{i=1}^4 (I(+\text{bone}))}{\sum_{i=1}^4 (I(\text{total}))} \times 100$$

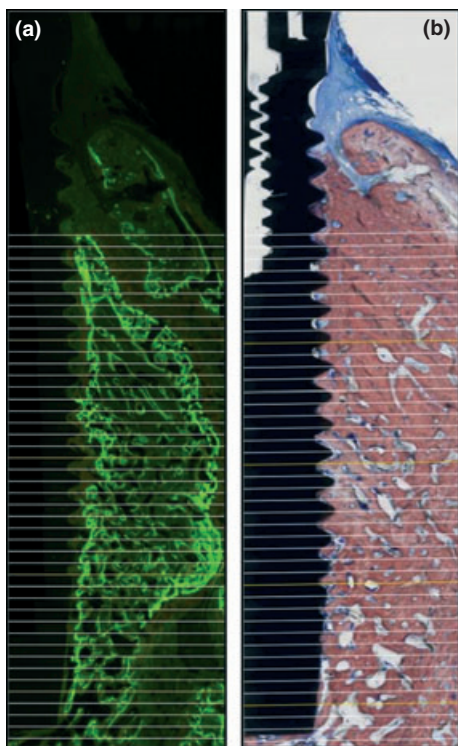


Fig. 3. A fixed systematic set of straight parallel test lines randomly superimposed over the fluorochrome image (a) perpendicular to the vertical implant axis with the first line positioned randomly. The fluorochrome image was superimposed on the sections stained with Stevenel's blue and alizarin red S (b) (not shown). The fluorochrome image was made slightly transparent and bone-to-implant contact was assessed at each intersection between test lines and implant surface. Moreover, the color of the fluorochrome labelling was registered at each intersection between test lines and implant surface.

$I(+\text{bone})$  is the number of lines hitting the implant surface with bone contact within the previous maxillary sinus, and  $I(\text{total})$  is the total number of lines hitting the implant surface within the previous maxillary sinus.

Similarly, based on the registrations of the fluorochrome labelling of each intersection, the proportion (%) of the implant covered by regenerated bone at week 2–3 (Xylenol orange), 4–5 (Calcein green), 6–7 (Alizarin complexon), and 8–9 (Doxycycline) was estimated.

#### Evaluation of stereological procedure

To evaluate the stereological procedure, the coefficient of variation (CV) (SD/mean) was calculated based on the original estimates. Moreover, the entire counting procedures, including superimposing of the fluorochrome and the histological images and the demarcation of the original border of the maxillary sinus were repeated on eight randomly selected animals (16 sinuses), and the coefficient of error (CE) (SEM/mean) based on the differences between the first and second set of estimates was calculated. Moreover, the differences between the repeated estimates were examined against the corresponding means by a scatter diagram (Bland & Altman 1986). The same investigator (TJ) performed all recordings.

#### Data management and statistical analysis

Data management and analysis including calculation of descriptive statistics were carried out by means of the statistical software R version 2.13.0 (R Development Core Team 2011), in particular the nlme package (Pinheiro et al. 2011). The primary descriptive variable was the bone-to-implant contact. The secondary descriptive variables were the proportions (%) of the implant covered by regenerated bone at week 2–3, 4–5, 6–7, and 8–9 based on the fluorochrome labelling. Results were summarized as median percentage with 95% confidence interval (95% CI).

The descriptive variables were analyzed in a random effect ANOVA model for normally distributed data. The proportions were not normally distributed, why the data were transformed prior to the analysis of variance. The logit (or log-odds)-transformation was the most suitable transformation to achieve an approximate normal distribution. The following explanatory variables were included in the model: Origin of the autogenous bone graft (mandible, iliac crest), and the ratio of Bio-Oss and autogenous bone, and side (right, left). Further, mini pig (a categorical variable with 40 levels, represented by animal num-

ber) was included in the model as a random effect. The logit transformed the proportions to the logarithm of their odds (i.e. ratio between bone-to-implant contacts and non-bone-to-implant contacts). Hence, after back-transformation with the exponential function, differences between the groups were described as *ratios of median odds* (reported with 95% CI). E.g. if the median odds ratio equals two this would mean that the median ratio of bone-to-implant contacts to non-bone-to-implant contacts in one group is twice as high as in the group it is compared to.

## Results

Intra- and postoperative complications have been described in detail previously (Jensen et al. 2011). Assessment of the bone-to-implant contact was impossible in eight sinuses due to separation of the interface between tissue and implant surface: One with 100% iliac bone, one with 75% iliac bone and 25% BO, two with 50% iliac bone and 50% BO, two with 75% mandibular bone and 25% BO, and two with 100% BO.

#### General histological description

The original border of the maxillary sinus could be identified by the fluorochrome labelling. The fluorochrome images showed various stages of new bone formation. However, when autogenous bone was used as graft, the bone remodelling activity appears to be more advanced. In contrast, sinuses augmented solely with BO showed negligible fluorochrome labelling. The fluorochrome labelling indicated that the new bone formation occurred primarily from the original bone of the sinus extending into the augmented region.

The histological images stained with Stevenel's blue and alizarin red S showed that precise differentiation between newly formed bone, residual autogenous bone graft, and original bone was difficult. The bone formation appeared more homogenous after use of autogenous bone, whereas sinuses augmented with BO showed that the BO particles within the central part of the augmented region frequently were embedded entirely in connective tissue, whereas particles adjacent to the original bone were mainly surrounded by newly formed bone.

#### Bone-to-implant contact

The estimates of bone-to-implant contact are presented in Fig. 4. The median bone-to-implant contact was: A) 42.9% (95% CI: 32.1

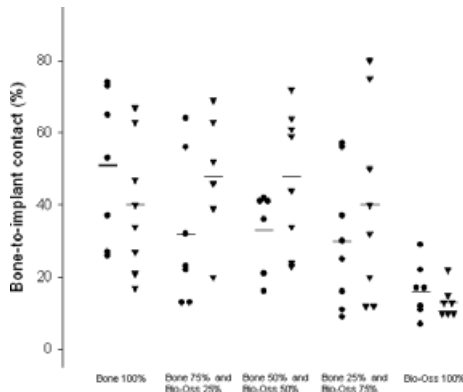


Fig. 4. Bone-to-implant contact (%). (●: iliac bone; ▼: mandibular bone; -: median).

–54.5%), B) 37.8% (95% CI: 27.1–49.9%), C) 43.9% (95% CI: 32.6–55.9%), D) 30.2% (95% CI: 21.6–40.3%), and E) 13.9% (95% CI: 11.4–16.9%). The bone-to-implant contact was significantly higher for A, B, C, D as compared to E ( $P < 0.0001$ ). The bone-implant-contact was not significantly influenced by the origin of the autogenous bone ( $P = 0.72$ ), i.e. iliac and mandibular bone, but by the side (OR = 1.41 CI: 1.06–1.87) ( $P = 0.02$ ). Images with bone-to-implant contact close to the median values of the different treatment groups are presented in Figs 5 and 6.

#### Bone-to-implant contact formation

The estimates of bone-to-implant contact formation according to the sequential fluorochrome labelling are presented in Fig. 7 and Table 4. The labelling revealed extensive variation between the groups as well as within the individual groups. However, the labelling at weeks 2–3 was significantly increased with A compared to E (OR = 8.1 CI: 5.0–13.1,  $P < 0.0001$ ), while E showed a significantly increased labelling at weeks 8–9 compared to A (OR = 0.5 CI: 0.3–0.7,  $P = 0.0028$ ). The total fluorochrome labelling at weeks 2–9 was significantly increased for A, B, C, and D as compared to E (OR = 2.2, 95% CI: 1.4–3.5,  $P < 0.0001$ ). The fluorochrome labelling was not influenced by the origin of the autogenous bone ( $P = 0.72$ ). Images with fluorochrome labelling of the bone-to-implant contact formation close to the median values of the different treatment groups are presented in Figs 8 and 9.

#### Evaluation of stereological procedure

The mean CVs of the bone-to-implant contact varied between 32% and 66%. The corresponding mean CEs varied between 12% and 24%. A scatter diagram showed no relation between the differences of the repeated estimates against the corresponding means

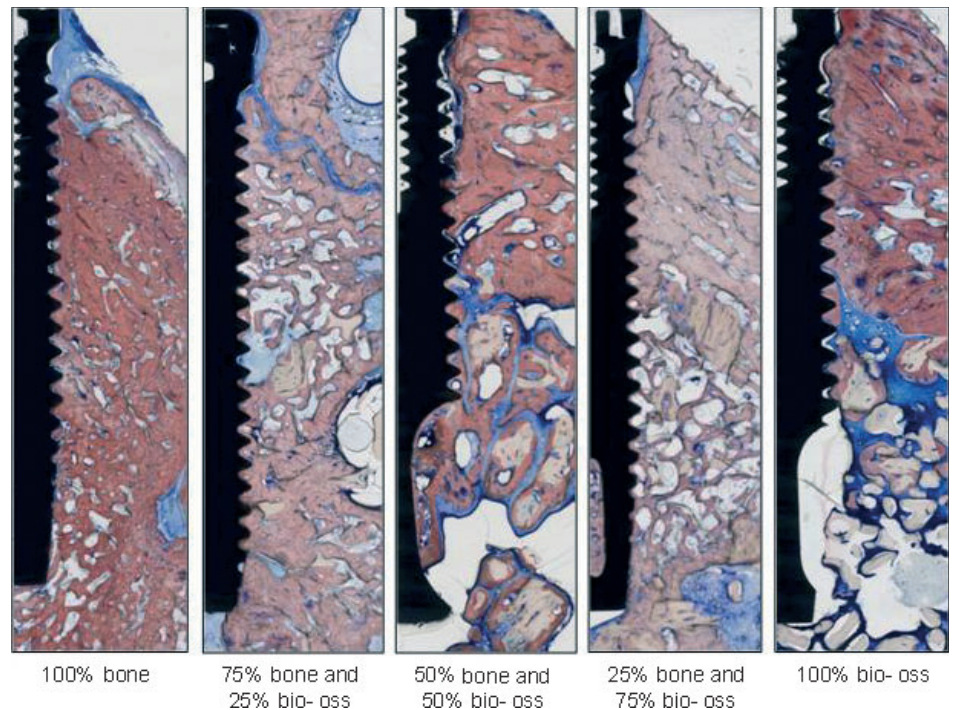


Fig. 5. Histological features after maxillary sinus floor augmentation with bovine origin BO and iliac bone. Stained with Stevenel's blue and alizarin red S.

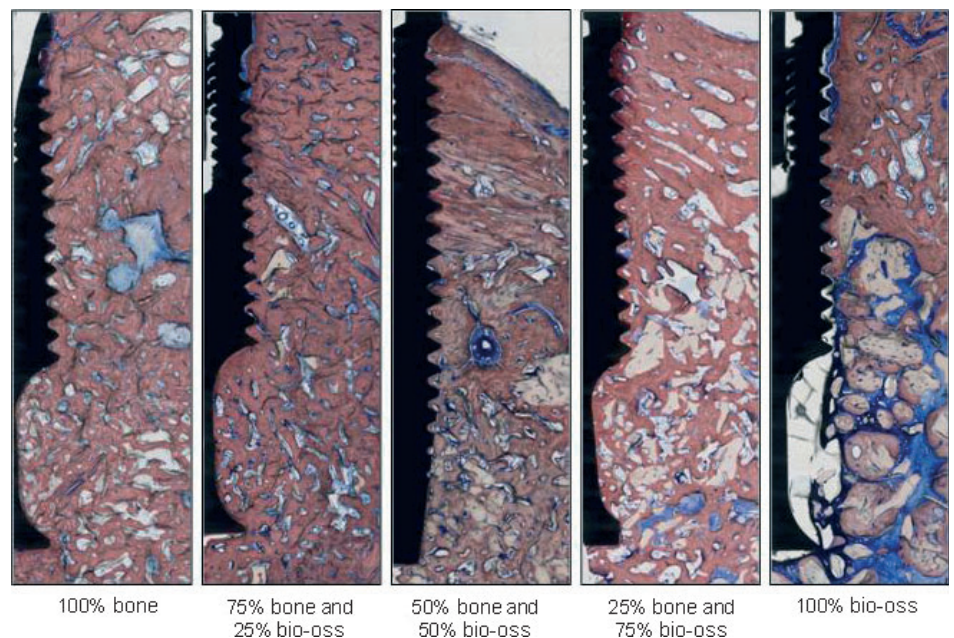


Fig. 6. Histological features after maxillary sinus floor augmentation with bovine origin BO and mandibular bone. Stained with Stevenel's blue and alizarin red S.

(Bland & Altman 1986). The analysis of the repeated estimates of the bone-to-implant contact showed that the total number of test lines hitting the implant surface on the second estimates was within –3.4–3.8% of the test lines hitting the implant surface on the first estimates with an estimated bias of 0.2% which is statistically insignificant ( $P = 0.66$ ) (Fig. 10). Similar results were

obtained for the repeated fluorochrome labelling (not reported).

#### Discussion

The bone-to-implant contact formation after maxillary sinus floor augmentation with BO and autogenous bone in different ratios was



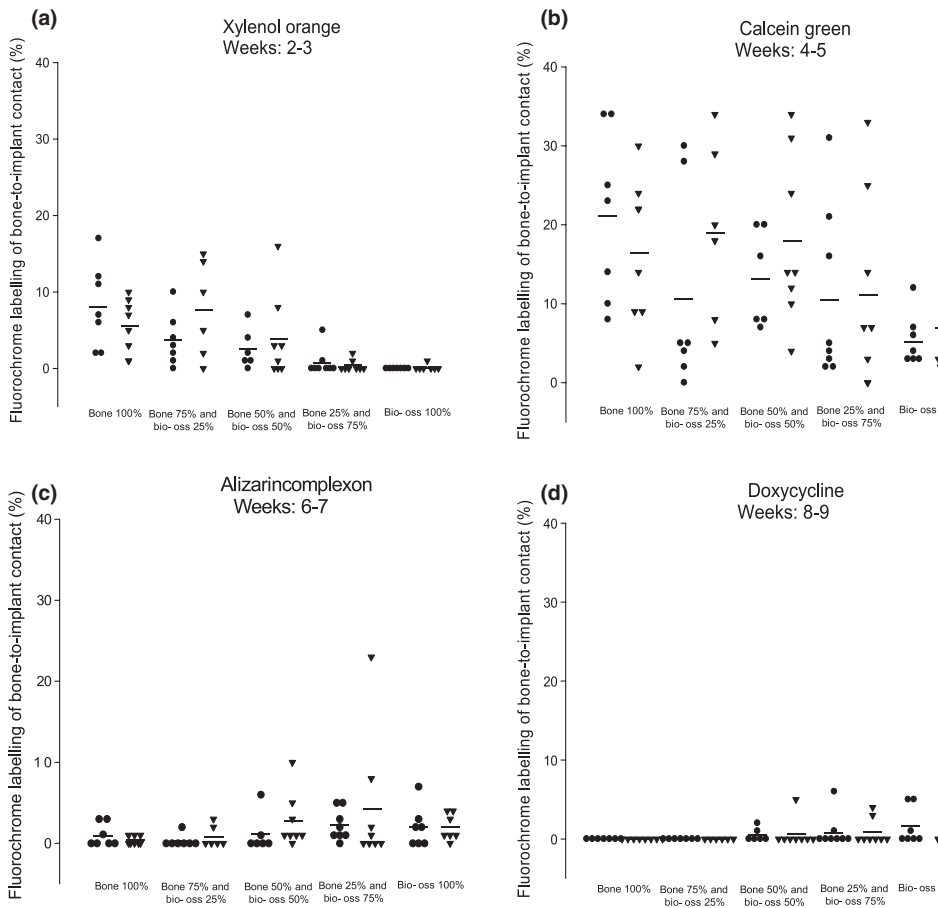


Fig. 7. Sequential fluorochrome labelling of bone-to-implant contact with xylenol orange (a), calcein green (b), alizarincomplexon (c), and doxycycline (d). (●: iliac bone; ▼: mandibular bone; -: median).

evaluated in mini pigs after 12 weeks. Stereological methods in combination with sequential fluorochrome labelling have not previously been used for the assessment of the bone-to-implant contact formation after maxillary sinus floor augmentation with BO and autogenous bone in different ratios. It was concluded that the bone-to-implant contact was significantly higher when autogenous bone or BO mixed with autogenous bone in different ratios were used as compared to BO alone. In addition, fluorochrome labelling indicated that the early bone-to-implant contact formation adjacent to the implant surface was more advanced with autogenous bone compared to BO.

Systematic uniform random sampling at all levels of the stereological procedure is mandatory for obtaining unbiased and efficient estimates (Gundersen et al. 1999). Unbiased estimates of surface area can be obtained by using the vertical section technique and a systematic test system of cycloids (Baddeley et al. 1986). The present study focused on estimates of the proportion (%) of the bone-to-implant contact and not on estimates of

the total surface area. Therefore, the specimens were randomly rotated around the vertical implant axis and divided into four tissue blocks longitudinally to the vertical implant axis. Systematic random procedures were included in the following steps of the counting procedures, while efficient and unbiased estimates of the proportion of the bone-to-implant contact were obtained.

The observed total variance of stereological estimates is a combination of a real difference between the specimens (i.e. biologic variation) and variation added by the stereological procedure (i.e. methodological variation). The stereological procedure of the present study was assessed by the coefficient of error (CE) (SEM/mean) for the primary outcome variable. The CVs were always higher than the corresponding CEs, why the variance of the estimates was caused mainly by a real difference between the specimens (i.e. "biologic variation") and not by errors associated with the stereological method.

Sequential fluorochrome labelling has previously been used in animal studies to evaluate new bone formation over time after

Table 4. Median percentages of sequential fluorochrome color labelling with 95% confidence intervals (95% CI)

Fluorochromes	Bone 100% (A)	Bone 75% and Bio-Oss 25% (B)	Bone 50% and Bio-Oss 50% (C)	Bone 25% and Bio-Oss 75% (D)	Bio-Oss 100% (E)
Xylenol orange	5.7% (95% CI: 3.6–8.9%)	4.1% (95% CI: 2.2–7.2%)	2.3% (95% CI: 1.4–3.8%)	0.8% (95% CI: 0.6–1.1%)	0.7% (95% CI: 0.6–0.8%)
Calcein green	14.9% (95% CI: 9.9–21.8%)	10.8% (95% CI: 6.5–17.5%)	15.5% (95% CI: 12.3–19.3%)	6.6% (95% CI: 4.1–10.5%)	4.4% (95% CI: 3.4–5.7%)
Alizarin-complexon	0.7% (95% CI: 0.5–1.0%)	0.9% (95% CI: 0.6–1.2%)	1.8% (95% CI: 1.1–2.9%)	1.9% (95% CI: 1.2–3.0%)	2.4% (95% CI: 1.6–3.6%)
Doxycycline	0.5% (95% CI: 0.4–0.7%)	0.6% (95% CI: 0.4–0.8%)	0.9% (95% CI: 0.6–1.2%)	0.9% (95% CI: 0.6–1.4%)	1.0% (95% CI: 0.7–1.6%)



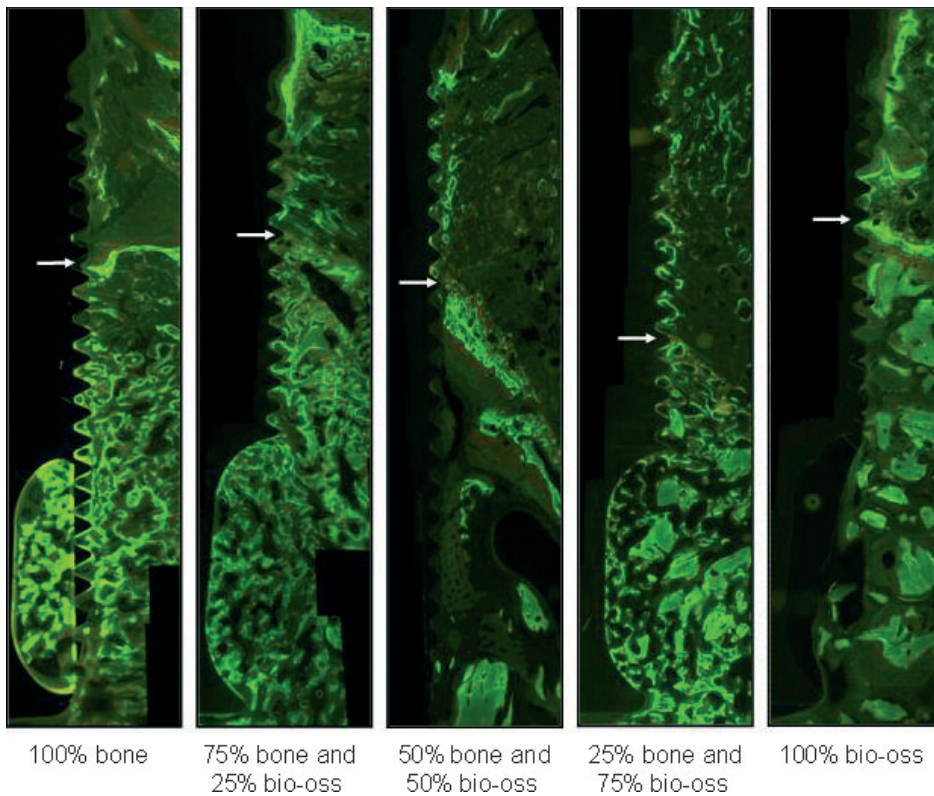


Fig. 8. Features of sequential fluorochrome labelling after maxillary sinus floor augmentation with bovine origin BO and iliac bone. Original border of the maxillary sinus (arrow).

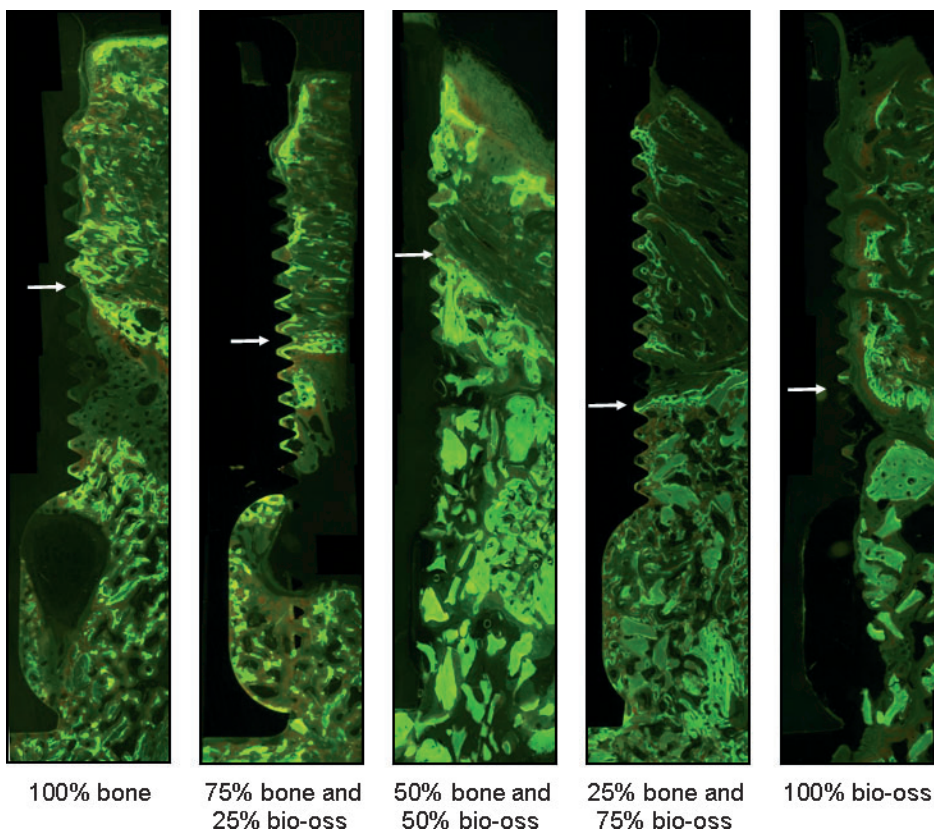


Fig. 9. Features of sequential fluorochrome labelling after maxillary sinus floor augmentation with bovine origin BO and mandibular bone. Original border of the maxillary sinus (arrow).

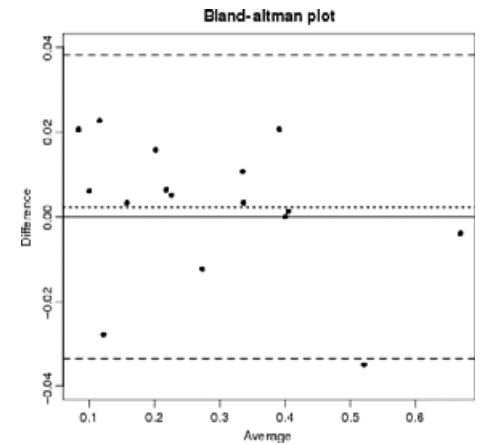


Fig. 10. Bland-Altman plot of repeated estimates of bone-to-implant contacts. The dotted line marks the estimated insignificant bias and the dashed lines represent 95% limits of agreement.

maxillary sinus floor augmentation with Bio-Oss or autogenous bone (Haas et al. 1998; Terheyden et al. 1999; Fürst et al. 2003; Butterfield et al. 2005; Jiang et al. 2009; Gutwald et al. 2010). However, fluorochromes have not previously been applied to assess the bone-to-implant contact formation. The evaluation of bone-to-implant contact within the augmented region necessitates identification of the original border of the maxillary sinus. The demarcation of the original border between the graft and the maxillary sinus becomes indistinct as the graft integrates. Therefore, the original border of the maxillary sinus was approximated in the present study based on the fluorochrome labelling and the intraoperative standardization of the maxillary sinus wall thickness. This method appears to enable a reliable delineation of the augmented sinus.

Bone-to-implant contact after maxillary sinus floor augmentation with BO, BO mixed with autogenous bone, and autogenous bone has previously been assessed in humans (Hallman et al. 2002; Lindgren et al. 2009) and animals (Wetzel et al. 1995; Hürzeler et al. 1997; Haas et al. 1998; Terheyden et al. 1999; Fürst et al. 2003; Schlegel et al. 2003, 2007). Bone-to-implant contact after using BO, BO mixed with autogenous bone, and autogenous bone has exclusively been compared only in one human study (Hallman et al. 2002). The study involved experimental microimplants and sinus floor augmentation with BO, a mixture of 80% BO and 20% autogenous mandibular bone, and autogenous mandibular bone (Hallman et al. 2002). No statistically significant difference in bone-to-implant contact was found for BO (32%) as compared to BO mixed with autogenous bone

(54%), or autogenous bone (35%). However, the healing periods of the experimental groups were different, i.e. 6.5 months for autogenous bone, 6.5 months for BO mixed with autogenous bone, and 8.5 months for BO (Hallman et al. 2002). In addition, the study included only one ratio of BO and autogenous bone, i.e. 80% BO and 20% mandibular bone. The results of the present study are not in accordance with the results of the above mentioned study, presumably due to different healing periods. Thus, it is likely that a prolonged healing period diminishes the observed differences between the groups in the present study.

A histomorphometric meta-analysis based on 30 studies focused on maxillary sinus floor augmentation with bone substitutes, bone substitutes mixed with autogenous bone, and autogenous bone (Handschel et al. 2009). After 4 months, the total bone volume after using autogenous bone was significantly increased as compared to BO or BO mixed with autogenous bone. In contrast, no significant differences were reported after 9 months. The meta-analyses therefore support the above mentioned hypothesis, that a prolonged healing period diminishes the differences between the groups in the present study, due to increased bone formation. However, previously performed experimental studies using domes in rats have indicated that BO may hamper bone regeneration. (Stavropoulos et al. 2001, 2003, 2004). Therefore, additional studies comparing various healing period are needed before final conclusions can be made.

The proportion of vital bone within the sinus after using two different mixtures of BO and autogenous bone harvested from the lateral wall of the maxilla has been evaluated in one human study (Galindo-Moreno et al. 2011). No statistically significant difference in vital bone and non-mineralized tissue was found for 50% BO and 50% autogenous bone as compared to 80% BO and 20% autogenous bone after 6 months. However, a higher number of osteoid lines and an increased cellular activity were observed when the graft contains a higher proportion of autogenous bone. Therefore, additional studies with different healing periods are needed to increase our knowledge about maxillary sinus floor augmentation with different ratios of BO and autogenous bone.

Bone-to-implant contact after maxillary sinus floor augmentation with BO, BO mixed with autogenous bone, and autogenous bone grafts has never been compared in animal

studies. However, BO and autogenous bone have been compared in three studies (Haas et al. 1998; Schlegel et al. 2003, 2007). Statistical analysis was conducted in only one study demonstrating no significant differences in bone-to-implant contact in sheep after 12, 16, and 26 weeks (Haas et al. 1998). When BO was used, the bone-to-implant contact was 27%, 24%, and 35% after 12, 16, and 26 weeks, respectively. The corresponding figures were 30%, 32%, and 36% for autogenous bone. It is unknown why the present results differ from those of the above mentioned study, but the discrepancies may be due to different experimental designs, i.e. different animal models and quantitation procedures.

Bone-to-implant contact formation was assessed by sequential fluorochrome labelling in the present study. With autogenous bone, the early bone-to-implant contact formation appears to be more advanced than with BO as revealed by the significantly increased fluorochrome labelling after 2–3 weeks. In contrast, with BO, the bone-to-implant contact formation appears to be delayed as revealed by the significantly increased fluorochrome labelling after 8–9 weeks. Moreover, the labelling showed significantly enhanced total activity with autogenous bone or BO mixed with autogenous bone as compared to BO. Therefore, the present study indicated that BO delays the bone-to-implant contact formation as compared to autogenous bone. However, it should be emphasized that all assessed intersections between test lines and the implant surface were not characterized by fluorochrome staining properly due to bone-to-implant contact formation at other time points than included in the fluorochrome labelling regimen.

The new bone formation occurred primarily from the original bone of the sinus extending into the augmented region. These results are in accordance with a study in monkeys showing new bone formation in continuity with the original bone when no graft was used (Scala et al. 2011). In the present study a significant difference between iliac and mandibular bone was expected due to different osteogenic potential (Khan et al. 2005). However, no difference was observed indicating that differences between autogenous bone graft from the iliac crest and the mandible may not influence the bone-to-implant contact formation after maxillary sinus floor augmentation. The background of the present minute difference in bone-to-implant contact

between the right and left sinus are not immediately explainable.

The present study focused on the bone-to-implant contact formation. Assessment of different graft materials also includes estimates of newly formed bone. The sections were stained with Stevenel's blue and alizarin red S and precise separation of newly formed bone, residual autogenous bone graft, and original bone was difficult. A pilot study revealed that precise separation was also difficult when staining with Toluidine blue method was used. Stereological estimates of the total amount of bone within the different groups will be reported in a subsequent publication.

In conclusion, the hypothesis of no differences in bone-to-implant contact between the various treatment modalities was rejected since the bone-to-implant contact was significantly increased with autogenous bone or BO mixed with autogenous bone in different ratios as compared to BO. Furthermore, early bone-to-implant contact formation adjacent to the implant surface was more advanced with autogenous bone. No differences between the use of mandibular or iliac bone grafts were observed since the bone-to-implant contact was not significantly influenced by the origin of the bone graft. The present study as well as recently published study indicates that a mixture of autogenous bone and Bio-Oss should be used as graft material for the maxillary sinus floor augmentation for diminishing the resorption of the graft and for increasing bone-implant contact formation (Jensen et al. 2011). However, additional studies involving estimates of the total amount of new bone formation and different healing periods are needed before final conclusions can be made about the optimal ratio of BO and autogenous bone.

**Acknowledgements:** The authors are deeply indebted to Ms. Inge Stage, Ms. Birthe Gylling-Jørgensen, and Karen Biré for outstanding histological preparation, Mr. Jens Sørensen, Mr. Ole Sørensen, and Mr. Torben Madsen for comprehensive help with the studies including excellent handling of the animals, and Ms. Anni Wehrmann Pedersen, Ms. Jette Bruun, and Ms. Lene Bjerg Jensen for invaluable assistance during the surgical procedures. Bio-Oss and Bio-Gide membranes were kindly provided by Geistlich Pharma, Switzerland. Finally, we would like to thank Nobel Biocare AB, Sweden for the kind supply of implants. The study was supported



by grants from FUT/Calcin-fondene, KOF/Calcin-fondene, Det Obelske Familiefond, Nordjyllands Amts Forskningsråd, Direktør

E. Danielsens og Hustrus Fond, Familien Hede Nielsens Fond, Gangstedfonden, Augustinus Fonden, Speciallæge Heinrich

Kopp's Legat, Else og Mogens Wedell-Wedellsborgs Fond, and Peder Kristen Tøfting samt Dagmar Tøfting's Fond.

## References

- Baddeley, A.J., Gundersen, H.J.G. & Cruz-Orive, L.M. (1986) Estimation of surface area from vertical sections. *Journal of Microscopy* **142**: 259–276.
- Bland, J.M. & Altman, D.G. (1986) Statistical methods for assessing agreement between two methods of clinical measurements. *Lancet* **1**: 307–310.
- Browaeys, H., Bouvry, P. & Bruyn, H.D. (2007) A literature review on biomaterials in sinus augmentation procedures. *Clinical Implant Dentistry & Related Research* **9**: 166–177.
- Butterfield, K.J., Bennett, J., Gronowicz, G. & Adams, D. (2005) Effect of platelet-rich plasma with autogenous bone graft for maxillary sinus augmentation in a rabbit model. *Journal of Oral and Maxillofacial Surgery* **63**: 370–376.
- del Cerro, M., Cogen, J. & del Cerro, C. (1980) Stevenel's blue, an excellent stain for optical microscopical study of plastic embedded tissues. *Microscopic Acta* **83**: 117–121.
- Chiapasco, M., Casentini, P. & Zaniboni, M. (2009) Bone augmentation procedures in implant dentistry. *The International Journal of Oral & Maxillofacial Implants* **24**(Suppl.): 237–259.
- Esposito, M., Grusovin, M.G., Rees, J., Karasoulos, D., Felice, P., Alissa, R., Worthington, H.V. & Coulthard, P. (2010) Interventions for replacing missing teeth: augmentation procedures of the maxillary sinus. *Cochrane Database Systematic Reviews* **17**: CD008397.
- del Fabbro, M., Testori, T., Francetti, L. & Weinstein, R. (2004) Systematic review of survival rates for implants placed in the grafted maxillary sinus. *The International Journal of Periodontics & Restorative Dentistry* **24**: 565–577.
- Fürst, G., Gruber, R., Tangl, S., Zechner, W., Haas, R., Mailath, G., Sanroman, F. & Watzek, G. (2003) Sinus grafting with autogenous platelet-rich plasma and bovine hydroxyapatite. A histomorphometric study in minipigs. *Clinical Oral Implants Research* **14**: 500–508.
- Galindo-Moreno, P., Moreno-Riestra, I., Avila, G., Padial-Molina, M., Paya, J.A., Wang, H.L. & O'Valle, F. (2011) Effect of anorganic bovine bone to autogenous cortical ratio upon bone remodelling patterns following maxillary sinus augmentation. *Clinical Oral Implants Research* **22**: 857–864.
- Gundersen, H.J.G., Boysen, M. & Reith, A. (1981) Comparison of semiautomatic digitizer-tablet and simple point counting performance in morphometry. *Virchows Archiv B* **37**: 317–325.
- Gundersen, H.J.G., Jensen, E.B.V., Kiøu, K. & Nielsen, J. (1999) The efficiency of systematic sampling in stereology - reconsidered. *Journal of Microscopy* **193**: 199–211.
- Gutwald, R., Haberstroh, J., Kuschnierz, J., Kister, C., Lysek, D.A., Maglione, M., Xavier, S.P., Oshima, T., Schmelzeisen, R. & Sauerbier, S. (2010) Mesenchymal stem cells and inorganic bovine bone mineral in sinus augmentation: comparison with augmentation by autologous bone in adult sheep. *British Journal of Oral and Maxillofacial Surgery* **48**: 285–290.
- Haas, R., Donath, K., Födinger, M. & Watzek, G. (1998) Bovine hydroxyapatite for maxillary sinus grafting: comparative histomorphometric findings in sheep. *Clinical Oral Implants Research* **9**: 107–116.
- Hallman, M., Sennerby, L. & Lundgren, S. (2002) A clinical and histologic evaluation of implant integration in the posterior maxilla after sinus floor augmentation with autogenous bone, bovine hydroxyapatite, or a 20:80 mixture. *The International Journal of Oral & Maxillofacial Implants* **17**: 635–643.
- Handschel, J., Simonowska, M., Naujoks, C., Depprich, R.A., Ommerborn, M.A., Meyer, U. & Kübler, N.R. (2009) A histomorphometric meta-analysis of sinus elevation with various grafting materials. *Head & Face Medicine* **5**: 1–10.
- Hürzeler, M.B., Quinones, C.R., Kirsch, A., Gloker, C., Schüpbach, P., Strub, J.R. & Caffesse, R.G. (1997) Maxillary sinus augmentation using different grafting material and dental implants in monkeys. Part I. Evaluation of anorganic bovine-derived bone matrix. *Clinical Oral Implants Research* **8**: 476–486.
- Jensen, T., Schou, S., Svendsen, P.A., Andersen, G., Forman, J.L., Gundersen, H.J.G., Terheyden, T. & Holmstrup, P. (2011) Volumetric changes of the graft after maxillary sinus floor augmentation with Bio-Oss and autogenous bone in different ratios. A radiographic study in minipigs. *Clinical Oral Implants Research* [Epub ahead of print].
- Jensen, T., Schou, S., Stavropoulos, A., Terheyden, T. & Holmstrup, P. (2012) Maxillary sinus floor augmentation with Bio-Oss or Bio-Oss mixed with autogenous bone as graft: A systematic review. *Clinical Oral Implants Research* **23**: 263–273.
- Jensen, S.S. & Terheyden, H. (2009) Bone augmentation procedures in localized defects in the alveolar ridge: clinical results with different bone grafts and bone-substitutes materials. *The International Journal of Oral & Maxillofacial Implants* **24**(Suppl.): 218–236.
- Jiang, X.Q., Wang, S.Y., Zhao, J., Zhang, X.L. & Zhang, Z.Y. (2009) Sequential fluorescent labeling observation of maxillary sinus augmentation by a tissue-engineered bone complex in canine model. *International Journal of Oral Science* **1**: 39–46.
- Khan, S.N., Cammisia, F.P. Jr, Sandhu, H.S., Diwan, A.D., Girardi, F.P. & Lane, J.M. (2005) The biology of bone grafting. *Journal of the American Academy of Orthopaedic Surgeons* **13**: 77–86.
- Lindgren, C., Sennerby, L. & Hallman, M. (2009) Clinical histology of microimplants placed in two different biomaterials. *The International Journal of Oral and Maxillofacial Implants* **24**: 1093–1110.
- Maniopoulos, C., Rodriguez, A., Deporter, D.A. & Melcher, A.H. (1986) An improved method for preparing histological sections of metallic implants. *The International Journal of Oral & Maxillofacial Implants* **1**: 31–37.
- Nkenke, E. & Stelzle, F. (2009) Clinical outcomes of sinus floor augmentation for implant placement using autogenous bone or bone substitutes: a systematic review. *Clinical Oral Implants Research* **20**: 124–133.
- Pinheiro, J., Bates, D., DebRoy, S., Sarkar, D. & the R Core team (2011), nlme: Linear and Nonlinear Mixed Effects Models, R package version 3.1-100.
- Pjetursson, B.E., Tan, W.C., Zwahlen, M. & Lang, N.P. (2008) A systematic review of the success of sinus floor elevation and survival of implants inserted in combination with sinus floor elevation. *Journal of Clinical Periodontology* **35**: 216–240.
- R Development Core Team (2011) R: A language and environment for statistical computing. Vienna, Austria. ISBN 3-900051-07-0, URL <http://www.R-project.org>.
- Scala, A., Botticelli, D., Faeda, R.S., Rangel Garcia, I. Jr, de Oliveira, J.A. & Lang, N.P. (2011) Lack of influence of the Schneiderian membrane in forming new bone apical to implants simultaneously installed with sinus floor elevation: an experimental study in monkeys. *Clinical Oral Implants Research* **23**: 175–181.
- Schlegel, K.A., Fichtner, G., Schultze-Mosgau, S. & Wiltfang, W. (2003) Histologic findings in sinus augmentation with autogenous bone chips versus a bovine bone substitute. *The International Journal of Oral & Maxillofacial Implants* **18**: 53–58.
- Schlegel, K.A., Zimmermann, R., Thorwarth, M., Neukam, F.W., Klongnoi, B., Nkenke, E. & Felszeghy, E. (2007) Sinus floor elevation using autogenous bone or bone substitute combined with platelet-rich plasma. *Oral Surgery, Oral Medicine, Oral Pathology, Oral Radiology, and Endodontics* **104**: 15–25.
- Schou, S., Holmstrup, P., Skovgaard, L.T., Hjørting-Hansen, E. & Gundersen, H.J.G. (2003) Autogenous bone graft and ePTFE membrane in the treatment of peri-implantitis. II. Stereologic and histologic observations in cynomolgus monkeys. *Clinical Oral Implants Research* **14**: 404–411.
- Schou, S., Holmstrup, P., Stoltze, K., Hjørting-Hansen, E., Fiehn, N.E. & Skovgaard, L.T. (2002) Probing around implants and teeth with healthy or inflamed peri-implant mucosa/gingival. A histologic comparison in cynomolgus monkeys (*Macaca fascicularis*). *Clinical Oral Implants Research* **13**: 113–126.
- Stavropoulos, A., Kostopoulos, L., Mardas, N., Nyengaard, J.R. & Karring, T. (2001) Deproteinized bovine bone used as an adjunct to guided bone augmentation: an experimental study in rat. *Clinical Implant Dentistry and Related Research* **3**: 156–165.
- Stavropoulos, A., Kostopoulos, L., Nyengaard, J.R. & Karring, T. (2003) Deproteinized bovine bone

- (Bio-Oss) and bioactive glass (Biogran) arrest bone formation when used as an adjunct to guided tissue regeneration (GTR): an experimental study in the rat. *Journal of Clinical Periodontology* **30**: 636–643.
- Stavropoulos, A., Kostopoulos, L., Nyengaard, J.R. & Karring, T. (2004) Fate of bone formed by guided tissue regeneration with or without grafting of Bio-Oss or Biogran: an experimental study in the rat. *Journal of Clinical Periodontology* **31**: 30–39.
- Terheyden, H., Jepsen, S., Möller, B., Tucker, M.M. & Rueger, D.C. (1999) Sinus floor augmentation with simultaneous placement of dental implants using a combination of deproteinized bone xenografts and recombinant human osteogenic protein-1. A histometric study in miniature pigs. *Clinical Oral Implants Research* **10**: 510–521.
- Wallace, S.S. & Froum, S.J. (2003) Effect of maxillary sinus floor augmentation on the survival of endosseous dental implants. A systematic review. *Annals of Periodontology* **8**: 328–343.
- Weibel, E.R. (1979) *Stereological methods, Vol I, Practical Methods for Biological Morphometry*. London: Academic Press.
- Wetzel, A.C., Stich, H. & Caffesse, R.G. (1995) Bone apposition onto oral implants in the sinus area filled with different grafting materials. A histological study in beagle dogs. *Clinical Oral Implants Research* **6**: 155–163.