



AALBORG UNIVERSITY
DENMARK

Aalborg Universitet

Augmentation of implant surfaces with BMP-2 in a revision setting

effects of local and systemic bisphosphonate

Cleemann, Rasmus; Sorensen, Mette; West, Andreas; Soballe, Kjeld; Bechtold, Joan E;
Baas, Jorgen

Published in:
Bone & Joint Research

DOI (link to publication from Publisher):
[10.1302/2046-3758.108.BJR-2020-0280.R1](https://doi.org/10.1302/2046-3758.108.BJR-2020-0280.R1)

Creative Commons License
CC BY-NC-ND 4.0

Publication date:
2021

Document Version
Publisher's PDF, also known as Version of record

[Link to publication from Aalborg University](#)

Citation for published version (APA):
Cleemann, R., Sorensen, M., West, A., Soballe, K., Bechtold, J. E., & Baas, J. (2021). Augmentation of implant surfaces with BMP-2 in a revision setting: effects of local and systemic bisphosphonate. *Bone & Joint Research*, 10(8), 488-497. <https://doi.org/10.1302/2046-3758.108.BJR-2020-0280.R1>

General rights

Copyright and moral rights for the publications made accessible in the public portal are retained by the authors and/or other copyright owners and it is a condition of accessing publications that users recognise and abide by the legal requirements associated with these rights.

- Users may download and print one copy of any publication from the public portal for the purpose of private study or research.
- You may not further distribute the material or use it for any profit-making activity or commercial gain
- You may freely distribute the URL identifying the publication in the public portal -

Take down policy

If you believe that this document breaches copyright please contact us at vbn@aub.aau.dk providing details, and we will remove access to the work immediately and investigate your claim.



■ BONE BIOLOGY

Augmentation of implant surfaces with BMP-2 in a revision setting

EFFECTS OF LOCAL AND SYSTEMIC BISPHOSPHONATE

**R. Cleemann,
M. Sorensen,
A. West,
K. Soballe,
J. E. Bechtold,
J. Baas**

From Orthopedic
Research Laboratory,
Aarhus University
Hospital, Aarhus,
Denmark

Aims

We wanted to evaluate the effects of a bone anabolic agent (bone morphogenetic protein 2 (BMP-2)) on an anti-catabolic background (systemic or local zoledronate) on fixation of allografted revision implants.

Methods

An established allografted revision protocol was implemented bilaterally into the stifle joints of 24 canines. At revision surgery, each animal received one BMP-2 (5 µg) functionalized implant, and one raw implant. One group (12 animals) received bone graft impregnated with zoledronate (0.005 mg/ml) before impaction. The other group (12 animals) received untreated bone graft and systemic zoledronate (0.1 mg/kg) ten and 20 days after revision surgery. Animals were observed for an additional four weeks before euthanasia.

Results

No difference was detected on mechanical implant fixation (load to failure, stiffness, energy) between local or systemic zoledronate. Addition of BMP-2 had no effect on implant fixation. In the histomorphometric evaluation, implants with local zoledronate had more area of new bone on the implant surface (53%, $p = 0.025$) and higher volume of allograft (65%, $p = 0.007$), whereas implants in animals with systemic zoledronate had the highest volume of new bone (34%, $p = 0.003$). Systemic zoledronate with BMP-2 decreased volume of allograft by 47% ($p = 0.017$).

Conclusion

Local and systemic zoledronate treatment protects bone at different stages of maturity; local zoledronate protects the allograft from resorption and systemic zoledronate protects newly formed bone from resorption. BMP-2 in the dose evaluated with experimental revision implants was not beneficial, since it significantly increased allograft resorption without a significant compensating anabolic effect.

Cite this article: *Bone Joint Res* 2021;10(8):488–497.

Keywords: Bone anabolic, Anti-catabolic, Revision

Article focus

- Combined anabolic and anti-catabolic therapy in revision orthopedics.
- Experimental orthopedics.

Key messages

- Systemic and local zoledronate seems to retain bone at different maturity levels.
- No significant effect of bone morphogenetic protein 2 (BMP-2) on implant

fixation was detected with the applied dose and administration.

Strengths and limitations

- Validated experimental model.
- Results stem from animal experiments and cannot be translated into a clinical setting.

Correspondence should be sent to Rasmus Cleemann; email: rasmus.cleemann@clin.au.dk

doi: 10.1302/2046-3758.108.BJR-2020-0280.R1

Bone Joint Res 2021;10(8):488–497.

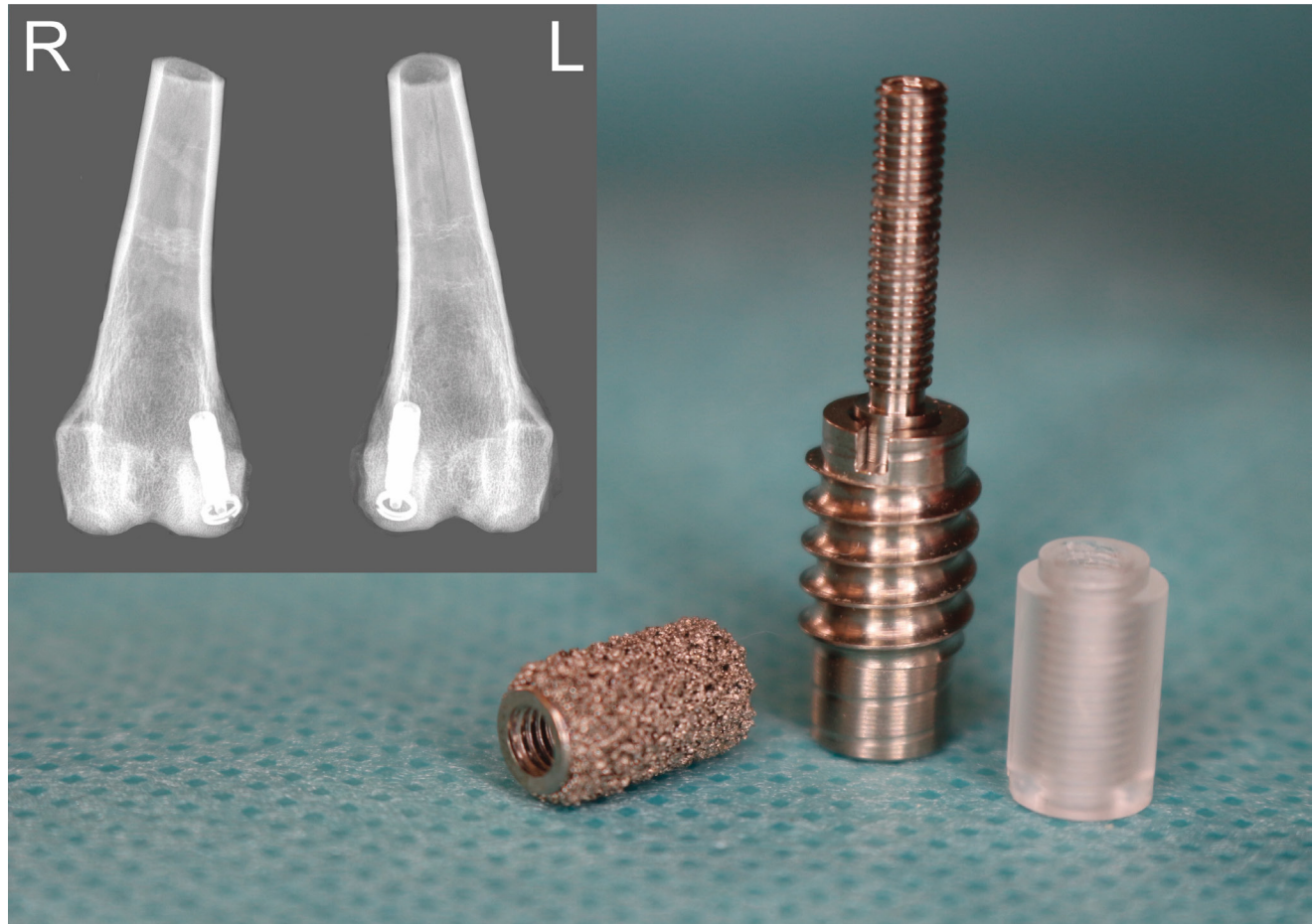


Fig. 1

Micromotion device (centre) with a titanium implant (left) and a poly(methyl methacrylate) (PMMA) implant (right). The micromotion device consists of a self-tapping anchor house (bottom) to secure device position in the subchondral cancellous bone of the medial femur condyle (radiograph upper left). A threaded rod on top of a coil spring sits inside the anchor house body, allowing for axial rod movement relative to the anchor-house (top). The coil spring returns the threaded rod to its original position after its compression during stand and gait. The primary PMMA implant has a 500 μm -high receded rim at its base, enabling it to slide a mean 500 μm (standard deviation (SD) 15 μm) inside the anchor house when axially compressed producing an unstable condition. The revision titanium implant has stable conditions by being seated directly on top of the anchor house, preventing the rod from moving axially.

Table I. Design revision with impacted allograft.

Group	Left stifle joint	Right stifle joint
Local zoledronate (n = 12)*	Implant + 5 μg rhBMP-2	Raw implant
Systemic zoledronate (n = 12)†	Implant + 5 μg rhBMP-2	Raw implant

Recombinant bone morphogenetic protein 2 treatment was assigned randomly between the left and the right stifle joints.

*Zoledronate soaked allograft (0.005 mg/ml).

†Zoledronate intravenous (IV) (0.1 mg/kg) ten and 20 days post revision surgery.

rhBMP-2, recombinant bone morphogenetic protein 2.

Introduction

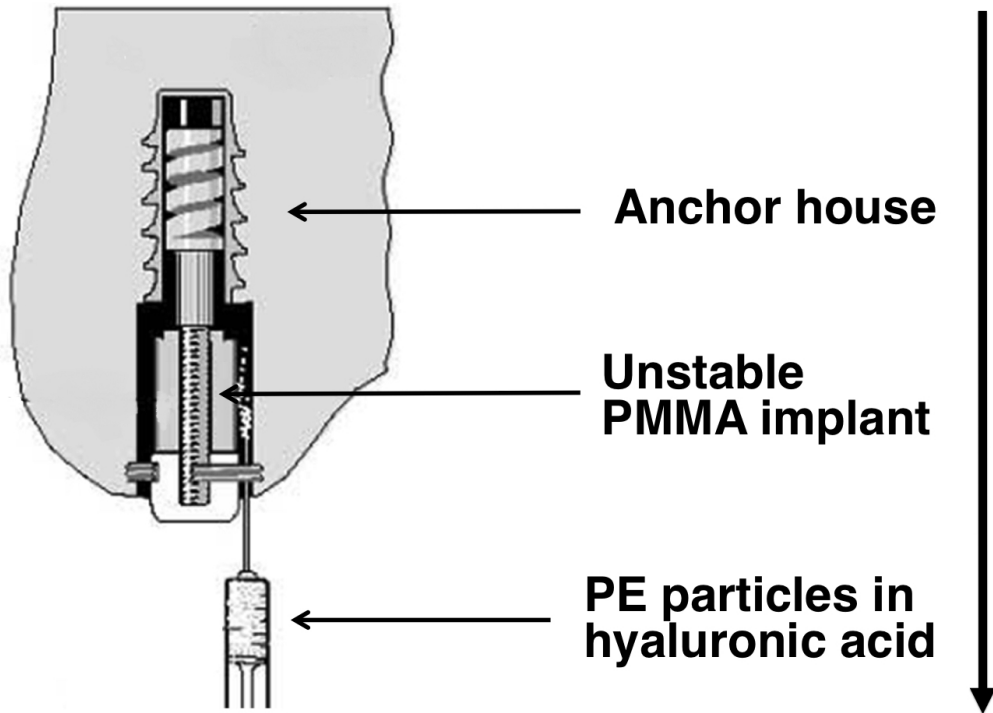
Primary arthroplasty is a successful treatment for osteoarthritis and excellent clinical outcomes have been reported.¹ Revised implants have a higher failure rate than primary implants,² and good initial fixation of implants is essential to reduce the risk of subsequent implant

failure.³ Revision surgery is often complicated by a deficient bone stock due to osteolysis, and the environment around a failed implant has a reduced healing capacity.^{4,5} Impacted bone graft is widely used to restore lost bone,⁶ as it provides initial mechanical support and functions as a lattice for new bone to form on before remodelling.

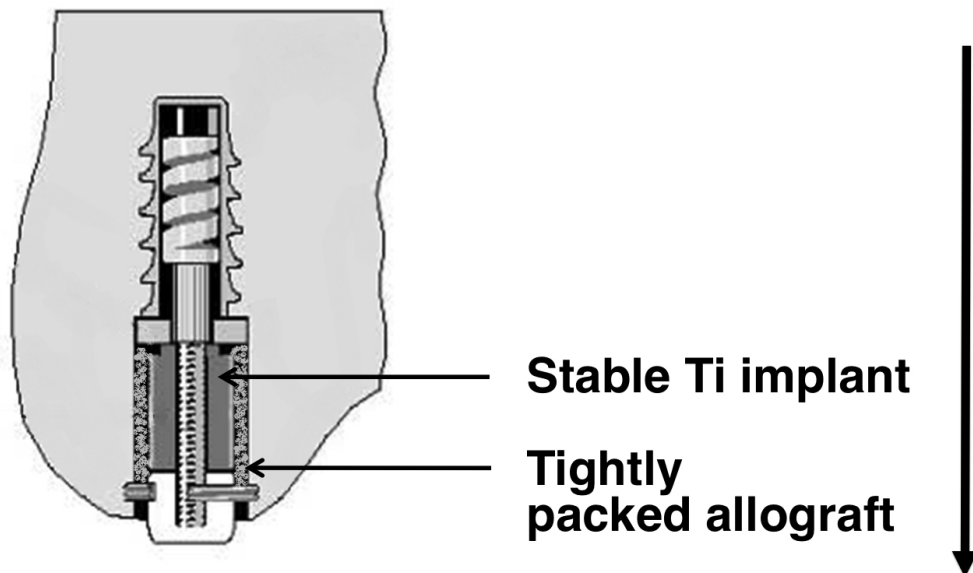
Bone morphogenetic protein 2 (BMP-2) is a bone anabolic protein that stimulates recruitment, proliferation, and differentiation of osteoprogenitor cells into bone-producing osteoblasts,⁷ and recombinant bone morphogenetic protein 2 (rhBMP-2) is Food and Drug Administration (FDA) approved for use in lumbar spinal fusion and open tibia fractures. BMP-2-induced allograft resorption and host bone resorption have been demonstrated and can potentially cause an early intermittent period of weakened implant fixation, pending new bone remodelling.^{8,9}

Previous studies investigating local nitrogen-containing bisphosphonates (N-bisphosphonates) as

PRIMARY SURGERY ————— t = 0 weeks



REVISION SURGERY ————— t = 8 weeks



Euthanasia ————— t = 12 weeks

Fig. 2

Illustration of revision protocols time sequence (right) and surgical procedures (left). At primary surgery (t = 0 weeks), a micromotion device, with a poly(methyl methacrylate) (PMMA) implant attached, was inserted into the medial condyle of each stifle joint with particulate polyethylene (PE) particles, representing a loose cement mantle and wear particles. At revision procedure (t = 8 weeks), the cavity was reamed and the PMMA implant replaced with a titanium (Ti) revision implant impacted with allograft. The animals were observed for an additional four weeks before euthanasia (t = 12 weeks).

Table II. Mechanical results.

Treatment	Strength, MPa	Energy, kJ/m ²	Stiffness, MPa/mm
LZ	10.5 (9.5 to 11.6)	1.5 (1.4 to 1.7)	55.3 (48.4 to 62.2)
LZ + rhBMP	10.3 (9.2 to 11.4)	1.5 (1.3 to 1.6)	54.6 (47.7 to 61.5)
SZ	8.6 (6.7 to 10.6)	1.2 (0.8 to 1.5)	45.9 (35.7 to 56.2)
SZ + rhBMP	8.2 (6.3 to 10.2)	1.1 (0.8 to 1.5)	42.7 (32.5 to 53.0)

Results are presented as mean (95% confidence interval) per treatment group.

LZ, local zoledronate; rhBMP-2, recombinant bone morphogenetic protein 2; SZ, systemic zoledronate.

Table III. The p-values for comparisons of mechanical parameters between treatment groups. A p-value ≤ 0.05 was considered statistically significant.

Group	Strength, MPa	Energy, kJ/m ²	Stiffness, MPa/mm
Paired			
SZ vs SZ + rhBMP	0.760	0.755	0.628
LZ vs LZ + rhBMP	0.643	0.651	0.852
Unpaired			
SZ vs LZ	0.106	0.097	0.149
LZ + rhBMP vs SZ + rhBMP	0.081	0.059	0.067

LZ, local zoledronate; rhBMP-2, recombinant bone morphogenetic protein 2; SZ, systemic zoledronate.

anti-catabolic means to decrease resorption of allograft demonstrated a reduction in allograft resorption both experimentally¹⁰ and clinically.¹¹

Combined bone anabolic and anti-catabolic therapy should in theory have a synergistic effect, and some experimental studies have confirmed this. In a piglet model of osteonecrosis of the hip, application of local ibandronate and rhBMP-2 preserved autograft and increased new bone formation.¹² However, in the context of primary impaction grafted implants, combined anabolic and local anti-catabolic therapies have proved less fruitful as rhBMP-2 with impacted allograft decreased implant fixation, primarily explained by accelerated allograft resorption and toxic effects of anti-catabolic compounds.^{13,14}

This motivated the present study; to investigate effects on initial implant osseointegration of local versus systemic administration of anti-catabolic treatment with or without rhBMP-2, in an animal model of impaction-grafted revision implants.

We hypothesized that osseointegration of implants would improve with rhBMP-2 in combination with local or systemic zoledronate compared to zoledronate alone. We defined this as increasing mechanical fixation and enhancing amount of new bone on the implant surface and in the peri-implant gap, and at the same time controlling bone allograft resorption.

Osseointegration was evaluated by mechanical testing to failure of the bone-implant interface (ultimate shear strength, apparent shear stiffness, and total energy absorption), and by histomorphometric evaluation of

tissues (allograft, new bone, bone marrow, fibrous tissue) on the implant surface and the immediate peri-implant gap.

Methods

Animals. Revision implant settings were studied in 24 skeletally mature male mongrel canines with a mean weight of 25.4 kg (20.6 kg to 29.8 kg) and a mean age of 14 months (13 to 15). Animals were bred for scientific purposes and two additional animals served as allograft donors. The study was approved by the Institutional Animal Care and Use Committee (IACUC) of Minneapolis Medical Research Foundation (MMRF).

Sample size. An a priori sample sized calculation was performed to allow for unpaired comparisons between systemic and local zoledronate administration, and for separate paired comparisons of systemic or local zoledronate with the addition of rhBMP-2. In the unpaired study, we wished to detect a relative minimal difference of $\geq 50\%$ on endpoints and assumed a coefficient of variation of 40% in the unpaired differences, an α of 0.05, and a β of 0.8. This resulted in a sample size of 22 animals in the unpaired study. To counter the loss of power in the advent of animal exclusions or implants lost during analysis, an additional two animals were included. Assuming a similar coefficient of variation in the paired differences, an α of 0.05, a β of 0.8, resulted in a sample size of 12 animals for each of the paired studies.

Treatment groups. Animals were randomly allocated into two groups ($n = 12$) for each paired study. One group received systemic zoledronate and the other local zoledronate. Each animal received one implant in each medial femoral condyle (Figure 1 and Table I), either rhBMP-2-coated or untreated. Treatment was assigned with random start and systematically altered between left and right femora.

Implants. The primary surgery used 48 poly(methyl methacrylate) (PMMA) implants and the revision surgery used 48 porous coated titanium-alloy (6Al-4V) implants (Figure 1). Implants were cylindrical and had nominal dimensions of 10 mm in length and 6 mm in diameter. Revision implants had a commercially available porous coating (Gription; DePuy Synthes, USA) with a reported mean volume porosity of 63% (standard deviation (SD) 3%).

Implant coating with rhBMP-2. Functionalization of the implant surface with rhBMP-2 was performed as described previously.^{8,15} rhBMP-2 (Infuse 12 mg; Medtronic, USA) was reconstituted with solutes and buffer included in the kit, to a concentration of 84 $\mu\text{g}/\text{ml}$. The coating retained a mean volume of 60 μl (SD 4) of fluid, depositing 5 μg of rhBMP-2 on the implant. In vitro release (rhBMP-2 Quantikine ELISA kit; R&D Systems, USA) confirmed presence and release of rhBMP-2 within the expected range (Supplementary Figure a).

Graft material. Bones from the proximal humeri, distal femora, and proximal tibiae from allograft donor animals were harvested under sterile conditions and debrided of

soft tissues followed by milling of metaphyses using the finest setting on a standard bone mill (The Mill Bone Mill System; Biomet, USA) producing morcellized allograft of 1 mm to 3 mm in chip size. Milled bone was mixed into a single batch, rinsed three times for one minute in 0.5 l of fresh saline, squeezed in gauze to remove excess saline, and manually compressed into 1.0 ml sterile vials with a mean 0.57 g (SD 0.02) of allograft and stored at -80°C .

Zoledronate administration. At revision surgery, thawed morcellized allograft was soaked in 5 ml of zoledronate solution (0.005 mg/ml, zoledronic acid; Actavis Group, Iceland) for three minutes and rinsed three times for one minute in fresh saline to remove unbound zoledronate before impaction.¹⁶ Systemic zoledronate (0.1 mg/kg) was administered intravenously (IV) ten and 20 days after revision surgery.

Surgery. We implemented our established revision protocol developed by Professors Søballe and Bechtold.^{4,5,17} The protocol consists of a two-stage procedure. The first stage imitates unstable conditions with relative implant movement. The second stage imitates post-revision conditions with a stable allograft impacted implant (Figure 2). The protocol consistently produces a tri-laminar revision cavity (sclerotic bone rim, dense fibrous tissue membrane, and a synovial-like membrane) similar to clinical implants with a loose cement mantle.^{4,10,18} All surgical procedures were performed on animals using general anaesthesia, observing sterile technique and infection prophylaxis (preoperatively cefazolin IV, 22 mg/kg, and cefuroxime SC, 50 mg/kg a day for nine days). Following a medial arthrotomy, a 2.1 mm Kirschner wire (K-wire) was inserted into the central portion of the medial condyles' weight-bearing surface. A cannulated step-drill created a 30 mm deep cavity at two rotations per second, consisting of a deep part (6 mm \times 10 mm) and an upper part (7.5 mm \times 20 mm), with the most superficial 3 mm tapped for a centralizer ring. The micromotion implant was inserted into the deep part of the cavity (Figure 2) and a PMMA implant mounted in line with the upper cavity. An estimated 5×10^7 particulate polyethylene (PE) suspended in synthetic hyaluronic acid (Lifecore Biomedical, USA) was injected around the PMMA implant. The PE mix was composed of 15% ultra-high molecular weight PE with a mean size of 30 μm (10 to 50) and 85% high-density PE with a mean size of 4.0 μm (0.4 to 11). A PE end-plug was threaded on the unstable rod tip ending just above the articular surface. Full PMMA implant displacement (500 μm) and free range of motion of the stifle joint was affirmed before tissue and skin were closed in layers with absorbable sutures. Eight weeks after the primary surgery, all animals underwent an implant revision procedure. Using the same medial arthrotomy, the PE plug, PMMA implant, and centralizer ring were removed. Visual inspection affirmed the presence of excess synovial fluid, synovitis, and a fibrous membrane in the superficial cavity in 48 out of a total of 48 revision cavities. An 8.2 mm reamer debrided the sclerotic bone rim in the superficial cavity to bleeding cancellous bone. The most superficial 3 mm

of the upper cavity (8.2 mm in diameter) was tapped for a larger titanium revision-centralizer ring. A titanium revision implant was threaded onto the implant piston, stabilizing the construct and preventing further axial motion. Allograft was impacted into the peri-implant gap. The PE end-plug was adjusted to a minimal protrusion to secure load transfer to the revision titanium implant during each gait cycle. Tissue and skin were closed in layers. An identical procedure was performed on the contralateral stifle with a rhBMP-2-coated implant. Postoperative analgesia was provided using 3 ml to 4 ml of 0.5% bupivacaine (Sagent Pharmaceuticals, USA) at the incision site and transdermal fentanyl (Recuvyra (Elanco, USA) 2.7 mg/kg). Four weeks after revision procedure, all animals were sedated with acepromazine intramuscular (IM) (0.1 mg/kg; Boehringer Ingelheim, USA) and propofol IV (4 mg/kg; Zoetis, USA) and euthanized with hypersaturated barbiturate IV (Socumb; Henry Schein Animal Health, USA).

Observation period. Animals were exercised two hours per day and allowed unlimited pen activity to ensure loading of the implants. Radiographs were obtained to confirm correct implant placement. Two animals sustained superficial wound ruptures after revision surgery and were treated with ten days of antibiotics and a collar. Wounds healed without sign of infection and all animals completed the observation period with no loss of specimens.

Specimen preparation. After euthanasia, distal femora with implants in situ were harvested and stored at -21°C . A bone cube with implant in situ was cut from the medial femur condyle using a water-cooled diamond band saw (Exakt Apparatebau, Germany) (Figure 3a). The outermost 1 mm of the implant-bone specimen closest to the subchondral bone was removed. The remaining implant-bone specimen was divided into two by a cut perpendicular to the axis of the implant. The outermost 3.5 mm was stored at -21°C for later mechanical testing. The innermost 5.5 mm was used for histomorphometric evaluation.

Histomorphometry. Specimens for histomorphometric evaluation were sequentially dehydrated in graded ethanol (70% to 96%) and 100% isopropyl alcohol (2-propanol; MilliporeSigma, Merck, Germany), defatted in xylene, and embedded in methyl methacrylate (MMA; Product no. 800590; Merck) in a cylindrical mould, thus securing alignment of the vertical axes of the mould and implant. The embedded specimen was rotated uniformly randomly along its vertical axis before four serial sections 400 μm apart (corresponding to the width of the saw blade) were cut from the central part of the implant using a hard-tissue microtome (KDG-95; MeProTech, The Netherlands) (Figure 3c). Specimens were stained using 0.1% toluidine blue (pH = 7; Sigma-Aldrich, USA), rinsed, and mounted on glass. The staining method enabled different tissues to be distinguished on the basis of morphological appearance. Using an optical light microscope (Olympus, Japan) and associated software (NewCast software, version 3.0.9.0; Visiopharm Integrator System,

Table IV. Histomorphometric results.

Treatment	Surface		Gap	
	New bone		New bone	Allograft
LZ	0.23 (0.18 to 0.28)		0.25 (0.21 to 0.29)	0.26 (0.20 to 0.31)
LZ + rhBMP-2	0.27 (0.22 to 0.32)		0.29 (0.25 to 0.33)	0.28 (0.23 to 0.33)
SZ	0.15 (0.10 to 0.20)		0.34 (0.30 to 0.38)	0.15 (0.10 to 0.21)
SZ + rhBMP-2	0.16 (0.11 to 0.21)		0.36 (0.32 to 0.40)	0.07 (0.02 to 0.12)

Results are presented as mean fraction (95% confidence interval) of surface area and volumes inside the peri-implant gap per treatment group. A p-value ≤ 0.05 was considered statistically significant.

LZ, local zoledronate; rhBMP-2, recombinant bone morphogenetic protein 2; SZ, systemic zoledronate.

Table V. The p-values for comparison for tissue area fractions on implant surface and volume fractions. A p-value ≤ 0.05 was considered statistically significant.

Group	Surface		Volume	
	New bone		New bone	Allograft
Paired				
SZ vs SZ + rhBMP	0.821		0.364	0.017
LZ vs LZ + rhBMP	0.247		0.192	0.468
Unpaired				
SZ vs LZ	0.030		0.003	0.007
LZ + rhBMP vs SZ + rhBMP	0.002		0.009	< 0.001

LZ, local zoledronate; rhBMP-2, recombinant bone morphogenetic protein 2; SZ, systemic zoledronate.

Denmark), quantitative histomorphometric evaluation was performed by a reviewer blinded to treatment, with specimens in random order. Surface area-fraction of new bone, allograft, marrow, and fibrous tissue were estimated by line intersection technique¹⁹ using a probe intensity of 15 lines. Volume fraction of new bone, allograft, marrow, and fibrous tissue were estimated by point counting technique²⁰ using a probe intensity of 5×4 points. Histomorphometry was performed at $\times 10$ magnification using meander sampling (100% fraction).

Mechanical testing. Thawed specimens were tested in random order by an examiner blinded to treatment (RC). Specimens were placed on a jig with a central 7.4 mm hole, securing 0.7 mm of clearance between the implant and the hole edge.²¹ Implants were tested until failure of the bone implant interface by applying a continuous force axially onto the implant with a cylindrical metal test probe connected to a servohydraulic test rig (MTS 858 Mini Bionics Test Machine; MTS Systems, USA). A preload of 2 N was applied as standard contact condition. Force was applied at a constant displacement rate of 5 mm/minute, recording displacement (mm) and load (N) for every 10 μm to produce a load/displacement curve (Figure 3b).

Statistical analysis. Statistical data analysis was carried out in StataCorp. 2013 (version IC 13.1; StataCorp, USA). Effects of treatment on mechanical and histomorphometric endpoints were estimated using a mixed model adjusting for implant position, age, and weight of the animal, and thus taking variations between animals and between sides into account. The probability of type I error was not adjusted for multiple comparisons. Mean estimates and differences are presented with 95% confidence intervals.

In all studies, two-tailed p-values below 0.05 for overall and pairwise comparisons were considered statistically significant. Correlation between histomorphometric and mechanical results were tested using Spearman's rank correlation coefficient (Rho) with corresponding p-value; a p-value below 0.05 was considered statistically significant.

Results

Mechanical parameters with local zoledronate were all higher compared to systemic zoledronate in both paired and unpaired studies. However, no significant differences were detected on any mechanical parameter between groups (Tables II and III).

In the unpaired studies, local zoledronate had a statistically significant 53% larger implant surface area covered with new bone compared to systemic zoledronate alone ($p = 0.030$) (Tables IV and V).

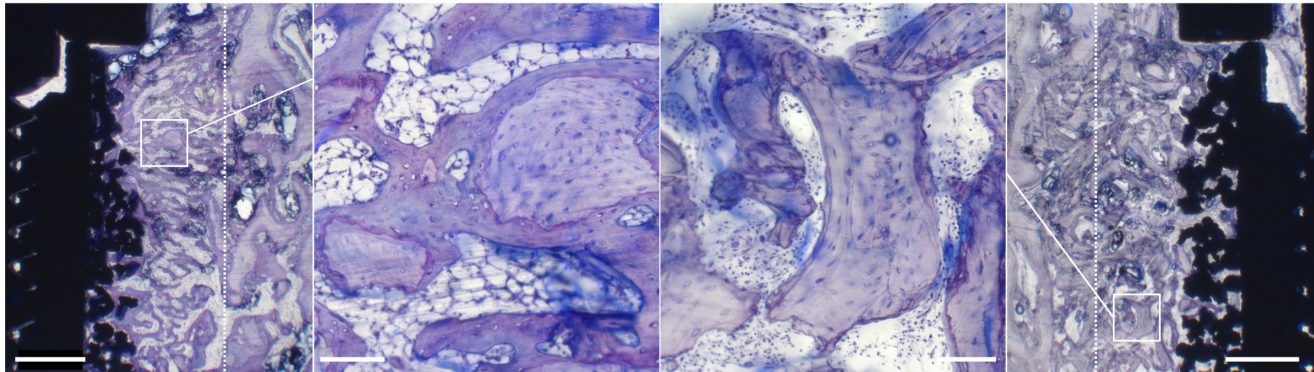
In the peri-implant gap, systemic zoledronate had a 34% higher volume of new bone and 39% lower volume of allograft compared to local zoledronate, which was statistically significant ($p = 0.003$) (Table IV).

In the paired studies, the addition of rhBMP-2 to either local or systemic zoledronate increased both surface area and volume of new bone, but results were not statistically significant (local zoledronate: $p = 0.247$; systemic zoledronate: $p = 0.821$). In contrast, addition of rhBMP-2 to systemic zoledronate statistically significantly decreased volume of allograft in the peri-implant gap by 53% ($p = 0.017$). Interestingly, no negative effect on volume of allograft was seen when rhBMP-2 was combined with local zoledronate (Table IV).

Table VI. Correlation of biomechanical and histomorphometric results (Spearman's rank correlation coefficient).

Parameter	Surface				Volume			
	New bone		Allograft		New bone		Allograft	
	Spearman	p-value	Spearman	p-value	Spearman	p-value	Spearman	p-value
Strength, MPa	0.43	0.003	0.39	0.006	0.19	0.197	0.41	0.004
Energy, kJ	0.37	0.009	0.22	0.140	0.15	0.325	0.29	0.045
Stiffness, MPa/mm	0.42	0.003	0.39	0.006	0.14	0.327	0.46	0.001

Mechanical fixation parameters are maximum shear strength ("Strength"), total energy absorption ("Energy"), and apparent shear stiffness ("Stiffness"). Surface parameters are surface area fraction of new bone and allograft, and peri-implant gap volume fraction of new bone and allograft.

**Fig. 3**

Representative histological sections of the zoledronate-treated groups (toluidine blue). Systemic zoledronate (SZ) group (far left; $\times 1.25$) and local zoledronate (LZ) group (far right; $\times 1.25$). Solid white frames in SZ ($\times 1.25$) and LZ ($\times 1.25$) mark the positions of the two central images ($\times 10$). Bar ($\times 1.25/\times 10$) = 1.0/0.1 mm. Sections are cut longitudinally to the long axis of the implant. Dotted line marks original drill-border. Allograft appears as a lightly stained lamellar structure with empty fusiform lacunae. Lamellar bone appears as allograft having fusiform lacunae with cells. New bone presents as a disorganized, dark-stained structure having round lacunae with cells. SZ ($\times 1.25$): extensive remodelling has occurred, with a few small pieces of allograft in the peri-implant gap being covered with new bone, which exhibits high interconnectivity in the peri-implant gap and into the porous surface coating. SZ ($\times 10$): allograft with a thick layer of new bone and few resorption lacunae. The surface of the remaining allograft is covered with resorption lacunae, giving it a serrated appearance. LZ ($\times 1.25$): large pieces of allograft with thin layers of new bone displaying low interconnectivity in the peri-implant gap and into the porous implant surface. LZ ($\times 10$): allograft with ragged and intact edges, non-circumferential new bone coverage, and extensive number of resorption lacunae.

Correlation analysis (Spearman's Rho) of histomorphometric variables and mechanical results had a medium but statistically significant correlation except for surface allograft and energy to failure and volume of new bone for all mechanical parameters ($p = 0.140$) (Table VI).

Discussion

The aim of the study was to improve revision implant fixation by balancing increased bone remodelling induced by rhBMP-2 with local or systemic anti-catabolic bisphosphonate treatment. We hypothesized that this approach would increase mechanical fixation of impaction grafted orthopaedic revision implants by increasing bone formation without excessive bone resorption.

All animals received anti-catabolic treatment, either locally as zoledronate soaked allograft or as zoledronate IV. Titanium implants, functionalized with rhBMP-2 or left untreated, were inserted into the revision cavity and the peri-implant gap impacted with allograft.

An almost inverse composition of the peri-implant gap was seen, depending on administration route of zoledronate (local vs systemic). Allograft was protected

and retained in higher amount with local zoledronate, whereas new bone formation was significantly higher with systemic zoledronate. Although mechanical failure occurred at lower forces with systemic zoledronate compared to local zoledronate, the addition of rhBMP-2 did not improve formation of new bone or mechanical fixation irrespective of zoledronate route.

It can be considered a limitation of the study that a control group (without zoledronate) was not applied. Previous studies with rhBMP-2 allograft augmented implants uniformly demonstrated extensive allograft resorption if an anti-catabolic was omitted.^{8,13,14} Given the predictable results with rhBMP-2 from historical controls with our standardized model, we did not feel it was justified to replicate those groups here. This necessarily confines our results with rhBMP-2 to be interpreted only in the context of local or systemic zoledronate, with knowledge of historical controls.

As initial implant fixation is imperative for long-term implant survival, we designed the study to address effects on early-phase implant fixation. A four-week observation period represents this early important implant fixation, but interpretation is limited to this time frame.

The experimental revision cavity consists of a cylindrical defect and the revision implants are cyclically loaded, intra-articular, subjected to oscillating fluid pressure, and have a commercially available coating. However, this controlled experimental revision setting does not include the clinical array of manifestations in failed arthroplasties. The limitations of this lack of morphological and functional resemblance to clinical implants are balanced by the model's high levels of control and reproducibility with low variation.

It is a potential limitation that mechanical tests are performed systematically in a different region than histological evaluation, as bone ingrowth and loading in these two regions could be different. Both mechanical and histomorphometric sample evaluation is by nature destructive and only permits for a single endpoint to be evaluated. As we search for directions of applied interventions to guide future research, a difference could exist between mechanical and histomorphometric sampling sites, but as both mechanical and histological parameters are evaluated as separate relative differences, this would not affect the results. The assumption that treatment effects to a great extent are similar in intimately neighbouring bone is supported by a medium but significant correlation between mechanical and histomorphometric results, with the exception of surface allograft and energy to failure ($p = 0.140$) (Table VI).

Bisphosphonates are viewed as capable of enhancing the intrinsic anabolic potential of bone,²² and our intention to protect newly formed bone was reached with systemic zoledronate, despite low values of retained allograft, normally viewed as a lattice for new bone formation.²³ No significant anabolic effect of rhBMP-2 irrespective of zoledronate administration route was seen. Higher volumes of new bone are thus likely attributable to effects of zoledronate administration route.

Local zoledronate secured presence of the compound in the revision cavity, where it remains highly localized with a minimal systemic spillover.²⁴ No direct proof of zoledronate reaching the peri-implant gap is provided with systemic administration. However, bisphosphonates accumulate in physes of appendicular bone and areas with increased metabolism.^{24,25}

The larger surface area of new bone with local zoledronate compared to systemic zoledronate may stem from a peripheral effect by zoledronate eluting from allograft, as seen with bisphosphonate-augmented implants.²² With systemic zoledronate, bone mineralization may not have been extensive enough at zoledronate administration points, or zoledronate, a high affinity bisphosphonate, was bound peripherally in the grafted gap leaving the surface unprotected.²⁶

Our results with local zoledronate and allograft mirror previous studies, indicating a protective effect on allograft.^{10,11,16} Whereas a previous study with systemic bisphosphonate indicates a protective effect on both new bone and allograft,²³ our results only demonstrate an effect on new bone.

Some protective effect on allograft with systemic zoledronate cannot be ruled out. Volumes and surface areas of new bone and allograft with local zoledronate in the present study are similar to values recently reported in an identical experimental revision implant setting by Sørensen et al.¹⁰ However, allograft volumes are noticeably higher with systemic zoledronate than naïve controls in the Sørensen et al study.¹⁰

The higher volume of new bone with naïve allograft in the systemic zoledronate group may be attributed to endothelial cells and osteoblasts not being directly exposed to zoledronate. Osteoclasts are perceived as the only cell able to internalize N-bisphosphonates in amounts sufficient to induce apoptosis to interfere with farnesyl pyrophosphate synthase (FPPS), an enzyme path ubiquitous in all cell lines.²² However, angiogenesis and osteoblasts have in vitro been inhibited in a non-FPPS dependent manner by bone-bound N-bisphosphonates.^{27,28} While systemic zoledronate seemingly has the advantage of lower toxicity, the poor protection of allograft observed here allowed osteoclast-mediated resorption. Release of embedded osteoinductive growth factors,¹³ followed by peripheral zoledronate retention,²⁶ could explain the higher volumes of new bone with systemic zoledronate.

Previously investigated rhBMP-2 and N-bisphosphonate dosages and delivery are highly variable.^{8,12-15,18} We recently demonstrated that allograft resorption and anabolic response is rhBMP-2 dose-dependent, and these results guided the choice of rhBMP-2 concentration, to optimize its effect.^{8,15} While the rhBMP-2 dose was insufficient to initiate a significant anabolic response regardless of zoledronate administration, the dose was sufficient to shift the peri-implant milieu in a catabolic direction with systemic zoledronate.

Successful osseous integration of an implant is essential for its secure anchorage. The correlation analysis indicates that both allograft and new bone are prerequisites for good early implant fixation (Table V). The different composition of the peri-implant likely resulted from bone growth or resorption being targeted at different maturity levels.

In conclusion, by use of two administration routes of zoledronate, we were able to target bone around impaction grafted revision implants that were at different maturity levels. Local zoledronate retained allograft, while systemic zoledronate accrued new bone. Application and dose of rhBMP-2 was not sufficient to trigger a significant anabolic response, but sufficiently ample to move the peri-implant milieu towards bone resorption when initial anti-catabolic control was missing with systemic zoledronate. The results underline that both zoledronate and rhBMP-2 are potent bone metabolic compounds when used to augment revision implant fixation. A potential additive effect was suggested with a dual anti-catabolic therapy approach combining local and systemic zoledronate. Further experimental studies are warranted before any translation into a human setting should be considered.

Supplementary material



Figure showing mean recombinant bone morphogenetic protein 2 (rhBMP-2) release from two rhBMP-2 coated implants, and an ARRIVE checklist to show that the ARRIVE guidelines were adhered to in this study.

References

- Pivec R, Johnson AJ, Mears SC, Mont MA. Hip arthroplasty. *Lancet*. 2012;380(9855):1768–1777.
- Ong KL, Lau E, Suggs J, Kurtz SM, Manley MT. Risk of subsequent revision after primary and revision total joint arthroplasty. *Clin Orthop Relat Res*. 2010;468(11):3070–3076.
- Klerken T, Mohaddes M, Nemes S, Kärrholm J. High early migration of the revised acetabular component is a predictor of late cup loosening: 312 cup revisions followed with radiostereometric analysis for 2–20 years. *Hip Int*. 2015;25(5):471–476.
- Bechtold JE, Kubic V, Søballe K. A controlled experimental model of revision implants: Part I. development. *Acta Orthop Scand*. 2001;72(6):642–649.
- Bechtold JE, Mouzin O, Kidder L, Søballe K. A controlled experimental model of revision implants: Part II. Implementation with loaded titanium implants and bone graft. *Acta Orthop Scand*. 2001;72(6):650–656.
- Ricciardi BF, Bostrom MP. Bone graft substitutes: claims and credibility. *Semin Arthroplasty*. 2013;24(2):119–123.
- Wang RN, Green J, Wang Z, et al. Bone Morphogenetic Protein (BMP) signaling in development and human diseases. *Genes Dis*. 2014;1(1):87–105.
- Cleemann R, Bechtold JE, Sorensen M, Soballe K, Baas J. Dose-Dependent Resorption of Allograft by rhBMP-2 Uncompensated by New Bone Formation-A Canine Study With Implants and Zoledronate. *J Arthroplasty*. 2018;33(4):1215–1221.
- Toth JM, Boden SD, Burkus JK, Badura JM, Peckham SM, McKay WF. Short-term osteoclastic activity induced by locally high concentrations of recombinant human bone morphogenetic protein-2 in a cancellous bone environment. *Spine (Phila Pa 1976)*. 2009;34(6):539–550.
- Sorensen M, Barckman J, Bechtold JE, Søballe K, Baas J. Preclinical evaluation of zoledronate to maintain bone allograft and improve implant fixation in revision joint replacement. *J Bone Joint Surg Am*. 2013;95-A(20):1862–1868.
- Kesteris U, Aspenberg P. Rinsing morcellised bone grafts with bisphosphonate solution prevents their resorption. A prospective randomised double-blinded study. *J Bone Joint Surg Br*. 2006;88-B(8):993–996.
- Vandermeer JS, Kamiya N, Aya-ay J, Garces A, Browne R, Kim HKW. Local administration of ibandronate and bone morphogenetic protein-2 after ischemic osteonecrosis of the immature femoral head: a combined therapy that stimulates bone formation and decreases femoral head deformity. *J Bone Joint Surg Am*. 2011;93-A(10):905–913.
- Baas J, Elmengaard B, Jensen TB, Jakobsen T, Andersen NT, Soballe K. The effect of pretreating morselized allograft bone with rhBMP-2 and/or pamidronate on the fixation of porous Ti and HA-coated implants. *Biomaterials*. 2008;29(19):2915–2922.
- Baas J, Vestermark M, Jensen T, Bechtold J, Soballe K, Jakobsen T. Topical bisphosphonate augments fixation of bone-grafted hydroxyapatite coated implants, BMP-2 causes resorption-based decrease in bone. *Bone*. 2017;97:76–82.
- Cleemann R, Sorensen M, Bechtold JE, Soballe K, Baas J. Healing in peri-implant gap with BMP-2 and systemic bisphosphonate is dependent on BMP-2 dose-A canine study. *J Orthop Res*. 2018;36(5):1406–1414.
- Jakobsen T, Baas J, Bechtold JE, Elmengaard B, Søballe K. The effect of soaking allograft in bisphosphonate: a pilot dose-response study. *Clin Orthop Relat Res*. 2010;468(3):867–874.
- Søballe K, Hansen ES, B-Rasmussen H, Jørgensen PH, Bünger C. Tissue ingrowth into titanium and hydroxyapatite-coated implants during stable and unstable mechanical conditions. *J Orthop Res*. 1992;10(2):285–299.
- Søballe K, Jensen TB, Mouzin O, Kidder L, Bechtold JE. Differential effect of a bone morphogenetic protein-7 (OP-1) on primary and revision loaded, stable implants with allograft. *J Biomed Mater Res A*. 2004;71(4):569–576.
- Baddeley AJ, Gundersen HJ, Cruz-Orive LM. Estimation of surface area from vertical sections. *J Microsc*. 1986;142(Pt 3):259–276.
- Gundersen HJ, Bendtsen TF, Korbo L, et al. Some new, simple and efficient stereological methods and their use in pathological research and diagnosis. *APMIS*. 1988;96(5):379–394.
- Dhert WJ, Verheyen CC, Braak LH, et al. A finite element analysis of the push-out test: influence of test conditions. *J Biomed Mater Res*. 1992;26(1):119–130.
- Qayoom I, Raina DB, Širka A, et al. Anabolic and antiresorptive actions of locally delivered bisphosphonates for bone repair: a review. *Bone Joint Res*. 2018;7(10):548–560.
- Astrand J, Harding AK, Aspenberg P, Tägil M. Systemic zoledronate treatment both prevents resorption of allograft bone and increases the retention of new formed bone during revascularization and remodelling. A bone chamber study in rats. *BMC Musculoskelet Disord*. 2006;7:63.
- McKenzie K, Dennis Bobyn J, Roberts J, Karabasz D, Tanzer M. Bisphosphonate remains highly localized after elution from porous implants. *Clin Orthop Relat Res*. 2011;469(2):514–522.
- Wen D, Qing L, Harrison G, Golub E, Akintoye SO. Anatomic site variability in rat skeletal uptake and desorption of fluorescently labeled bisphosphonate. *Oral Dis*. 2011;17(4):427–432.
- Turek J, Ebetino FH, Lundy MW, et al. Bisphosphonate binding affinity affects drug distribution in both intracortical and trabecular bone of rabbits. *Calcif Tissue Int*. 2012;90(3):202–210.
- Idris AI, Rojas J, Greig IR, Van't Hof RJ, Ralston SH. Aminobisphosphonates cause osteoblast apoptosis and inhibit bone nodule formation in vitro. *Calcif Tissue Int*. 2008;82(3):191–201.
- Stresing V, Fournier PG, Bellahcène A, et al. Nitrogen-containing bisphosphonates can inhibit angiogenesis in vivo without the involvement of farnesyl pyrophosphate synthase. *Bone*. 2011;48(2):259–266.

Author information:

- R. Cleemann, MD PhD, Consultant Orthopedics, Orthopedics, Zealand University Hospital Koge, Køge, Denmark; Orthopedic Research Laboratory, Aarhus University Hospital, Aarhus, Denmark; Orthopedics, Elective Surgery Center - Silkeborg Regional Hospital, Silkeborg, Denmark.
- M. Sorensen, MD PhD, Consultant Orthopedics, Orthopedic Research Laboratory, Aarhus University Hospital, Aarhus, Denmark; Orthopedics, Aalborg University Hospital, Aalborg, Denmark.
- A. West, MD, Speciality Registrar Orthopedics, Orthopedics, Regionshospitalet Horsens, Horsens, Denmark.
- K. Soballe, MD DMSc, Professor, Senior Consultant Orthopedics
- J. Baas, MD PhD, Consultant Orthopedics Orthopedic Research Laboratory, Aarhus University Hospital, Aarhus, Denmark; Orthopedics, Aarhus University Hospital Skejby, Aarhus, Denmark.
- J. E. Bechtold, BS, MS, PhD, Professor, Department of Orthopedic Surgery, Hennepin Healthcare Research Institute, Minneapolis Medical Research Foundation, Orthopedic Biomechanics Laboratory, University of Minnesota, Minneapolis, Minnesota, USA.

Author contributions:

- R. Cleemann: Conceptualization; Project administration; Investigation; Formal Analysis; Writing – original draft;
- M. Sorensen: Supervision; Investigation; Writing – review & editing
- A. West: Investigation; Writing – review & editing
- K. Soballe: Conceptualization; Supervision; Resources; Funding acquisition; Writing – review & editing
- J. E. Bechtold: Conceptualization; Supervision; Investigation; Funding acquisition; Resources; Writing – review & editing
- J. Baas: Conceptualization; Supervision; Investigation; Writing – review & editing

Funding statement:

- The following donors funded this study: Orthopaedic Research Foundation-Aarhus University Hospital, Elective Surgery Center-Silkeborg Regional Hospital, NIH Grant AR-042051, The Danish Rheumatism Association, Direktør Jacob Madsens og Hustru Olga Madsens Fond, AP Møllers Fond til Lægevidenskabens fremme, Aarhus Universitetes Rejselegat, Direktør Emil C. Hertz og Hustru Inger Hertz Fond, Knud og Edith Eriksens Minde Fond, Linux Fonden, Oticon Fonden, Torben og Alice Frimodts Fond, Aase og Ejnar Danielsens Fond, Brorsons Rejselegat, Dansk Ortopædkirurgisk Selskab and Kong Christian d. X's Fond. The authors have chosen not to provide a funding statement for this manuscript.

ICMJE COI statement:

- The authors report donation of the porous implant coating from DePuy Synthes, and donation of recombinant bone morphogenetic protein 2 (rhBMP-2) and solutes used from Medtronic, all related to this study.
- R. Cleemann reports an institutional research grant (paid to Orthopedic Research Laboratory, Aarhus University Hospital) from the Danish Orthopedic Society (DOS), related to this study. This grant was used to support a podium presentation at Orthopaedic Research Society (ORS) 2017 Annual Meeting in San Diego, California, USA.
- J. E. Bechtold reports an institutional research grant (paid to University of Minnesota) from the National Institutes of Health, related to this study.

Acknowledgements:

- Acknowledgements and gratitude are given to Veterinary Technician Toni Meglitsch for help with surgeries at Minneapolis Medical Research Foundation (MMRF), Laboratory Technician Jane Pauli for histomorphometric evaluation and specimen prepara-

ration, Laboratory Technician Anna Bay Nielsen for aid and advice on recombinant bone morphogenetic protein 2 (rhBMP-2) release and Laboratory Technician Annette Battrup, all at Orthopaedic Reserch Laboratory, Aarhus University Hospital. Thank you all for your help, encouragement, advice, and keeping up spirits.

Ethical review statement:

- The study was approved by the Institutional Animal Care and Use Committee (IACUC) of Minneapolis Medical Research Foundation (MMRF).

Open access funding:

- The authors report that they received open access funding for their manuscript from Aase og Ejnar Danielsens Fond.

© 2021 Author(s) et al. This is an open-access article distributed under the terms of the Creative Commons Attribution Non-Commercial No Derivatives (CC BY-NC-ND 4.0) licence, which permits the copying and redistribution of the work only, and provided the original author and source are credited. See <https://creativecommons.org/licenses/by-nc-nd/4.0/>.