



Aalborg Universitet

AALBORG UNIVERSITY  
DENMARK

## Patient assessment of cosmetic outcome after craniotomy for intracranial tumor surgery

Uggerly, Amalie Sofie Vagner; Møller, Morten Winkler; Eriksen, Elin; Bjarkam, Carsten Reidies; Poulsen, Frantz Rom

*Published in:*  
Interdisciplinary neurosurgery

*DOI (link to publication from Publisher):*  
[10.1016/j.inat.2023.101752](https://doi.org/10.1016/j.inat.2023.101752)

*Creative Commons License*  
CC BY-NC-ND 4.0

*Publication date:*  
2023

*Document Version*  
Publisher's PDF, also known as Version of record

[Link to publication from Aalborg University](#)

*Citation for published version (APA):*

Uggerly, A. S. V., Møller, M. W., Eriksen, E., Bjarkam, C. R., & Poulsen, F. R. (2023). Patient assessment of cosmetic outcome after craniotomy for intracranial tumor surgery. *Interdisciplinary neurosurgery*, 32, Article 101752. Advance online publication. <https://doi.org/10.1016/j.inat.2023.101752>

### General rights

Copyright and moral rights for the publications made accessible in the public portal are retained by the authors and/or other copyright owners and it is a condition of accessing publications that users recognise and abide by the legal requirements associated with these rights.


- Users may download and print one copy of any publication from the public portal for the purpose of private study or research.
- You may not further distribute the material or use it for any profit-making activity or commercial gain
- You may freely distribute the URL identifying the publication in the public portal -

### Take down policy

If you believe that this document breaches copyright please contact us at [vbn@aub.aau.dk](mailto:vbn@aub.aau.dk) providing details, and we will remove access to the work immediately and investigate your claim.

Contents lists available at [ScienceDirect](https://www.sciencedirect.com)

# Interdisciplinary Neurosurgery: Advanced Techniques and Case Management

journal homepage: [www.elsevier.com/locate/inat](http://www.elsevier.com/locate/inat)

Research Article

## Patient assessment of cosmetic outcome after craniotomy for intracranial tumor surgery

Amalie Sofie Vagner Uggerly<sup>a,b,\*</sup>, Morten Winkler Møller<sup>a,b</sup>, Elin Eriksen<sup>c</sup>,  
Carsten Reidies Bjarkam<sup>c</sup>, Frantz Rom Poulsen<sup>a,b</sup>

<sup>a</sup> Department of Neurosurgery, Odense University Hospital, Klovevænget 47, 1st Floor, Denmark

<sup>b</sup> Department of Clinical Research and BRIDGE—Brain Research – Inter Disciplinary Guided Excellence, University of Southern Denmark, DK-5000 Odense C, Denmark

<sup>c</sup> Department of Neurosurgery, Department of Clinical Medicine, Aalborg University Hospital, Hobrovej 18-22, DK-9000 Aalborg, Denmark



### ARTICLE INFO

#### Keywords:

Craniotomy  
Brain neoplasm  
Neurosurgical procedures  
Cosmetic outcome  
Questionnaire

### ABSTRACT

**Background:** Intracranial tumors are commonly approached through a craniotomy, and the bone flap is later reattached with plates and screws. The gap created around the bone flap may cause the skin to submerge, potentially influencing the facial and head aesthetic appearance. The aim of this study was to examine patient satisfaction with cosmetic outcome after craniotomy for intracranial tumor resection.

**Methods:** In a prospective questionnaire-based study, patients were asked to report their degree of satisfaction with the scar and overall cosmetic appearance, and the extent of change to their facial appearance using 0–10 rating scales. The questionnaire was sent six months after surgery to patients undergoing first-time craniotomy for tumor resection at either of two neurosurgical departments.

**Results:** Of the 70 patients included in the study, 49 (70%) completed the questionnaire. Median scores were 9.3 for satisfaction with the scar and 9.0 for overall cosmetic satisfaction (a score of 10 reflected highest satisfaction). The median score was 1.7 for degree of change in facial appearance (a score of 0 reflected no change). However, 24.5% of patients reported major alterations to facial appearance. Satisfaction levels were similar by age, sex, and tumor type, but patients with occipital craniotomies were less satisfied with the overall cosmetic result than those with temporal craniotomies.

**Conclusion:** Most patients were satisfied with the cosmetic outcome of the craniotomy, but a considerable proportion reported major facial alterations. While the level of overall cosmetic satisfaction did not differ according to age, sex, or tumor type, the location of the craniotomy seemed to be a factor in satisfaction with the aesthetic outcome. Further studies are needed to investigate how the cosmetic result from craniotomy could be improved from the patient's perspective.

### 1. Introduction

The treatment of diagnosed central nervous system (CNS) tumors is complex, with a multimodal approach that often starts with surgical intervention followed by chemotherapy, radiotherapy, targeted therapy, immunotherapy, or a combination of these [1].

The most common procedure for intracranial tumor resection is a craniotomy, and this is usually repaired by reattaching the bone flap to the cranium using plates, screws, or similar. The surgery can lead to aesthetic damage due to cutaneous scarring, depression of the skin,

irregularity of the skin above the craniotomy, or subcutaneous breaks due to the materials lying underneath [2]. Patient satisfaction with the aesthetic outcome after craniotomy has only been sparsely investigated [2–4], however, making it difficult for the surgeon to optimize this part of the surgical procedure.

The objectives of this study were to investigate patients' level of satisfaction with the aesthetic outcome six months after craniotomy for intracranial tumor and to look for any differences by age, sex, tumor type, and surgical approach. We custom-designed a questionnaire asking patients to rate their satisfaction with the scar, the overall cosmetic

**Abbreviations:** OUH, Odense University Hospital; AaUH, Aalborg University Hospital; IQR, Intra quartile range.

\* Corresponding author at: Oestre Stationsvej 37L, st. 5, DK-5000 Odense C, Denmark.

**E-mail addresses:** [amugg17@student.sdu.dk](mailto:amugg17@student.sdu.dk) (A.S.V. Uggerly), [morten.winkler.moeller3@rsyd.dk](mailto:morten.winkler.moeller3@rsyd.dk) (M.W. Møller), [ele@rn.dk](mailto:ele@rn.dk) (E. Eriksen), [c.bjarkam@rn.dk](mailto:c.bjarkam@rn.dk) (C.R. Bjarkam), [frantz.r.poulsen@rsyd.dk](mailto:frantz.r.poulsen@rsyd.dk) (F.R. Poulsen).

<https://doi.org/10.1016/j.inat.2023.101752>

Received 23 January 2023; Received in revised form 24 February 2023; Accepted 26 February 2023

Available online 1 March 2023

2214-7519/© 2023 The Author(s). Published by Elsevier B.V. This is an open access article under the CC BY-NC-ND license (<http://creativecommons.org/licenses/by-nc-nd/4.0/>).

outcome, and the extent of change to their facial appearance.

## 2. Material and methods

### 2.1. Study design

We conducted a prospective questionnaire-based study in which 70 patients were enrolled from the neurosurgical department at either Odense University Hospital (OUH) or Aalborg University Hospital (AaUH) between October 1st, 2020, and August 31st, 2021. Inclusion criteria were informed consent from patients aged 18 years or above who were scheduled for first-time craniotomy for an intracranial tumor. The surgical procedure was similar at the two neurosurgical departments, with plates and screws used to mount the cranial flap alongside resorbable subcutaneous sutures and non-resorbable nylon skin sutures. The non-resorbable nylon skin sutures were removed eight to ten days after surgery. Cranial cement or similar was not used in either department.

Patients were invited to participate in the study during their pre-surgical outpatient clinic consultation (OUH) or during hospitalization immediately after surgery (AaUH). The study was approved by the relevant data protection authorities (Region of Southern Denmark ID: 20/33798 and Region of Northern Denmark ID: 2020–178).

### 2.2. Data collection

The study data were collected through a custom-made patient questionnaire.

As primary outcomes, three questions were designed: 1) By marking on the scale from 0 to 10, rate your satisfaction with the appearance of your surgical scar, 2) By marking on the scale from 0 to 10, rate your satisfaction with the overall cosmetic appearance of your cranium after surgery, and 3) By marking on the scale from 0 to 10, show what extent you think your facial appearance has changed after surgery (0 is no change). On the first two questions, an answer above 7.5 was defined as a very satisfactory result and below 2.5 indicated a very unsatisfactory result. On the third question, an answer below 2.5 indicated no or minor alterations, and above 7.5 suggested major alterations.

Additionally, patients were asked if they had experienced complications from the surgery. They also had an opportunity to write freely if they had other remarks regarding the surgery.

The questionnaire was sent out six months after surgery—either electronically via RedCap through a national secure mailing system or by standard mail if the patient did not have access to the secure mail system.

In case of no response to the initial questionnaire, a reminder was sent after two weeks and a further reminder after four weeks. Data on age, sex, tumor histology, and the surgical site were collected from the patient's medical record. All data were gathered in a secure REDCap database [5].

### 2.3. Data analysis

The results for the primary outcomes were compared between the subgroups using Kruskal-Wallis one-way analysis (age, tumor type, and surgical approach) or Wilcoxon rank sum test (sex), followed by linear regression to compare each group of tumor and surgical access with the other groups. A post hoc Wilcoxon rank sum test was used to compare patients reporting major facial alterations with those reporting no or minor facial alterations. P-values < 0.05 were considered statistically significant. Data were analyzed with STATA (version 17.0).

## 3. Results

### 3.1. Study patients

A total of 70 patients were included in the study, 57 from OUH and 13 from AaUH. One patient withdrew consent, and one was excluded after histology revealed necrosis due to radiotherapy and no tumor tissue, leaving a study population of 68 (31 male and 37 female). Nineteen patients did not reply to the questionnaire (9 died before follow-up, and 10 were lost to follow-up), leaving data from 49 patients for analysis.

The median age was 66 years (range 23 to 82). The cohort was subcategorized into six tumor subgroups: meningioma, high or low grade astrocytoma, metastasis, oligodendroglioma, and other tumors (one neurocytoma, one subependymoma, and one epidermoid cyst) (Fig. 1). Craniotomy location was divided into six categories as shown in Fig. 2. The temporal category included both temporal and pterion access, and the occipital category included all posterior fossa craniotomies and occipitoparietal craniotomies.

### 3.2. Satisfaction with the scar

Of the 49 patients who responded to this question, 21 (42.9%) reported their satisfaction with the scar to be 10 out of 10, and a total of 40 patients (81.6%) reported a very satisfactory result (above 7.5) (Table 1). No patients reported a very unsatisfactory result (below 2.5). The median score was 9.3, with an interquartile range (IQR) of 8.0–10. No statistically significant difference was found between age groups ( $P = 0.359$ ) although there was a tendency for a less satisfactory result among patients under 40 years old. There was no statistically significant difference by sex ( $P = 0.809$ ). Patients with “other tumor types” (Fig. 3) were statistically less satisfied than those with meningiomas ( $P = 0.004$ ), oligodendrogliomas ( $P = 0.047$ ), low grade astrocytomas ( $P = 0.047$ ), high grade astrocytomas ( $P = 0.011$ ), and metastasis ( $P = 0.024$ ). Otherwise, there were no differences between the tumor types. Patients who had an occipital craniotomy approach were less satisfied than patients who had a temporal approach ( $P = 0.018$ ) or fronto-temporal approach ( $P = 0.021$ ). No differences were found for the other surgical approaches.

### 3.3. Satisfaction with overall cosmetic appearance

Of the 47 patients who responded to this question, 11 (23.4%) reported their satisfaction with the overall cosmetic appearance to be 10 out of 10. A total of 32 (68.1%) patients reported a very satisfactory result (above 7.5) while 2 (4.3%) reported a very unsatisfactory result (below 2.5). The median score was 9.0 out of 10, with an IQR of 7.0–9.9. No statistically significant differences were found when stratifying for age ( $P = 0.431$ ) or sex ( $P = 0.939$ ). Patients with “other tumor types” were again less satisfied, with statistically significant differences from patients with meningiomas ( $P = 0.001$ ), oligodendrogliomas ( $P = 0.014$ ), low grade astrocytomas ( $P = 0.014$ ), high grade astrocytomas ( $P = 0.002$ ), and metastasis ( $P = 0.005$ ). Otherwise, there were no differences between the tumor types. Patients who had an occipital craniotomy approach were less satisfied than those with a temporal approach ( $P = 0.019$ ).

### 3.4. Facial alterations

The 49 patients who responded to this question gave a wide range of responses. While 12 (24.5%) patients reported no facial alterations (0 on the scale), a total of 26 (53.1%) patients reported no or minor alterations, and 12 (24.5%) reported major alterations. The median score was 1.7 out of 10, with an IQR of 1.0–7.2. When comparing patients who reported no or minor alterations with patients with major alterations, no differences were found in satisfaction with the scar ( $P = 0.554$ ) or with overall cosmetic appearance ( $P = 0.497$ ). No significant difference was

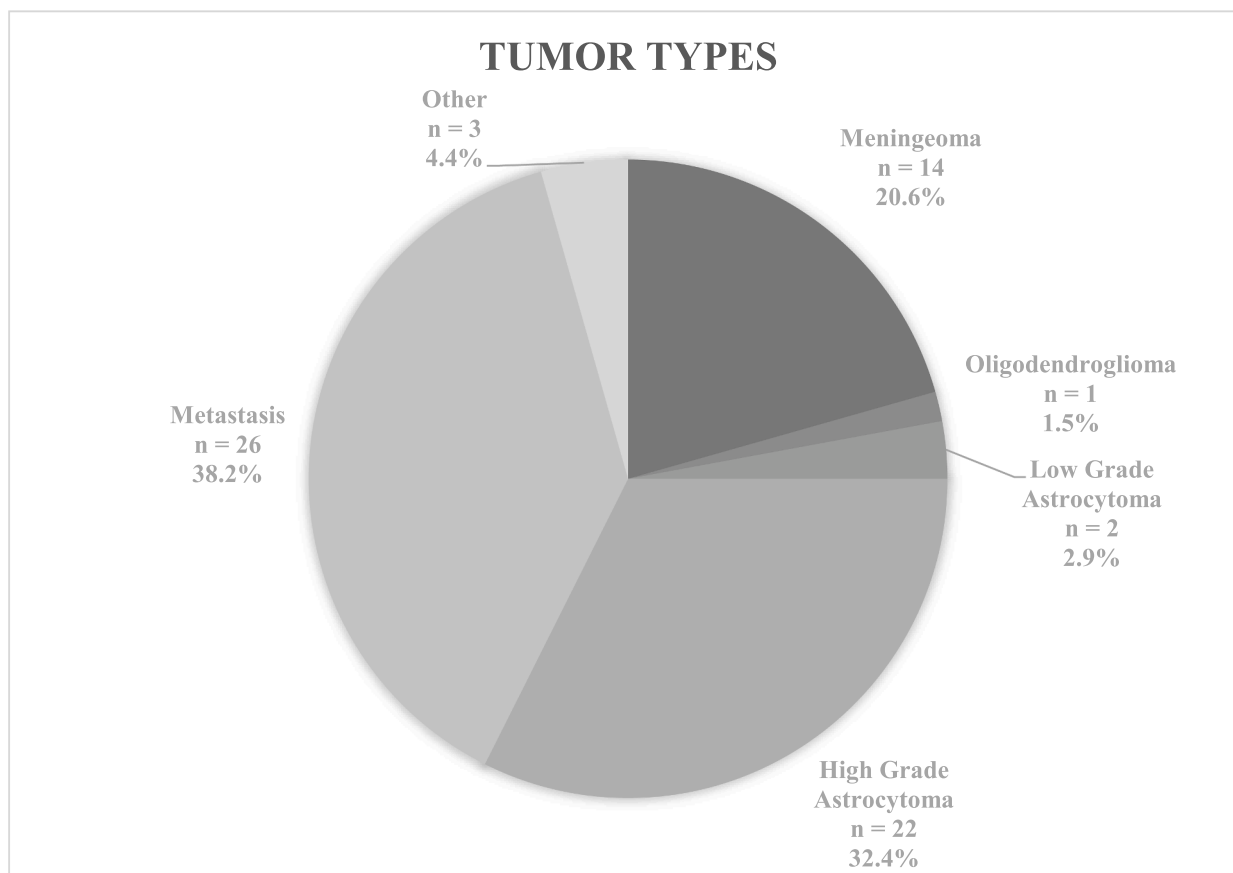


Fig. 1. Distribution of histologically verified tumor types included in the study. The percentages due not add up to 100 due to rounding. (Single column fitting).

found between age groups ( $P = 0.445$ ) although there was a tendency for a more satisfactory result among patients under 40 years old. There were no significant differences by sex ( $P = 0.510$ ), tumor type ( $P = 0.187$ ), or surgical approach ( $P = 0.412$ ).

### 3.5. Complications

Complications were reported by 20 patients (29%). Twelve different complications were registered: 11 patients (15.9%) reported skewness, irregularities, bumps, or subsidence; 5 (7.2%) patients reported pain or tenderness around the surgical wound; three (4.3%) patients reported cerebrospinal fluid leak or infection; and two (2.9%) patients reported slow healing. Other complications reported were paresthesia, headache, and reduced hair growth.

All five patients who reported pain or tenderness and the two patients who reported slow healing were very satisfied with all three outcomes. Ten (90.1%) of the patients who reported skewness, irregularities, bumps, or subsidence were less than satisfied with all three outcomes (below 7.5 in questions 1 and 2, and above 2.5 in question 3). Of the three patients reporting either cerebrospinal fluid leak or infection, two reported very satisfactory results for all outcomes. In contrast, the third reported less than satisfactory results (below 7.5 in questions 1 and 2, and above 2.5 in question 3).

Of the 38 patients not reporting complications, 37 (97.4%) were very satisfied with the scar, 30 (78.9%) were very satisfied with the overall cosmetic appearance, and 22 (57.9%) reported little facial alteration. Thus, there was a tendency for less satisfactory results when patients experienced cosmetic complications such as skewness, irregularities, bumps, or subsidence.

## 4. Discussion

The study results suggest that the patients were generally satisfied with the cosmetic outcome after craniotomy surgery for intracranial tumor. Median scores on a 0–10 scale were 9.3 for satisfaction with the scar and 9.0 for satisfaction with the overall cosmetic appearance, both with narrow IQR.

Although the median score for the extent of facial alteration after surgery was 1.7 (i.e. close to no alterations), almost 25% of patients reported major facial alterations.

A post hoc analysis comparing patients who reported no or minor facial alterations with those who reported major facial alterations showed no differences in satisfaction with the scar or overall cosmetic appearance. This suggests that even though patients generally are satisfied, some of them did experience facial alterations due to the craniotomy. Patients reporting cosmetic complications were the least satisfied on all three outcomes, suggesting that the surgical procedure could be optimized in an attempt to avoid skewness, bumps, subsidence, or other irregularities. As this could have a clinical impact on a considerable number of patients, there should be further investigation into the effects of craniotomy on facial appearance, with more concrete questions about the cosmetic complications.

We expected that patients with more benign tumors (and thus longer life expectancy) would be more dissatisfied with the cosmetic outcome as patients with more malignant tumors and higher mortality might have other concerns besides the aesthetics. We found no significant differences in satisfaction between the tumor types except for patients with “other tumor types”, who were less satisfied than the other groups with the scar and the overall cosmetic appearance. This group was small, however, with only three patients and different tumors (a neurocytoma, an epidermoid cyst, and a subependymoma), making firm conclusions

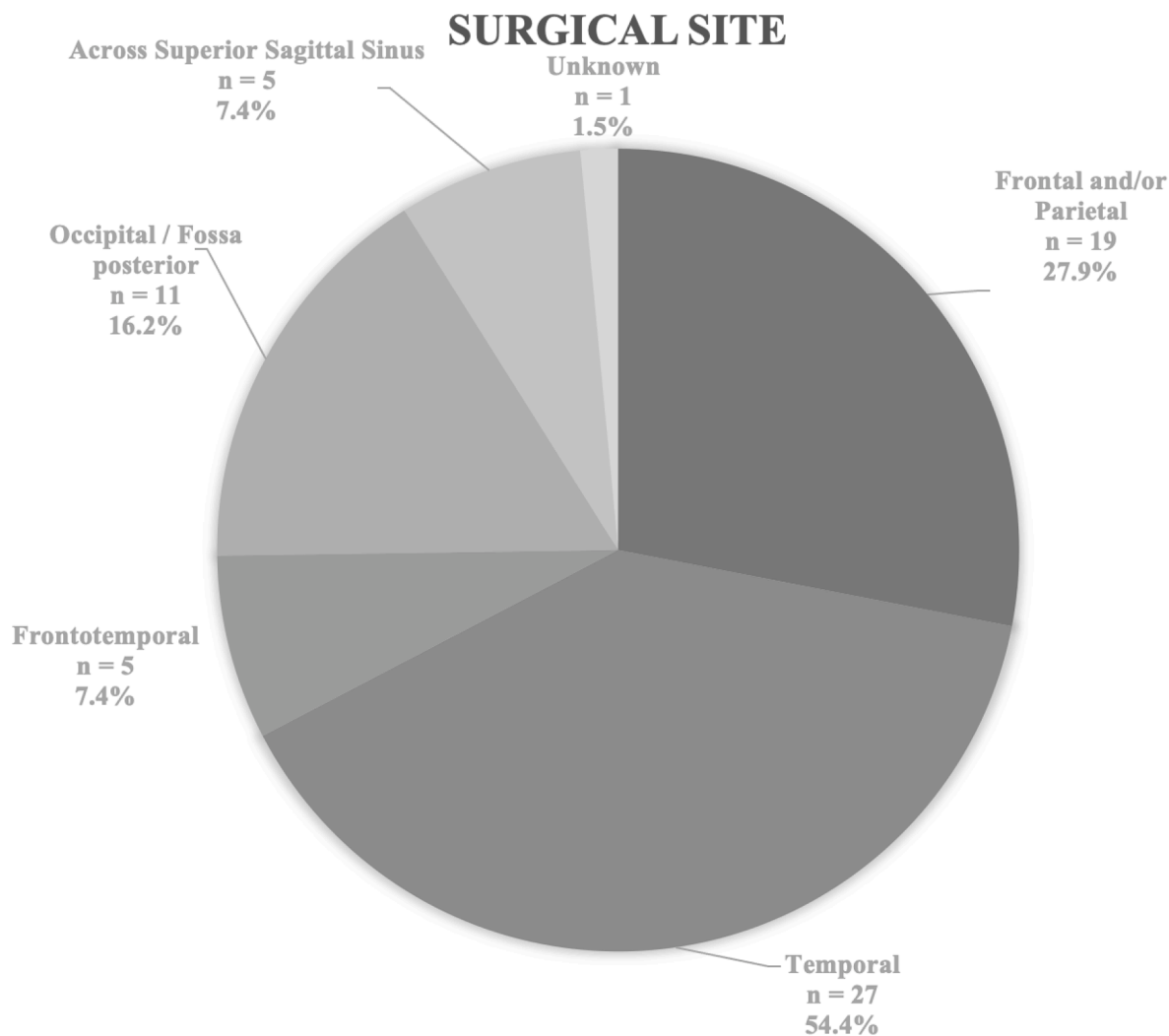


Fig. 2. Distribution of the surgical craniotomy approaches used for gaining access to the tumor. The percentage might not add up due to rounding (Single column fitting).

impossible.

We also expected patients with surgery in frontal or temporal regions to be less satisfied with the cosmetic outcome as these regions are more exposed due to incomplete hair coverage and post-surgical temporal muscle atrophy. In a study on the aesthetic result after polymethyl-methacrylate cranioplasty, Fisher et al. [6] found that patients operated on in the occipital area were more satisfied than patients with operations in the frontal or temporal regions. Therefore, we were surprised to find the opposite where patients with occipital craniotomies were less satisfied than those with temporal or frontotemporal craniotomies regarding the scar and the overall cosmetic appearance. Our study population was exclusively intracranial tumor patients treated with craniotomy, which differs from that of Fisher et al. [6] who included patients receiving cranioplasty with polymethyl-methacrylate to repair skull deficits. This makes it difficult to compare the results directly. In addition, it would have been of interest to ask the patients with occipital scars in more detail why they were unsatisfied. However, as many of our patients will be deceased, it is not possible. A future qualitative study would be beneficial for neurosurgeons to understand this problem in more detail and enable further optimization of occipital craniotomies.

We had expected that frontal, frontotemporal, and temporal craniotomy approaches would have a more significant impact on the face than the other approaches due to the location in the forehead and over the temporal muscle. However, we found no differences in patient-

reported extent of facial alterations according to surgical approach. Moreover, we could find no indication of which patients were most likely to experience facial alterations as no differences were found by age, sex, or tumor type.

Limitations of the study are mainly due to the small sample size and the loss to follow-up. Due to the severity of some of the conditions, a six-month follow-up meant that many patients had died before they could receive and answer the questionnaire (8.8%). On the other hand, if the questionnaire had been sent out earlier, the surgical scar might not have healed completely, leading to less valid results. Sending out the questionnaire later than six months might allow further healing and give the hair more time to grow, which might increase patient satisfaction.

Using a questionnaire can be problematic as each respondent interprets the questions differently, making the responses harder to compare. A future qualitative interview study could help to further explore the importance of cosmetic outcome and changes in facial appearance in patients undergoing craniotomy.

### 5. Conclusion

Despite the limitations of our study, we conclude that most patients are satisfied with the cosmetic outcome after craniotomy. However, a significant portion of patients reported major facial alterations due to surgery, indicating that cosmetic consequences, such as skewness,

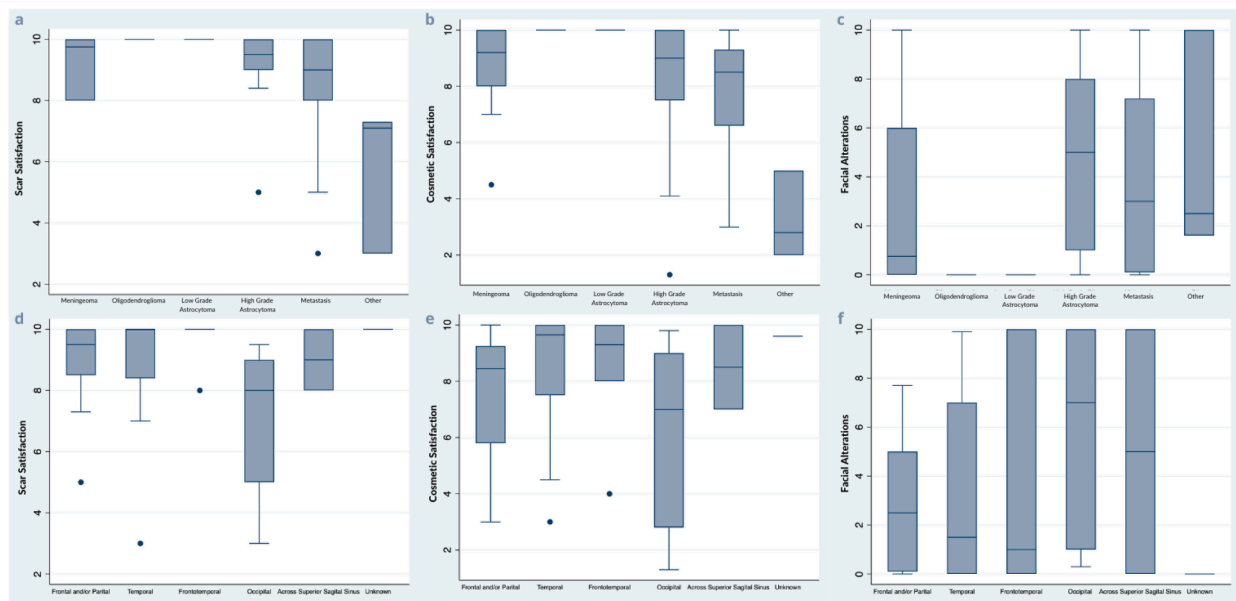
**Table 1**

Subgroup distribution of the 68 patients surgically treated for intracranial tumor according to the three primary outcomes.

Subgroups	n (%)	Satisfaction with scar			Satisfaction with overall cosmetic appearance			Extent of facial alteration		
		Median	IQR	Missing (%)	Median	IQR	Missing (%)	Median	IQR	Missing (%)
<b>Age, years</b>										
< 40 (n = 50)	5 (7.4)	8.0	7.3–8.4	0	7.0	5.0–7.5	0	1.6	0.0–1.7	0
40–60	21 (30.9)	9.5	8.0–10	5	9.0	4.5–10	5	3.0	0.3–9.0	5
> 60	42 (61.8)	9.5	8.4–10	14	9.0	7.0–9.9	16	1.5	0.1–7.2	14
<b>Sex</b>										
Female	37 (54.4)	9.0	8.4–10	10	8.8	7.0–9.9	11	1.1	0.0–7.7	10
Male	31 (45.6)	9.8	8.0–10	9	9.0	5.0–9.9	10	2.1	0.4–7.2	9
<b>Tumor type</b>										
Meningioma	14 (20.6)	9.8	8.0–10	0	9.2	8.0–10	0	0.8	0.0–6.0	0
Oligodendroglioma	1 (1.5)	10	10–10	0	10	10–10	0	0.0	0.0–0.0	0
Low grade astrocytoma	2 (2.9)	10	10–10	1	10	10–10	1	0.0	0.0–0.0	1
High grade astrocytoma	22 (32.4)	9.5	9.0–10	9	9.0	7.5–10	11	5.0	1.0–8.0	9
Metastasis	26 (38.2)	9.0	8.0–10	9	8.5	6.6–9.3	9	3.0	0.1–7.2	9
Other*	3 (4.4)	7.1	3.0–7.3	0	2.8	2.0–5.0	0	2.5	1.6–10	0
<b>Surgical approach</b>										
Frontal and/or parietal	19 (27.9)	9.5	8.5–10	6	8.5	5.8–9.3	7	2.5	0.1–5.0	6
Temporal	27 (39.7)	10	8.4–10	8	9.7	7.5–10	9	1.5	0.0–7.0	8
Frontotemporal	5 (7.4)	10	10–10	0	9.3	8.0–10	0	1.0	0.0–10	0
Occipital	11 (16.2)	8.0	5.0–9.0	2	7.0	2.8–9.0	2	7.0	1.0–10	2
Across superior sagittal sinus	5 (7.4)	9.0	8.0–10	3	8.5	7.0–10	3	5.0	0.0–10	3
Unknown	1 (1.5)	10	10–10	0	9.6	9.6–9.6	0	0.0	0.0–0.0	0
<b>Total</b>	<b>68 (100)</b>			<b>19 (27.9)</b>			<b>21 (30.9)</b>			<b>19 (27.9)</b>

Primary outcomes are patient-reported satisfaction with the scar and the overall cosmetic appearance and the extent of alterations in facial appearance. IQR = interquartile range.

\*One neurocytoma, one epidermoid cyst, and one subependymoma.



**Fig. 3.** Boxplots showing patient-reported satisfaction with the scar and cranial cosmetic appearance and extent of facial alterations due to the craniotomy. Patients were asked to 1) rate their satisfaction with the appearance of the craniotomy scar on a scale from 0 to 10 (10 = most satisfied); 2) rate their satisfaction with overall cosmetic appearance of the cranium after surgery on a scale from 0 to 10 (10 = most satisfied); 3) rate the extent they thought their facial appearance had altered after surgery (0 = no alterations). Satisfaction with the scar by tumor type (a) and by surgical access site (d). Satisfaction with cosmetic appearance by tumor type (b) and by surgical access site (e). Extent of facial alterations by tumor type (c) and by surgical access site (f). (Two column fitting, with color).

bumps, or other skin irregularities, of the craniotomy should be considered when performing the procedure and that the patient should be informed about it prior to surgery.

No difference in the level of satisfaction and facial alterations between age, sex, or tumor groups was found. Yet, the location of the craniotomy might be a factor in the satisfaction of the aesthetic outcome, but further research into this important patient-experienced outcome is needed.

**Funding**

The REDCap database was provided and supported by the Open Patient data Explorative Network (OPEN) in the Region of Southern Denmark. This research did not receive any specific grant from public funding agencies, commercial, or not-for-profit sectors.

### CRediT authorship contribution statement

**Amalie Sofie Vagner Uggerly:** Conceptualization, Methodology, Software, Formal analysis, Investigation, Data curation, Writing – original draft, Writing – review & editing, Visualization, Project administration. **Morten Winkler Moeller:** Formal analysis, Writing – review & editing, Supervision. **Elin Eriksen:** Methodology, Data curation, Writing – review & editing. **Carsten Reidies Bjarkam:** Methodology, Writing – review & editing, Supervision. **Frantz Rom Poulsen:** Conceptualization, Methodology, Writing – review & editing, Supervision, Project administration.

### Declaration of Competing Interest

The authors declare that they have no known competing financial interests or personal relationships that could have appeared to influence the work reported in this paper.

### Acknowledgment

The proofreading assistance from Claire Gudex is greatly

appreciated.

### References

- [1] M. Rivera, S. Norman, R. Sehgal, R. Juthani, Updates on Surgical Management and Advances for Brain Tumors, *Curr. Oncol. Rep.* 23 (3) (2021) 35.
- [2] A. Frati, A. Pichierri, V. Esposito, R. Frati, R. Delfini, G. Cantore, et al., Aesthetic issues in neurosurgery: a protocol to improve cosmetic outcome in cranial surgery, *Neurosurg. Rev.* 30 (1) (2007) 69–76, discussion -7.
- [3] S. Sato, M. Sato, M. Nishizawa, T. Oizumi, M. Hiwatari, T. Kajiwaru, et al., Method to improve cosmetic outcome following craniotomy, *Neurol. Res.* 23 (4) (2001) 339–342.
- [4] L.N. Sekhar, The cosmetic aspects of neurosurgery, *Neurosurg. Clin. N. Am.* 13 (4) (2002) 401–403.
- [5] P.A. Harris, R. Taylor, R. Thielke, J. Payne, N. Gonzalez, J.G. Conde, Research electronic data capture (REDCap)—a metadata-driven methodology and workflow process for providing translational research informatics support, *J. Biomed. Inform.* 42 (2) (2009) 377–381.
- [6] C.M. Fischer, J.K. Burkhardt, J. Samthein, R.L. Bernays, O. Bozinov, Aesthetic outcome in patients after polymethyl-methacrylate (PMMA) cranioplasty - a questionnaire-based single-centre study, *Neurol. Res.* 34 (3) (2012) 281–285.