



Aalborg Universitet

AALBORG UNIVERSITY
DENMARK

Silent cerebral lesions following catheter ablation for atrial fibrillation

a state-of-the-art review

Calvert, Peter; Kollias, Georgios; Pürerfellner, Helmut; Narasimhan, Calambur; Osorio, Jose; Lip, Gregory Y.H.; Gupta, Dhiraj

Published in:
Europace

DOI (link to publication from Publisher):
[10.1093/europace/euad151](https://doi.org/10.1093/europace/euad151)

Creative Commons License
CC BY-NC 4.0

Publication date:
2023

Document Version
Publisher's PDF, also known as Version of record

[Link to publication from Aalborg University](#)

Citation for published version (APA):
Calvert, P., Kollias, G., Pürerfellner, H., Narasimhan, C., Osorio, J., Lip, G. Y. H., & Gupta, D. (2023). Silent cerebral lesions following catheter ablation for atrial fibrillation: a state-of-the-art review. *Europace*, 25(6), Article euad151. <https://doi.org/10.1093/europace/euad151>

General rights

Copyright and moral rights for the publications made accessible in the public portal are retained by the authors and/or other copyright owners and it is a condition of accessing publications that users recognise and abide by the legal requirements associated with these rights.

- Users may download and print one copy of any publication from the public portal for the purpose of private study or research.
- You may not further distribute the material or use it for any profit-making activity or commercial gain
- You may freely distribute the URL identifying the publication in the public portal -

Take down policy

If you believe that this document breaches copyright please contact us at vbn@aub.aau.dk providing details, and we will remove access to the work immediately and investigate your claim.

Silent cerebral lesions following catheter ablation for atrial fibrillation: a state-of-the-art review

Peter Calvert ^{1,2}, Georgios Kollias ³, Helmut Pürerfellner ³,
Calambur Narasimhan ⁵, Jose Osorio ⁶, Gregory Y. H. Lip ^{1,2,4},
and Dhiraj Gupta ^{1,2*}

¹Liverpool Centre for Cardiovascular Science at University of Liverpool, Liverpool John Moores University and Liverpool Heart & Chest Hospital, Liverpool, UK; ²Department of Cardiology, Liverpool Heart & Chest Hospital NHS Foundation Trust, Thomas Drive, Liverpool L14 3PE, UK; ³Ordensklinikum Linz Elisabethinen, Linz, Austria; ⁴Danish Centre for Clinical Health Services Research, Aalborg University, Aalborg, Denmark; ⁵Department of Cardiac Electrophysiology, AIG Hospitals, 1-66/AIG/2 to 5, Mindspace Road, Gachibowli Hyderabad, Telangana 500032, India; and ⁶Grandview Medical Center, Arrhythmia Institute at Grandview, 3686 Grandview Parkway Suite 720, Birmingham, AL 35243, USA

Received 3 February 2023; editorial decision 25 April 2023; accepted after revision 25 April 2023

Abstract

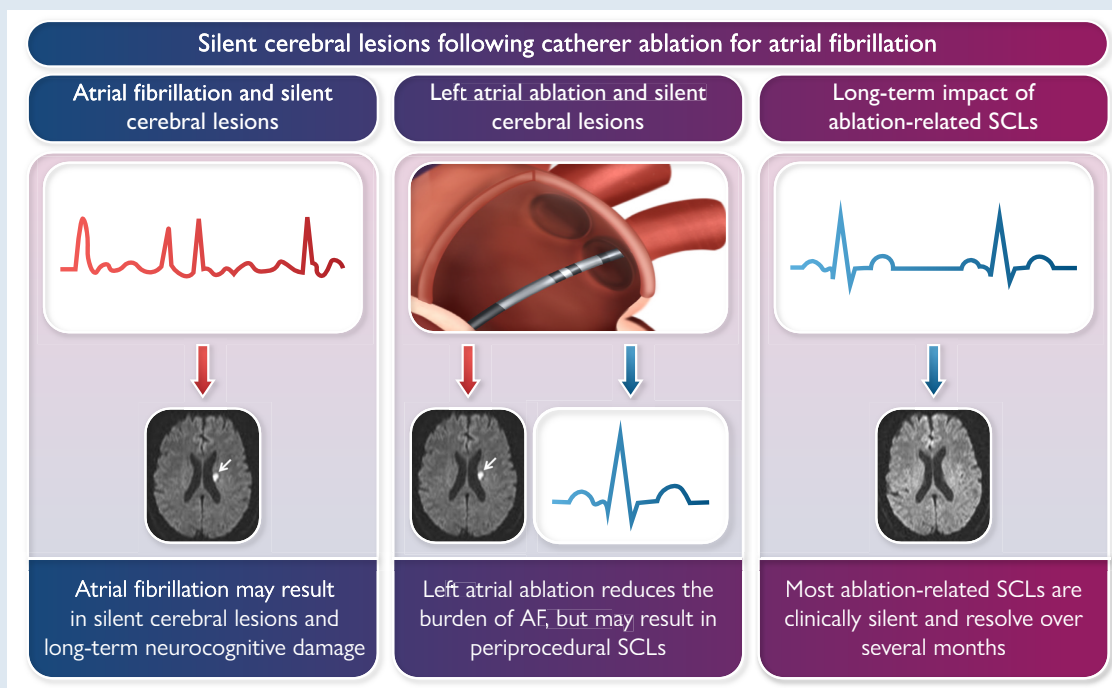
Atrial fibrillation is associated with neurocognitive comorbidities such as stroke and dementia. Evidence suggests that rhythm control—especially if implemented early—may reduce the risk of cognitive decline. Catheter ablation is highly efficacious for restoring sinus rhythm in the setting of atrial fibrillation; however, ablation within the left atrium has been shown to result in MRI-detected silent cerebral lesions. In this state-of-the-art review article, we discuss the balance of risk between left atrial ablation and rhythm control. We highlight suggestions to lower the risk, as well as the evidence behind newer forms of ablation such as very high power short duration radiofrequency ablation and pulsed field ablation.

* Corresponding author. Tel: +44 151 600 1616, E-mail address: dhiraj.gupta@lhch.nhs.uk

© The Author(s) 2023. Published by Oxford University Press on behalf of the European Society of Cardiology.

This is an Open Access article distributed under the terms of the Creative Commons Attribution-NonCommercial License (<https://creativecommons.org/licenses/by-nc/4.0/>), which permits non-commercial re-use, distribution, and reproduction in any medium, provided the original work is properly cited. For commercial re-use, please contact journals.permissions@oup.com

Graphical Abstract



Keywords

Atrial fibrillation • Neurocognitive • Neurological • Dementia • Cognition • Ablation

What's new?

- Silent cerebral lesions may arise secondary to left atrial ablation for atrial fibrillation.
- The majority of these lesions are asymptomatic and regress over time.
- It is crucial that electrophysiologists are aware of factors which increase the risk of silent cerebral lesion formation and techniques to minimize this risk.

Introduction

Atrial fibrillation (AF), the most common cardiac arrhythmia, is associated with neurocognitive sequelae such as cardioembolic stroke, formation of silent cerebral lesions (SCLs), cognitive decline, and dementia.^{1–4} Dementia and stroke significantly affect the quality of life for both patients and carers and place a substantial burden on the healthcare economy.⁵

A number of pathophysiologic mechanisms underlie the relationship between AF and dementia. The irregular cardiac rhythm during AF may lead to blood–brain barrier damage and abnormal cerebral blood flow,⁶ with micro-hypertensive and hypotensive events causing microbleeds and hypoperfusion, respectively. AF has been associated with both vascular and Alzheimer's dementia.^{7,8} Longer duration of AF with poor rate control and added cardiovascular comorbidity increases the risk further.^{9–11}

As always, prevention is better than cure. While it is well recognized that anticoagulation reduces the risk of stroke in patients with AF, it may be less appreciated that effective AF management—ideally following the guideline-recommended Atrial fibrillation Better Care (ABC)

pathway¹²—can also reduce the risk of dementia, as well as other cardiovascular outcomes.^{13,14} It may even be advisable to screen newly diagnosed dementia patients for AF as a way to potentially slow cognitive decline.¹⁵

Rhythm control with catheter ablation has become a common way to manage the symptoms of AF, and potential prognostic benefits are emerging in recent research including significant reduction or even elimination of AF burden.¹⁶ Indeed, the data suggest that rhythm control—particularly with catheter ablation—may improve the risk of neurocognitive decline in patients with AF. Mechanistically, studies have shown that restoring sinus rhythm improves cerebral blood flow.^{6,17} However, some studies also suggest the main benefit is seen in younger patients, with less structural heart disease or comorbidities, and if rhythm control is implemented earlier in the course of AF (<3 months).^{18,19} Risk factor modification is also complementary with regard to modulating neurocognitive decline in patients with AF.^{20–23}

While catheter ablation may be highly effective, ablation within the left atrium (LA) may itself cause the formation of SCLs—so how do we balance the risk? We will explore this concept in this narrative review article.

Left atrial catheter ablation and silent cerebral lesions

While periprocedural stroke is a recognized complication of LA catheter ablation, it may be less well appreciated that the same procedure can cause clinically silent emboli, resulting in SCLs (*Figure 1*). These may occur despite anticoagulation^{24,25} and are associated with persistent AF, the presence of spontaneous echocardiographic contrast on periprocedure transoesophageal echocardiography, and prolonged

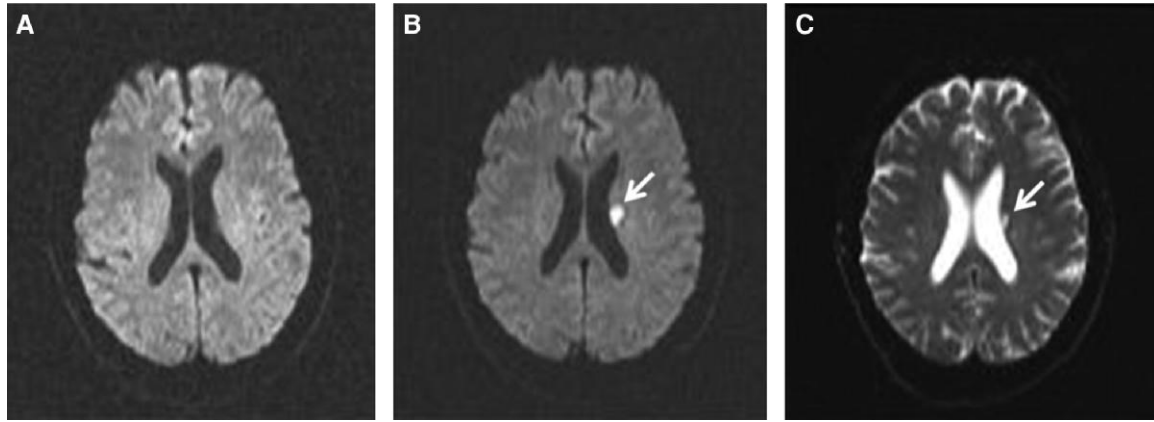


Figure 1 (A) Diffusion-weighted brain magnetic resonance imaging (DW-MRI) prior to pulmonary vein isolation (PVI); (B) DW-MRI post-PVI; and (C) echo-planar T2-weighted MRI at 3 months. Note the presence of a new embolic lesion following PVI which persists at 3 months in this case. Reproduced with permission from Martinek et al.²⁴

procedural times.²⁴ Intraprocedural electrical cardioversion also appears strongly related to the risk of SCL formation.^{24,25}

The mechanism of SCL formation during ablation is multifactorial. First, air or thrombus entry via sheaths may occur. Second, coagulum may form on the catheter itself, or over-delivered ablation lesions. Third, gas bubble formation may occur during ablation. The modality of ablation, including catheter type, affects this risk. In this section, we will discuss the main factors affecting ablation-related SCL risk in detail.

Intraprocedural anticoagulation—keeping up the ACT

Wazni *et al.* found that periprocedural stroke/TIA was reduced by maintaining a higher activated clotting time (ACT) during ablation.²⁶ A significant reduction was seen comparing ACT levels between 250 and 300 s and those between 350 and 400 s. This study used a non-irrigated catheter, which may have affected microbubble formation and thromboembolic risk, and did not assess SCL prevalence. Similarly, Ren *et al.* found a reduced incidence of LA thrombus (detected via intracardiac echocardiography) in those with ACT >300 s compared with 250–300 s.²⁷ Oddly, in this study, spontaneous echocardiographic contrast was reportedly more common in the higher ACT group, despite no significant differences in other parameters.

Pre-procedural anticoagulation is also important. Early studies showed that thromboembolic risk—and indeed bleeding complications—were reduced with a strategy of uninterrupted Warfarin compared with Heparin bridging.²⁸ There was initial controversy when comparing direct oral anticoagulants (DOACs) to vitamin K antagonists (VKAs), with some studies finding a higher risk of thromboembolic complications with DOACs.^{29,30} However, many studies have since demonstrated comparable risk, often with a lower rate of bleeding complications using DOACs.^{31–37} Notably, target ACT may be more difficult to achieve using certain DOACs—specifically dabigatran.^{38,39}

A 'belt-and-braces' approach with uninterrupted pre-procedural anticoagulation, heparin bolus prior to—or immediately following—transseptal puncture, and ACT maintained at >300 s appears highly effective.⁴⁰ Di Biase *et al.* showed that this reduced SCL frequency to just 2%, compared with 7% in those whose INR was subtherapeutic or who had ACT <300 s on two or more occasions. The highest risk—14%—was seen in those bridged with heparin.⁴⁰

Notably, transcranial Doppler studies suggest that not all the ablation-related signals are thrombotic; the majority may be gaseous.⁴¹

This suggests that even intense anticoagulation is unlikely to prevent all SCLs.

Intraprocedural electrical cardioversion—a shocking discovery?

A number of studies have shown that intraprocedural electrical cardioversion is an independent predictor of SCLs.^{25,29,42} Mechanistically, this might relate to the dislodgement of thrombotic material from equipment—or from fresh ablation lesions—due to the sudden movement caused by direct current cardioversion or by restoration of atrial contraction.

In the study by Gaita *et al.*, SCL risk was lowest in those who remained in sinus rhythm throughout the procedure (9%), and those in whom sinus rhythm was restored with ablation alone (14%; $P = 0.331$).²⁵ The risk increased to 26% in those undergoing a composite of pharmacologic or electrical cardioversion. However, the vast majority of these patients underwent electrical cardioversion (53 vs. 9), so it is difficult to draw conclusions about pharmacological cardioversion. The available evidence suggests that the risk is highest in those who remain in AF at the end of the procedure and thus undergo electrical cardioversion.

Pre-ablation cardioversion with the maintenance of sinus rhythm throughout the procedure may reduce the risk further; however, this is not always achievable in the persistent AF population.

One study trialed delayed cardioversion at 4 weeks post-ablation.⁴³ The investigators found that the risk of SCL formation was significantly reduced with this approach.

Interestingly, in direct contrast to the above, two studies demonstrated that cardioversion was not an independent predictor of SCLs.^{44,45} The major difference was that these two studies utilized second-generation cryoballoons, while those described above utilized radiofrequency (RF) ablation, or combined multiple modalities. This raises the hypothesis that the difference in thermodynamics and lesion formation might result in more risk with cardioversion in the setting of RF, but not cryoablation. This would require further study to confirm.

Standard ablation modalities—radiofrequency and cryoballoon

RF and cryoballoon are modalities used widely throughout the world of AF ablation. Both approaches have advantages and disadvantages;

however, in terms of outcome, they tend to perform similarly.^{46,47} The neurological impact of ablation using non-irrigated RF, irrigated RF, and cryoablation has been extensively studied.

Transcranial Doppler monitoring studies show significant micro-embolic signals with any ablation modality. The number of signals appears much higher with non-irrigated RF compared with irrigated RF and appears lowest—but not negligible—with cryoablation.⁴⁸ Some have noted that these signals are similar to those seen during cardiac surgery, which are associated with significant neurocognitive abnormalities.⁴⁹ However, it should be remembered that interventional electrophysiological procedures are far less invasive than open heart surgery—and the latter is more likely to be complicated by post-operative delirium. Equally, the demographics, comorbidities, and functional status of patients undergoing open cardiac surgery likely differ from those undergoing AF ablation.

Bench studies have demonstrated a higher degree of blood damage, platelet activation, and thrombogenesis with RF ablation compared to cryoablation, suggesting the latter should be safer.⁵⁰ In real-world studies, however, lesion frequency detected by MRI appears similar between irrigated RF and cryoballoon.^{51,52}

Several studies have compared SCL rates between irrigated RF, cryoballoon, and the multielectrode phased RF (PVAC) catheter.^{41,53–56} The consistent finding between these studies is that the PVAC catheter resulted in a substantially higher rate of SCL formation. Similarly, the NMARQ multielectrode catheter was noted to cause SCLs in a third of patients.⁵⁷ One study noted that most thromboembolic events with the PVAC occurred when all 10 electrodes were used for ablation.⁵⁶ Subsequent studies showed that by deactivating certain electrodes, the number of Doppler-detected embolic signals and MRI-detected SCLs was reduced to a similar value to that seen during irrigated RF ablation.^{58–60}

Another alternative ablation modality is the laser balloon. Two studies found that this caused a similar number of SCLs as irrigated RF and cryoablation.^{52,61}

In terms of risk reduction, it is worth noting that exchanging catheters via a single transeptal sheath may increase the number of SCLs, regardless of ablation modality.⁶² Another study tested extracorporeal cryoballoon inflation with removal of air using heparinized saline, in order to try to reduce the risk of air embolism—however, this had no effect on the SCL rate.⁶³ Reinsertion of a withdrawn cryoballoon appears to significantly increase the risk.⁴⁴ With RF ablation, it is becoming increasingly common to utilize a single transeptal approach. While this has been shown to be safe and effective, some studies report longer procedural times due to frequent catheter exchanges,⁶⁴ which may also increase the SCL risk as described above. An alternative approach is to perform mapping with the ablation catheter itself, thus negating the need for a mapping catheter while also reducing the number of exchanges. This approach has been shown to be safe, effective, and cost-saving.^{65–67}

It is worth noting that there is considerable heterogeneity between studies—for example, the contact force is not standardized across RF studies, and the method of assessment (transcranial Doppler or MRI with varying sequences and techniques) also differs.

Newer ablation modalities

Very high-power, short-duration ablation

As the name suggests, very high-power, short-duration ablation (vHPSD) involves high power (up to 90 watts) RF ablation delivered over a short duration (as little as 4 s). Few studies have assessed the neurocognitive impact of vHPSD ablation to date.

The seminal QDOT-FAST trial in 2019 reported a high rate SCLs in 6 of 51 patients (11.8%), albeit with no clinical strokes or cognitive impairment.⁶⁸ Repeat MRI at 1 month demonstrated resolution of SCLs in all but one patient, and none showed neurological symptoms. Higher SCL rates have been noted by two further studies. Halbfass

et al. found SCLs in 5 of 21 patients (24%) undergoing vHPSD ablation.⁶⁹ Only the subgroup of patients undergoing ablation using the new nGEN RF generator was scanned, thus comparisons with other technologies are difficult to draw. However, the nGEN generator was also associated with an increased rate of catheter tip charring (11% of cases). Subsequently, the nGEN generator underwent software modification. The same author group recently studied SCL frequency using this modified nGEN generator and, unfortunately, found SCLs in 6 of 23 patients (26%).⁷⁰ Catheter tip coagulum was noted in six patients, two of whom had SCLs on MRI (three were not scanned). Again, no neurological symptoms were seen. Interestingly, the authors modified the position of the neutral electrode for the final 14 patients, in order to keep the baseline circuit impedance above 110Ω. Following this, no further catheter tip charring occurred; the effect of this impedance change on SCLs was not stated, though it is likely that larger patient numbers would be needed to confirm a difference.

Notably in these studies, catheter tip coagulum and charring did not result in SCLs in all patients. This aligns with findings from transcranial Doppler studies, as discussed earlier, showing that most signals were gaseous rather than solid.⁴¹

No trials to date have performed a longer-term neuropsychiatric assessment of patients following vHPSD ablation.

Pulsed field ablation

Pulsed field ablation (PFA) is a new technology, promising to revolutionize the field of AF ablation. PFA works by using electrical fields to induce the electroporation of cells. As different cell types have different electroporation thresholds, PFA brings significant safety advantages by minimizing damage to extracardiac structures such as the esophagus and phrenic nerve.

In neurological terms, bench data using canines showed gas bubble formation during ablation; however, no neurological sequelae were seen, and MRI was normal in 10 of 11 subjects.⁷¹ The one lesion seen was of unclear significance and was undetectable on histopathological examination.

One-year outcomes from the IMPULSE and PEFCAT I + II studies found that PFA was very safe, with only 1 TIA in 121 patients.⁷² Echogenic bubble formation was observed with ICE during ablation; however, this did not appear to result in significant adverse effects. Of the 18 patients who underwent cranial MRI scanning post-PFA ablation, 1 (who had suffered a clinical TIA) showed an acute lesion, and another had a single SCL. No lesions were found in the remaining 16 patients. This is reassuring, although low numbers are a limitation. The MANIFEST-PF survey, including data on 1758 patients across 24 clinical centers, reported TIAs in 2 patients (0.11%) and stroke in 7 patients (0.39%).⁷³ At least three of these strokes were attributed to sheath management and catheter exchange, rather than PFA itself, although this is obviously impossible to prove.

A recent study by Reinsch et al. directly studied the effects of PFA on SCL formation and neurological deficit in 30 patients.⁷⁴ No neurological deficits were detected and MRI was normal in all but one patient. The single detected SCL was no longer present at a repeat MRI 40 days later.

Larger studies on neurocognitive effects following PFA will be needed—these should include both MRI (ideally pre- and post-ablation and at longer-term follow-up) along with neuropsychiatric testing at these same intervals. Transcranial Doppler studies may also be beneficial to contrast with similar studies using other ablation modalities.

How clinically important are ablation-related silent cerebral lesions?

There is a clear and logical reason to worry about SCLs and how they might link to progressive neurocognitive decline. Vermeer et al. showed

almost 20 years ago that SCLs were associated with a greater than two-fold increased risk of developing dementia.⁷⁵ It is important to remember, however, that the evolution of treatment and risk factor modification since this study may have altered the risk relationship. How, then, do SCLs caused by ablation affect long-term outcome—and should we worry about them?

A number of studies have assessed neurocognitive outcomes following ablation, particularly in relation to SCLs. Schwarz *et al.* found a reduction in verbal memory (just one of seven assessed domains). However, this study was likely underpowered, recruiting just 21 patients of whom only 2 had SCLs detected post-ablation, along with one clinical stroke.⁷⁶ This study used a healthy non-AF control group which affects the interpretability of the result. Additionally, verbal memory decline occurred mostly in patients without SCLs—and only in one of the two patients with SCL—so this may be a case of correlation, not causation.

Zhang *et al.* found an increased risk of short-term cognitive decline immediately post-ablation.⁷⁷ Risk factors included activated clotting time <300 s during the procedure and lack of pre-operative oral anticoagulation—both factors associated with SCL formation as described earlier. Despite this, cognitive performance either returned to baseline or improved by 6-month follow-up. Medi *et al.* found cognitive dysfunction was present in 27–28% of patients post-ablation, improving to 13–20% at 90 days, with left atrial dwell time being independently predictive.⁷⁸ This study did not include MRI assessment, so the correlation with SCLs cannot be determined.

The 2011 MEDAFI study found new SCLs in 8% of patients post-ablation, with no neurological effects.⁵¹ The investigators also noted that 12% of patients had chronic SCLs prior to ablation, and no additional lesions were detected during short-term (median 4-month) follow-up.

Some studies found very high rates of SCLs (30–40%) due to the use of multielectrode ablation catheters as described earlier. It is significant that no neurological abnormalities were detected despite this.⁵³ The MACPAF study, using an uncommon ‘mesh ablator,’ found SCLs in over 40% of patients.⁷⁹ Again, despite this exceptionally high figure, neuropsychiatric assessments were not significantly abnormal. Those

with lesions underwent repeat MRI at 6 months, and persistent lesions were present in less than a third. Those with persistent lesions continued to have normal neuropsychiatric assessments. This is in keeping with earlier research, which showed that 94% of smaller (≤ 10 mm) post-ablation SCLs resolved by 3 months.⁸⁰ Larger lesions persisted as glial scarring but remained asymptomatic.

The recently published AXAFA-AFNET 5 trial found SCLs in 26.1% of patients.⁸¹ Cognitive assessment 3 months post-ablation was not different between those with and without SCLs. In fact, cognitive change was only associated with older age, after multivariable adjustment.

Two studies have even demonstrated small improvements in cognitive function following ablation. Wang *et al.* compared ablation against drug therapy, finding a small decrease in cognition with drug therapy vs. a small increase with ablation, and no interaction with ablation modality.⁸² Kato *et al.* found microinfarctions in over 85% of patients post-ablation; however, despite this, 6-month assessments showed small improvements in memory, constructional, and frontal lobe function.⁸³

Overall, post-ablation SCLs do not appear to have a meaningful effect on neurocognitive function, and the vast majority spontaneously resolve within a few months. However, there are limitations to this evidence as we describe below.

Limitations to the evidence

First, as mentioned earlier, it is difficult to perform very long-term follow-up of patients in a robust fashion. Second, confounding may be present as SCLs may be linked to factors such as age,⁵¹ renal function,⁶³ coronary disease,⁸⁴ left ventricular dilatation or hypertrophy,⁸⁴ spontaneous echocardiographic contrast,²⁴ type of AF,²⁴ as well as other cardiovascular risk factors.^{85,86} Many studies do not assess the presence of SCLs before ablation in order to determine which were a procedural consequence and which were pre-existing.

Third, the modality of MRI scanning may affect the number—or type—of SCLs detected. Yu *et al.* elegantly demonstrated this by scanning patients 48-h post-ablation with both high-resolution diffusion-weighted imaging (DWI) and standard DWI.⁸⁷ SCLs were seen in 67.3% of patients with high-resolution DWI compared with 41.8%

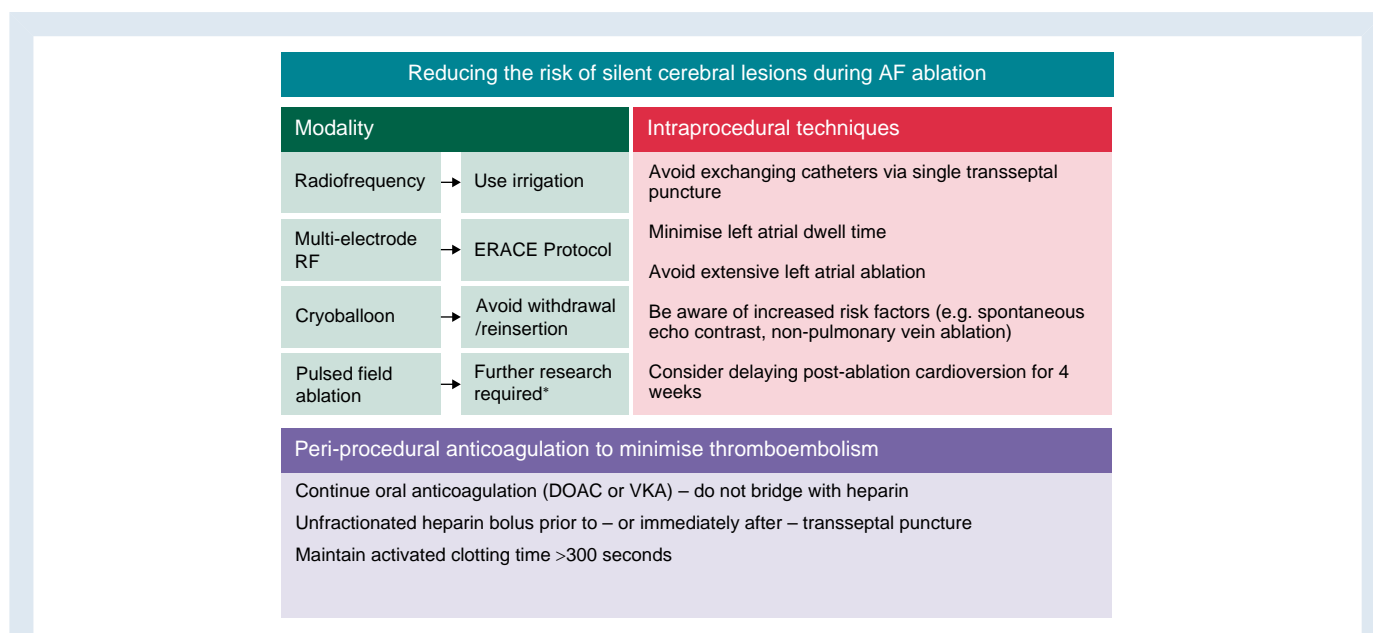


Figure 2 Approaches to minimize ablation-related silent cerebral lesion formation; AF, atrial fibrillation; DOAC, direct oral anticoagulant; ERACE, evaluation and reduction of asymptomatic cerebral embolism in ablation of atrial fibrillation (Verma *et al.* *Circulation Arrhythmia & Electrophysiology* 2013 Oct; 6(5):835–42); VKA, vitamin K antagonist.

with standard DWI ($P < 0.001$). Again, in keeping with multiple studies discussed here, no neurocognitive impairment was seen in any patient.

Finally, the exact definition of SCL differs between studies; for example, some differentiate microbleeds and microinfarcts, while others utilize different terminology, such as 'silent' or 'asymptomatic' cerebral 'lesions' and 'events'—sometimes defined by specific MRI findings.

Avoiding silent cerebral emboli

Regardless of the short-term impact, it is clearly desirable to avoid periprocedural SCLs if at all possible. Even if they do not appear harmful, they are certainly not beneficial. The difference between an SCL and an ablation-related stroke may simply be a matter of luck in terms of where in the brain the lesion appears. Risk reduction strategies are therefore important. Our suggestions for this are summarized in Figure 2.

Additional factors which may affect SCL risk include periprocedural hypotension and hypoxia, which should be avoided if possible. There is also evidence that antiplatelets can rapidly reduce micro-embolic signals in the setting of stroke,⁸⁸ though how this applies in the setting of ablation with Heparin on board is less clear. Future research should focus on these aspects, as well as the neurocognitive effects of PFA, and the timing of intraprocedural cardioversion, including the interaction with different ablation modalities.

Given the significant differences in SCL rates seen with some ablation modalities, such as the multi-electrode catheters described earlier, it may be prudent for regulatory authorities to consider mandatory trials assessing the neurocognitive impact of new ablation modalities prior to their approval.

Conclusion

Catheter ablation within the left atrium may be of significant benefit for those with symptomatic AF, and a prognostic benefit may be emerging in recent studies. However, such procedures may result in neurological injury, represented by SCLs seen on MRI scan. Fortunately, current evidence suggests that the majority of these lesions are asymptomatic and resolve over a short period of time.

Effective management of sheaths, continuation of pre-procedural anticoagulation, maintenance of ACT >300 s, and consideration of delayed cardioversion may reduce the risk of neurological effects. The upfront risk of ablation-related SCLs may be offset by restoration of sinus rhythm and consequent reduction in long-term exposure to AF.

Much akin to the situation with new diabetic agents and cardiovascular outcomes, regulatory authorities should give due consideration to the potential neurocognitive effects of new ablation modalities during the approval process.

Conflict of interest: DG reports: institutional research grants from Boston Scientific and Medtronic and speaker fees from Boston Scientific. GYHL reports: consultant and speaker for BMS/Pfizer, Boehringer Ingelheim, and Daiichi Sankyo. No fees are received personally. The other authors report no conflicts of interest.

Data availability

No new data were generated as part of this work.

References

- Kokkinidis DG, Zareifopoulos N, Theochari CA, Arfaras-Melainis A, Papanastasiou CA, Uppal D et al. Association between atrial fibrillation and cognitive impairment in individuals with prior stroke: a meta-analysis and meta-regression analysis. *Stroke* 2020;**51**:1662–6.
- Papanastasiou CA, Theochari CA, Zareifopoulos N, Arfaras-Melainis A, Giannakoulas G, Karamitsos TD et al. Atrial fibrillation is associated with cognitive impairment, all-cause dementia, vascular dementia, and Alzheimer's disease: a systematic review and meta-analysis. *J Gen Intern Med* 2021;**36**:3122–35.
- Stefanidis KB, Askev CD, Greaves K, Summers MJ. The effect of non-stroke cardiovascular disease states on risk for cognitive decline and dementia: a systematic and meta-analytic review. *Neuropsychol Rev* 2018;**28**:1–15.
- Koh YH, Lew LZW, Franke KB, Elliott AD, Lau DH, Thiyagarajah A et al. Predictive role of atrial fibrillation in cognitive decline: a systematic review and meta-analysis of 2.8 million individuals. *Europace* 2022;**24**:1229–39.
- Xu J, Zhang Y, Qiu C, Cheng F. Global and regional economic costs of dementia: a systematic review. *Lancet* 2017;**390**:S47.
- Saglieppo A, Scarsoglio S, Canova D, Roatta S, Gianotto N, Piccotti A et al. Increased beat-to-beat variability of cerebral microcirculatory perfusion during atrial fibrillation: a near-infrared spectroscopy study. *Europace* 2021;**23**:1219–26.
- Proietti R, Alturki A, Vio R, Licchelli L, Rivezzi F, Marafi M et al. The association between atrial fibrillation and Alzheimer's disease: fact or fallacy? A systematic review and meta-analysis. *J Cardiovasc Med (Hagerstown)* 2020;**21**:106–12.
- Benenati S, Canale C, De Marzo V, Della Bona R, Rosa GM, Porto I. Atrial fibrillation and Alzheimer's disease: a conundrum. *Eur J Clin Invest* 2021;**51**:e13451.
- Cacciatore F, Testa G, Langellotto A, Galizia G, Della-Morte D, Gargiulo G et al. Role of ventricular rate response on dementia in cognitively impaired elderly subjects with atrial fibrillation: a 10-year study. *Dement Geriatr Cogn Disord* 2012;**34**:143–8.
- Kim D, Yang PS, Yu HT, Kim TH, Jang E, Sung JH et al. Risk of dementia in stroke-free patients diagnosed with atrial fibrillation: data from a population-based cohort. *Eur Heart J* 2019;**40**:2313–23.
- Giannone ME, Filippini T, Whelton PK, Chiari A, Vitolo M, Boriani G et al. Atrial fibrillation and the risk of early-onset dementia: a systematic review and meta-analysis. *J Am Heart Assoc* 2022;**11**:e025653.
- Lip GYH. The ABC pathway: an integrated approach to improve AF management. *Nat Rev Cardiol* 2017;**14**:627–8.
- Romiti GF, Pastori D, Rivera-Caravaca JM, Ding WY, Gue YX, Menichelli D et al. Adherence to the 'atrial fibrillation better care' pathway in patients with atrial fibrillation: impact on clinical outcomes—a systematic review and meta-analysis of 285,000 patients. *Thromb Haemost* 2022;**122**:406–14.
- Kim D, Yang PS, Jang E, Yu HT, Kim TH, Uhm JS et al. Association of anticoagulant therapy with risk of dementia among patients with atrial fibrillation. *Europace* 2021;**23**:184–95.
- Schnabel RB, Marinelli EA, Arbelo E, Boriani G, Boveda S, Buckley CM et al. Early diagnosis and better rhythm management to improve outcomes in patients with atrial fibrillation: the 8th AFNET/EHRA consensus conference. *Europace* 2023;**25**:6–27.
- Kirchhof P, Camm AJ, Goette A, Brandes A, Eckardt L, Elvan A et al. Early rhythm-control therapy in patients with atrial fibrillation. *N Engl J Med* 2020;**383**:1305–16.
- Gardarsdottir M, Sigurdsson S, Aspelund T, Gardarsdottir VA, Forsberg L, Gudnason V et al. Improved brain perfusion after electrical cardioversion of atrial fibrillation. *Europace* 2020;**22**:530–7.
- Chao TF, Chan YH, Chiang CE, Tuan TC, Liao JN, Chen TJ et al. Early rhythm control and the risks of ischemic stroke, heart failure, mortality, and adverse events when performed early (<3 months): a nationwide cohort study of newly diagnosed patients with atrial fibrillation. *Thromb Haemost* 2022;**122**:1899–910.
- Kim D, Yang PS, You SC, Jang E, Yu HT, Kim TH et al. Comparative effectiveness of early rhythm control versus rate control for cardiovascular outcomes in patients with atrial fibrillation. *J Am Heart Assoc* 2021;**10**:e023055.
- Lee HJ, Lee SR, Choi EK, Park SH, Chung JW, Choi JM et al. Risk of dementia after smoking cessation in patients with newly diagnosed atrial fibrillation. *JAMA Netw Open* 2022;**5**:e2217132.
- Park S, Lee S, Choi E, Lee H, Chung J, Choi J et al. Low risk of dementia in patients with newly diagnosed atrial fibrillation and a clustering of healthy lifestyle behaviors: a nationwide population-based cohort study. *J Am Heart Assoc* 2022;**11**:e023739.
- Lim J, Lee SR, Choi EK, Han KD, Jung JH, Ahn HJ et al. Exercise and the risk of dementia in patients with newly diagnosed atrial fibrillation: a nationwide population-based study. *J Clin Med* 2021;**10**:3126.
- Jung H, Yang PS, Kim D, Jang E, Yu HT, Kim TH et al. Associations of hypertension burden on subsequent dementia: a population-based cohort study. *Sci Rep* 2021;**11**:12291.
- Martinek M, Sigmund E, Lemes C, Derndorfer M, Aichinger J, Winter S et al. Asymptomatic cerebral lesions during pulmonary vein isolation under uninterrupted oral anticoagulation. *Europace* 2013;**15**:325–31.
- Gaita F, Caponi D, Pianelli M, Scaglione M, Toso E, Cesarani F et al. Radiofrequency catheter ablation of atrial fibrillation: a cause of silent thromboembolism? Magnetic resonance imaging assessment of cerebral thromboembolism in patients undergoing ablation of atrial fibrillation. *Circulation* 2010;**122**:1667–73.
- Wazni OM, Rossillo A, Marrouche NF, Saad EB, Martin DO, Bhargava M et al. Embolic events and char formation during pulmonary vein isolation in patients with atrial fibrillation: impact of different anticoagulation regimens and importance of intracardiac echo imaging. *J Cardiovasc Electrophysiol* 2005;**16**:576–81.
- Ren JF, Marchlinski FE, Callans DJ, Gerstenfeld EP, Dixit S, Lin D et al. Increased intensity of anticoagulation may reduce risk of thrombus during atrial fibrillation ablation procedures in patients with spontaneous echo contrast. *J Cardiovasc Electrophysiol* 2005;**16**:474–7.

28. di Biase L, Burkhardt JD, Santangeli P, Mohanty P, Sanchez JE, Horton R et al. Peri-procedural stroke and bleeding complications in patients undergoing catheter ablation of atrial fibrillation with different anticoagulation management: results from the role of coumadin in preventing thromboembolism in atrial fibrillation (AF) patient. *Circulation* 2014;**129**:2638–44.
29. Petzl A, Derndorfer M, Kollias G, Moroka K, Aichinger J, Pürerfellner H et al. Cerebral thromboembolic risk in atrial fibrillation ablation: a direct comparison of vitamin K antagonists versus non-vitamin K-dependent oral anticoagulants. *J Interv Card Electrophysiol* 2021;**60**:147–54.
30. Ichiki H, Oketani N, Ishida S, Iriki Y, Okui H, Maenosono R et al. The incidence of asymptomatic cerebral microthromboembolism after atrial fibrillation ablation: comparison of warfarin and dabigatran. *Pacing Clin Electrophysiol* 2013;**36**:1328–35.
31. Kirchhof P, Haeusler KG, Blank B, de Bono J, Callans D, Elvan A et al. Apixaban in patients at risk of stroke undergoing atrial fibrillation ablation. *Eur Heart J* 2018;**39**:2942–55.
32. Brockmeyer M, Lin Y, Parco C, Karathanos A, Krieger T, Schulze V et al. Uninterrupted anticoagulation during catheter ablation for atrial fibrillation: no difference in major bleeding and stroke between direct oral anticoagulants and vitamin K antagonists in an updated meta-analysis of randomised controlled trials. *Acta Cardiol* 2021;**76**:288–95.
33. Kaseno K, Naito S, Nakamura K, Sakamoto T, Sasaki T, Tsukada N et al. Efficacy and safety of periprocedural dabigatran in patients undergoing catheter ablation of atrial fibrillation. *Circ J* 2012;**76**:2337–42.
34. Cappato R, Marchlinski FE, Hohnloser SH, Naccarelli GV, Xiang J, Wilber DJ et al. Uninterrupted rivaroxaban vs. uninterrupted vitamin K antagonists for catheter ablation in non-valvular atrial fibrillation. *Eur Heart J* 2015;**36**:1805–11.
35. Hohnloser SH, Camm J, Cappato R, Diener HC, Heidbüchel H, Mont L et al. Uninterrupted edoxaban vs. vitamin K antagonists for ablation of atrial fibrillation: the ELIMINATE-AF trial. *Eur Heart J* 2019;**40**:3013–21.
36. Romero J, Cerrud-Rodríguez RC, Diaz JC, Michaud GF, Taveras J, Alviz I et al. Uninterrupted direct oral anticoagulants vs. uninterrupted vitamin K antagonists during catheter ablation of non-valvular atrial fibrillation: a systematic review and meta-analysis of randomized controlled trials. *Europace* 2018;**20**:1612–20.
37. Wu S, Min Yang Y, Zhu J, Bin Wan H, Wang J, Zhang H et al. Meta-analysis of efficacy and safety of new oral anticoagulants compared with uninterrupted vitamin K antagonists in patients undergoing catheter ablation for atrial fibrillation. *Am J Cardiol* 2016;**117**:926–34.
38. Konduru SV, Cheema AA, Jones P, Li Y, Ramza B, Wimmer AP. Differences in intraprocedural ACTs with standardized heparin dosing during catheter ablation for atrial fibrillation in patients treated with dabigatran vs. patients on uninterrupted warfarin. *J Interv Card Electrophysiol* 2012;**35**:277–84; discussion 284.
39. Snipelisky D, Kauffman C, Prussak K, Johns G, Venkatachalam K, Kusumoto F. A comparison of bleeding complications post-ablation between warfarin and dabigatran. *J Interv Card Electrophysiol* 2012;**35**:29–33.
40. di Biase L, Gaita F, Toso E, Santangeli P, Mohanty P, Rutledge N et al. Does periprocedural anticoagulation management of atrial fibrillation affect the prevalence of silent thromboembolic lesion detected by diffusion cerebral magnetic resonance imaging in patients undergoing radiofrequency atrial fibrillation ablation with o. *Heart Rhythm* 2014;**11**:791–8.
41. Nagy-Baló E, Tint D, Clemens M, Beke I, Kovács KR, Csiba L et al. Transcranial measurement of cerebral microembolic signals during pulmonary vein isolation: a comparison of two ablation techniques. *Circ Arrhythm Electrophysiol* 2013;**6**:473–80.
42. Liu G, Chen R, Zhu W, Cheng K, Xu Y, Chen Q et al. Influence of cardioversion on asymptomatic cerebral lesions following atrial fibrillation ablation. *J Interv Card Electrophysiol* 2014;**40**:129–36.
43. Pianelli M, Scaglione M, Anselmino M, Caponi D, Garcia P, Cesarani F et al. Delaying cardioversion following 4-week anticoagulation in case of persistent atrial fibrillation after a transcatheter ablation procedure to reduce silent cerebral thromboembolism: a single-center pilot study. *J Cardiovasc Med (Hagerstown)* 2011;**12**:785–9.
44. Miyazaki S, Kajiyama T, Yamao K, Hada M, Yamaguchi M, Nakamura H et al. Silent cerebral events/lesions after second-generation cryoballoon ablation: how can we reduce the risk of silent strokes? *Heart Rhythm* 2019;**16**:41–8.
45. Miyazaki S, Watanabe T, Kajiyama T, Iwasawa J, Ichijo S, Nakamura H et al. Thromboembolic risks of the procedural process in second-generation cryoballoon ablation procedures: analysis from real-time transcranial Doppler monitoring. *Circ Arrhythm Electrophysiol* 2017;**10**:e005612.
46. Kuck KH, Brugada J, Fünkrantz A, Metzner A, Ouyang F, Chun KRJ et al. Cryoballoon or radiofrequency ablation for paroxysmal atrial fibrillation. *N Engl J Med* 2016;**374**:2235–45.
47. Andrade JG, Champagne J, Dubuc M, Deyell MW, Verma A, Macle L et al. Cryoballoon or radiofrequency ablation for atrial fibrillation assessed by continuous monitoring: a randomized clinical trial. *Circulation* 2019;**140**:1779–88.
48. Sauren LD, van Belle Y, de Roy L, Pison L, la Meir M, van der Veen FH et al. Transcranial measurement of cerebral microembolic signals during endocardial pulmonary vein isolation: comparison of three different ablation techniques. *J Cardiovasc Electrophysiol* 2009;**20**:1102–7.
49. Healey JS, Nair GM. Does catheter ablation for atrial fibrillation increase or reduce neurological insult? *Curr Opin Cardiol* 2012;**27**:36–40.
50. von Oeveren W, Crijns HJ, Korteling BJ, Wegereef EW, Haan J, Tjchelaar I et al. Blood damage, platelet and clotting activation during application of radiofrequency or cryoablation catheters: a comparative in vitro study. *J Med Eng Technol* 1999;**23**:20–5.
51. Neumann T, Kuniss M, Conradi G, Janin S, Berkowitsch A, Wojcik M et al. MEDAFI-trial (micro-embolization during ablation of atrial fibrillation): comparison of pulmonary vein isolation using cryoballoon technique vs. radiofrequency energy. *Europace* 2011;**13**:37–44.
52. Schmidt B, Gunawardene M, Krieg D, Bordignon S, Fünkrantz A, Kulikoglu M et al. A prospective randomized single-center study on the risk of asymptomatic cerebral lesions comparing irrigated radiofrequency current ablation with the cryoballoon and the laser balloon. *J Cardiovasc Electrophysiol* 2013;**24**:869–74.
53. Herrera Siklody C, Deneke T, Hocini M, Lehmann H, Shin DI, Miyazaki S et al. Incidence of asymptomatic intracranial embolic events after pulmonary vein isolation: comparison of different atrial fibrillation ablation technologies in a multicenter study. *J Am Coll Cardiol* 2011;**58**:681–8.
54. Gaita F, Leclercq JF, Schumacher B, Scaglione M, Toso E, Halimi F et al. Incidence of silent cerebral thromboembolic lesions after atrial fibrillation ablation may change according to technology used: comparison of irrigated radiofrequency, multipolar nonirrigated catheter and cryoballoon. *J Cardiovasc Electrophysiol* 2011;**22**:961–8.
55. Gujjian L, Wenqing Z, Xinggang W, Ying Y, Minghui L, Yeqing X et al. Association between ablation technology and asymptomatic cerebral injury following atrial fibrillation ablation. *Pacing Clin Electrophysiol* 2014;**37**:1378–91.
56. Wasmer K, Foraita P, Leitz P, Güner F, Pott C, Lange PS et al. Safety profile of multielectrode-phased radiofrequency pulmonary vein ablation catheter and irrigated radiofrequency catheter. *Europace* 2016;**18**:78–84.
57. Deneke T, Schade A, Müller P, Schmitt R, Christophoulos G, Krug J et al. Acute safety and efficacy of a novel multipolar irrigated radiofrequency ablation catheter for pulmonary vein isolation. *J Cardiovasc Electrophysiol* 2014;**25**:339–45.
58. Wiczorek M, Hoeltgen R, Brueck M. Does the number of simultaneously activated electrodes during phased RF multielectrode ablation of atrial fibrillation influence the incidence of silent cerebral microembolism? *Heart Rhythm* 2013;**10**:953–9.
59. Verma A, Debruyne P, Nardi S, Deneke T, DeGreef Y, Spitzer S et al. Evaluation and reduction of asymptomatic cerebral embolism in ablation of atrial fibrillation, but high prevalence of chronic silent infarction: results of the evaluation of reduction of asymptomatic cerebral embolism trial. *Circ Arrhythm Electrophysiol* 2013;**6**:835–42.
60. Zellerhoff S, Ritter MA, Kochhäuser S, Ditttrich R, Köbe J, Milberg P et al. Modified phased radiofrequency ablation of atrial fibrillation reduces the number of cerebral microembolic signals. *Europace* 2014;**16**:341–6.
61. Wissner E, Metzner A, Neuzil P, Petru J, Skoda J, Sediva L et al. Asymptomatic brain lesions following laserballoon-based pulmonary vein isolation. *Europace* 2014;**16**:214–9.
62. Deneke T, Nentwich K, Schmitt R, Christophoulos G, Krug J, di Biase L et al. Exchanging catheters over a single transseptal sheath during left atrial ablation is associated with a higher risk for silent cerebral events. *Indian Pacing Electrophysiol J* 2014;**14**:240–9.
63. Yokoyama M, Tokuda M, Tokutake K, Sato H, Oseto H, Yokoyama K et al. Effect of air removal with extracorporeal balloon inflation on incidence of asymptomatic cerebral embolism during cryoballoon ablation of atrial fibrillation: a prospective randomized study. *Int J Cardiol Heart Vasc* 2022;**40**:101020.
64. Park YJ, Yu HT, Kim T, Uhm J, Joung B, Lee M et al. Effectiveness and safety of single transseptal ablation for atrial fibrillation in real-world practice. *Clin Cardiol* 2021;**44**:547–54.
65. Chin SH, O'Brien J, Epicoco G, Peddinti P, Gupta A, Modi S et al. The feasibility and effectiveness of a streamlined single-catheter approach for radiofrequency atrial fibrillation ablation. *J Arrhythm* 2020;**36**:685–91.
66. Badertscher P, Knecht S, Spies F, Völlmin G, Schaer B, Schärli N et al. High-power short-duration ablation index-guided pulmonary vein isolation protocol using a single catheter. *J Interv Card Electrophysiol* 2022;**65**:633–42.
67. Pambrun T, Combes S, Sousa P, Le Bloa M, El Bouazzaoui R, Grand-Larrieu D et al. Contact-force guided single-catheter approach for pulmonary vein isolation: feasibility, outcomes, and cost-effectiveness. *Heart Rhythm* 2017;**14**:331–8.
68. Reddy VY, Grimaldi M, de Potter T, Vijgen JM, Bulava A, Duytschaever MF et al. Pulmonary vein isolation with very high power, short duration, temperature-controlled lesions: the QDOT-FAST trial. *JACC Clin Electrophysiol* 2019;**5**:778–86.
69. Halbfass P, Wielandts JY, Knecht S, le Polain de Waroux JB, Tavernier R, de Wilde V et al. Safety of very high-power short-duration radiofrequency ablation for pulmonary vein isolation: a two-centre report with emphasis on silent oesophageal injury. *Europace* 2022;**24**:400–5.
70. Mueller J, Halbfass P, Sonne K, Nentwich K, Ene E, Berkovitz A et al. Safety aspects of very high power very short duration atrial fibrillation ablation using a modified radiofrequency RF-generator: single-center experience. *J Cardiovasc Electrophysiol* 2022;**33**:920–7.
71. Neven K, Fütting A, Byrd I, Heil RW, Fish JM, Feeney DA et al. Absence of (sub-)acute cerebral events or lesions after electroporation ablation in the left-sided canine heart. *Heart Rhythm* 2021;**18**:1004–11.

72. Reddy VY, Dukkipati SR, Neuzil P, Anic A, Petru J, Funasako M et al. Pulsed field ablation of paroxysmal atrial fibrillation: 1-year outcomes of IMPULSE, PEFCAT, and PEFCAT II. *JACC Clin Electrophysiol* 2021;**7**:614–27.
73. Ekanem E, Reddy VY, Schmidt B, Reichlin T, Neven K, Metzner A et al. Multi-national survey on the methods, efficacy, and safety on the post-approval clinical use of pulsed field ablation (MANIFEST-PF). *Europace* 2022;**24**:1256–66.
74. Reinsch N, Fütting A, Höwel D, Bell J, Lin Y, Neven K. Cerebral safety after pulsed field ablation for paroxysmal atrial fibrillation. *Heart Rhythm* 2022;**19**:1813–8.
75. Vermeer SE, Prins ND, den Heijer T, Hofman A, Koudstaal PJ, Breteler MMB. Silent brain infarcts and the risk of dementia and cognitive decline. *N Engl J Med* 2003;**348**:1215–22.
76. Schwarz N, Kuniss M, Nedelmann M, Kaps M, Bachmann G, Neumann T et al. Neuropsychological decline after catheter ablation of atrial fibrillation. *Heart Rhythm* 2010;**7**:1761–7.
77. Zhang J, Xia SJ, Du X, Jiang C, Lai YW, Wang YF et al. Incidence and risk factors of post-operative cognitive decline after ablation for atrial fibrillation. *BMC Cardiovasc Disord* 2021;**21**:341.
78. Medi C, Evered L, Silbert B, Teh A, Halloran K, Morton J et al. Subtle post-procedural cognitive dysfunction after atrial fibrillation ablation. *J Am Coll Cardiol* 2013;**62**:531–9.
79. Herm J, Fiebach JB, Koch L, Kopp UA, Kunze C, Wollboldt C et al. Neuropsychological effects of MRI-detected brain lesions after left atrial catheter ablation for atrial fibrillation: long-term results of the MACPAF study. *Circ Arrhythm Electrophysiol* 2013;**6**:843–50.
80. Deneke T, Shin DI, Balta O, Bünz K, Fassbender F, Mügge A et al. Postablation asymptomatic cerebral lesions: long-term follow-up using magnetic resonance imaging. *Heart Rhythm* 2011;**8**:1705–11.
81. Häusler KG, Eichner FA, Heuschmann PU, Fiebach JB, Engelhorn T, Blank B et al. MRI-detected brain lesions and cognitive function in atrial fibrillation patients undergoing left atrial catheter ablation in the randomized AXAFA-AFNET 5 trial. *Circulation* 2022;**145**:906–15.
82. Wang X, Wang Z, Yan X, Huang M, Wu Y. Radiofrequency and cryoballoon ablation improve cognitive function in patients with atrial fibrillation. *Medicine (Baltimore)* 2021;**100**:e26914.
83. Kato N, Muraga K, Hirata Y, Shindo A, Matsuura K, li Y et al. Brain magnetic resonance imaging and cognitive alterations after ablation in patients with atrial fibrillation. *Sci Rep* 2021;**11**:18995.
84. Schrickel JW, Lickfett L, Lewalter T, Mittman-Braun E, Selbach S, Strach K et al. Incidence and predictors of silent cerebral embolism during pulmonary vein catheter ablation for atrial fibrillation. *Europace* 2010;**12**:52–7.
85. Cha MJ, Park HE, Lee MH, Cho Y, Choi EK, Oh S. Prevalence of and risk factors for silent ischemic stroke in patients with atrial fibrillation as determined by brain magnetic resonance imaging. *Am J Cardiol* 2014;**113**:655–61.
86. Lipnicki DM, Makkar SR, Crawford JD, Thalamuthu A, Kochan NA, Lima-Costa MF et al. Determinants of cognitive performance and decline in 20 diverse ethno-regional groups: a COSMIC collaboration cohort study. *PLoS Med* 2019;**16**:e1002853.
87. Yu Y, Wang X, Li X, Zhou X, Liao S, Yang W et al. Higher incidence of asymptomatic cerebral emboli after atrial fibrillation ablation found with high-resolution diffusion-weighted magnetic resonance imaging. *Circ Arrhythm Electrophysiol* 2020;**13**:e007548.
88. Goertler M, Baeumer M, Kross R, Blaser T, Lutze G, Jost S et al. Rapid decline of cerebral microemboli of arterial origin after intravenous acetylsalicylic acid. *Stroke* 1999;**30**:66–9.