



AALBORG UNIVERSITY
DENMARK

Aalborg Universitet

Frequency of superscan on bone scintigraphy

A systematic review

Kovacsne, Adrienn; Kozon, Isabella; Bentestuen, Morten; Zacho, Helle D.

Published in:
Clinical Physiology and Functional Imaging

DOI (link to publication from Publisher):
[10.1111/cpf.12821](https://doi.org/10.1111/cpf.12821)

Creative Commons License
CC BY-NC 4.0

Publication date:
2023

Document Version
Publisher's PDF, also known as Version of record

[Link to publication from Aalborg University](#)

Citation for published version (APA):
Kovacsne, A., Kozon, I., Bentestuen, M., & Zacho, H. D. (2023). Frequency of superscan on bone scintigraphy: A systematic review. *Clinical Physiology and Functional Imaging*, 43(5), 297-304. Advance online publication. <https://doi.org/10.1111/cpf.12821>

General rights

Copyright and moral rights for the publications made accessible in the public portal are retained by the authors and/or other copyright owners and it is a condition of accessing publications that users recognise and abide by the legal requirements associated with these rights.

- Users may download and print one copy of any publication from the public portal for the purpose of private study or research.
- You may not further distribute the material or use it for any profit-making activity or commercial gain
- You may freely distribute the URL identifying the publication in the public portal -

Take down policy

If you believe that this document breaches copyright please contact us at vbn@aub.aau.dk providing details, and we will remove access to the work immediately and investigate your claim.

Frequency of superscan on bone scintigraphy: A systematic review

Adrienn Kovacsne¹  | Isabella Kozon¹ | Morten Bentestuen¹ | Helle D. Zacho^{1,2} 

¹Department of Nuclear Medicine, Aalborg University Hospital, Aalborg, Denmark

²Department of Clinical Medicine, Aalborg University, Aalborg, Denmark

Correspondence

Adrienn Kovacsne, Department of Nuclear Medicine, Aalborg University Hospital, Hobrovej 18-22, Postboks 365, DK-9100 Aalborg, Denmark.
Email: a.kovacsne@rn.dk

Abstract

Introduction: Bone scintigraphy (BS) is an important tool for detecting bone metastasis. BS with diffuse increased skeletal radioisotope uptake with absent or faint urinary tract and soft tissue activity is defined as a superscan. In this review, we investigate the different etiologies causing superscan and the reported frequency of superscan among different disease entities.

Materials and Methods: The search terms were 'bone' AND 'superscan' OR 'superscan' in the PubMed database from 1980 to November 2020. Eligibility criteria included the following: Peer-reviewed studies containing original data using ^{99m}Tc-phosphate-analogue BS reporting a superscan pattern. Unretrievable papers, imaging modalities other than BS or with insufficient information to assess the aetiology were excluded. The abstracts of every paper and full texts of potentially eligible papers were assessed independently by three observers.

Results: Sixty-seven papers were included (48 case reports and 19 cohort studies). Studies conducted in patients with osteomalacia or skeletal fluorosis revealed superscan in all patients. Other benign causes of superscan were hyperparathyroidism and kidney disease. Among papers with malignant cause, prostate cancer was the most common cause, followed by gastric cancer. The frequency of superscans ranged from 1.3% in a cohort of mixed cancer types up to 2.6% in patients with gastric cancer and up to 23% in a cohort of prostate cancer patients.

Conclusion: Superscan is most frequently seen in prostate cancer, but numerous other cancers and metabolic bone diseases can cause superscan, which should be kept in mind when encountering an unexpected superscan on BS.

KEYWORDS

benign, bone scintigraphy, cancer, metabolic bone disease, superscan

This is an open access article under the terms of the Creative Commons Attribution-NonCommercial License, which permits use, distribution and reproduction in any medium, provided the original work is properly cited and is not used for commercial purposes.

© 2023 The Authors. *Clinical Physiology and Functional Imaging* published by John Wiley & Sons Ltd on behalf of Scandinavian Society of Clinical Physiology and Nuclear Medicine.

1 | INTRODUCTION

Bone metastases develop when cancer cells spread from their original site to the bone. Nearly all types of cancer can metastasize to the bones, but some types of cancer are particularly prone to metastasize to bone, for example, prostate cancer, breast cancer and renal cancer (Huang et al., 2020).

Bone scintigraphy (BS) is a nuclear imaging technique that uses (99 m) Tc-labelled diphosphonate (methylene-, hydroxydiphosphonate-, dicarboxypropane diphosphonate) to evaluate the distribution of active bone formation caused by osteoblast activity. Increased uptake on BS may be caused by malignancy, including both primary tumours and metastatic deposits. Likewise, several benign conditions may cause increased osteoblastic activity, such as healing fractures, osteoarthritis and infection (Brenner et al., 2012). In addition, certain metabolic disorders may also cause a generalized increase in bone turnover (Manohar et al., 2017). This can be seen for example, in patients with hyperthyroid disease showing abnormal bone metabolism as part of their generalized hypermetabolic status (Kotb et al., 2007). Due to its satisfactory diagnostic characteristics, BS is often used to assess the entire skeleton for the presence of metastatic disease, particularly in cancers prone to causing osteoblast activity when metastasizing to bones, such as prostate cancer and breast cancer (van den Bergh et al., 2021). In addition, BS is widely available, relatively inexpensive and a robust technique.

In some disease entities, BS may present with markedly uniform markedly increased tracer uptake in the axial skeleton, pelvic bones and proximal limbs, with concomitant faint uptake in the soft tissues and faint to absent genitourinary tract activity. This BS pattern is defined as a 'superscan' (Brenner et al., 2012; Constable & Cranage, 1981; Sy et al., 1975). The 'superscan' and 'reduced kidneys sign' was first described by Osmond et al. (1975). The causes of a superscan can vary widely, from metastatic cancer to metabolic bone disease or haematologic disease (Stadlnik et al., 1984). Prostate cancer is considered the most common cause of superscans among cancers (Hawkins & Halewood, 2008); however, superscans may also be caused by a variety of different cancers or benign diseases.

The aim of our study was to conduct a review of the underlying diseases causing superscan on BS and explore the reported frequency of superscan within different disease entities.

2 | METHODS

2.1 | Search strategy and eligibility criteria

The PubMed database was searched for relevant articles. The search terms were 'bone' AND 'superscan' OR 'superscan', and the search period spanned from 1980 to 12 November 2020.

The predefined inclusion criteria were as follows: (1) Peer-reviewed published studies containing original data in English,

- (2) Studies performing 99mTc-phosphate-analogue bone scans and
- (3) Studies reporting superscan patterns on bone scans.

Papers were excluded if they: (1) Were not retrievable within 30 days from an international medical library, (2) Referred to 'superscan' on an imaging modality other than 99mTc BS, or (3) Reported insufficient information for inclusion. The term 'insufficient information' was used where studies in general lacked follow-up/pathology, the number of cases did not add up, they used unconventional tracers for assessment of the skeletal system for example, 99m Tc-phosphate pentavalent dimercaptosuccinic acid (99mTc(V)-DMSA) which was used in three studies. Superscans in all studies were identified according to the criteria as a uniform, symmetric increased uptake of radiopharmaceutical in the skeleton with little or no renal visualization and a high ratio of bone to soft-tissue activity.

2.2 | Study selection

The title and abstract were assessed independently by three readers (A. K., I. K., M. B.), and the full text was retrieved for potentially eligible papers. Papers were excluded if there was consensus that the paper did not fulfil the eligibility criteria based on the abstract alone. If doubt existed that the paper might be eligible, the full text was retrieved. The full text from all potentially eligible papers was evaluated according to the eligibility criteria by the same three observers (A. K., I. K., M. B.). In cases of disagreement, a fourth investigator was involved in the discussion (H. Z.).

2.3 | Data extraction and data synthesis

The following data were extracted from the included studies: first author, year, title, country, number of superscans, incidence of superscans, study design, pathology or known disease and total number of included study subjects.

The papers were then sorted into papers investigating benign causes of superscans, papers reporting malignancy as a cause of superscans, and finally, papers with superscans in patients with both malignant and benign diseases that may cause superscans.

2.4 | Assessment of bias and quality of evidence

From a preliminary search using the word 'superscan', we found that the vast majority of potentially eligible studies were case reports and few cohort studies. Consequently, we did not perform a thorough assessment of the risk of bias. The quality of evidence assessment was conducted based on the Oxford University Centre for Evidence-based medicine grading of diagnostic trials (<http://www.cebm.net/>). Due to these limitations and lack of high-quality data, the findings in our review are presented as descriptive, as no proper meta-analysis was feasible.

3 | RESULTS

3.1 | Study selection and level of evidence

Our search identified a total of 162 papers. The main reasons for exclusion were insufficient data ($n = 3$) and studies using other tracers than ^{99m}Tc bisphosphonates ($n = 3$). A total of 67 papers met the eligibility criteria and were included in the review, as depicted in PRISMA flowchart (Figure 1). Among the 67 selected papers, 19 papers were cohort studies, and 48 papers were case reports. According to the Oxford Centre of Evidence Based Medicine, no high evidence papers were included. Ten papers were level 3, and the remaining 57 papers were level 4.

3.2 | Cohort studies with malignancy

A total of 13 cohort studies examining and reporting the presence of superscan in patients with cancer were included in the review. One study by Manohar et al. (2017) examined the presence of superscan in a general population with cancer undergoing BS and four studies evaluated the frequency of superscan among patients diagnosed with a specific cancer type (Choi et al., 1995; Liu et al., 1996; Shih et al., 1991; Simsek et al., 2020) The study by Manohar et al. included both retrospective and prospective data from a population of 6027

patients undergoing BS. overall, 80 cases of superscans were encountered corresponding to an frequency of 1.3% of all BS performed (Manohar et al., 2017). Prostate cancer (adenocarcinoma) was the most common disease (15%, 46/307) presenting with superscans, followed by ductal breast carcinoma ($n = 10$) and lung cancer ($n = 9$). Several other cancer types were also diagnosed as the cause of superscans, including bladder cancer (Table 1 and Figure 2).

In a retrospective study of 407 nasopharyngeal cancer patients, the incidence of superscans was 1.5% (Liu et al., 1996). Similarly, a retrospective study investigated the incidence of superscans in stomach cancer patients, and superscans were seen in 6 out of 234 patients, corresponding to a frequency of 2.6% (Choi et al., 1995).

One study evaluated the relationship between Gleason score (GS) and Tc-99 m HMDP bone scans in patients with prostate cancer, showing that superscans and extensive metastases only occurred in patients with high GS >6 , thus superscan was seen in 11 of the 32 men with high GS, whereas, no superscan pattern was seen among the 16 men with low GS (Shih et al., 1991). Another study in prostate cancer patients revealed that 23/138 (16.7%) patients had a superscan pattern on BS (Simsek et al., 2020).

It is a known phenomenon that the homogeneity of tracer accumulation in superscans may lead to a false negative interpretation as illustrated in Figure 2 (Constable & Cranage, 1981). The aim of six studies was to investigate different tools to reduce the risk of false interpretation of bone scans with a superscan appearance and

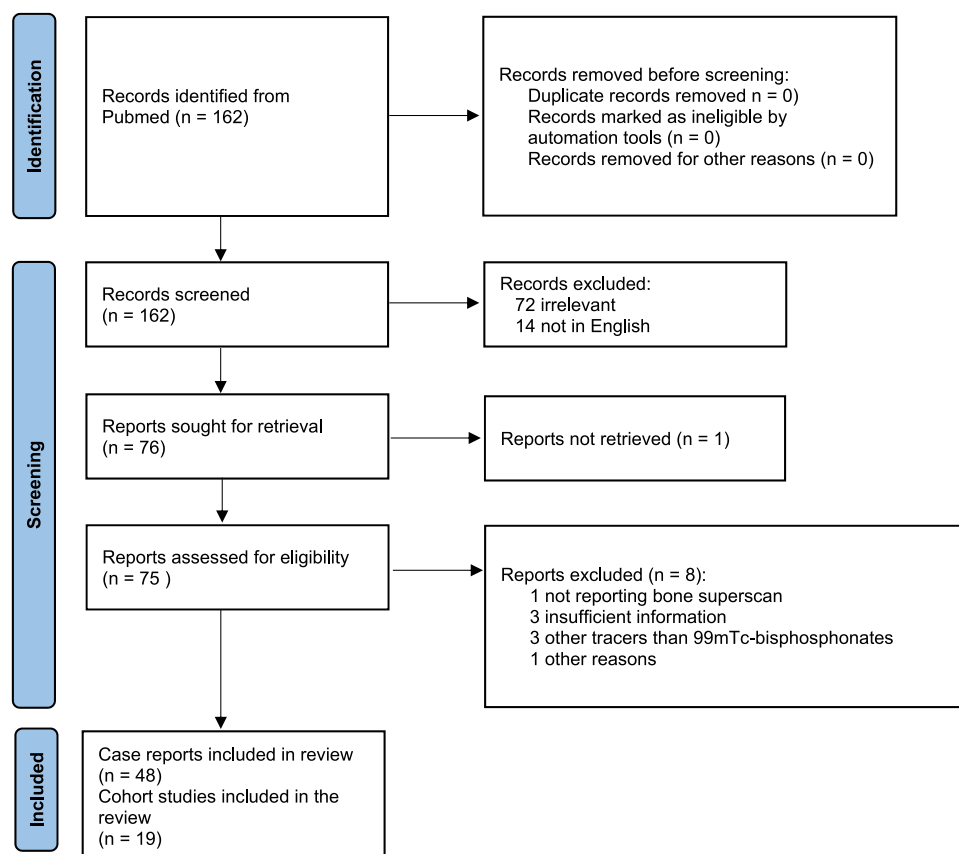


FIGURE 1 Selection process.

TABLE 1 Cohort studies—malignancy.

| Year | Author | Country | Number of patients | Tumour type with superscan, n | Incidence in % |
|--|-----------------|----------------|--------------------|---|----------------|
| 2017 | P. R. Manohar | India | 6027 | Superscan, all types of cancer, n = 80 Prostate cancer, n = 46 Breast cancer, n = 10 Lung cancer, n = 9 Gastric cancer, n = 5 Bladder cancer, n = 4 Thyroid cancer, n = 2 Nasopharynx cancer, n = 1 Oesophageal cancer, n = 1 Minor salivary gland cancer, n = 1 Ewing's sarcoma, n = 1 | 1.3% |
| 1991 | W. J. Shih | USA | 48 | Prostate cancer, n = 11 ^a | 23% |
| 2000 | D. H. Simsek | Turkey | 138 | Prostate cancer, n = 23 | 16.7% |
| 1995 | C. W. Choi | Korea | 234 | Gastric cancer, n = 6 | 2.6% |
| 1996 | R. S. Liu | China | 407 | Nasopharyngeal carcinoma, n = 6 | 1.5% |
| The patients in the following studies have been selected based on their superscan appearance on BS | | | | | |
| 2018 | I. Gayed | USA | 20 | Prostate cancer, n = 3 | |
| 2018 | H. Rathke | Germany | 21 | Prostate cancer, n = 7 | |
| 2011 | L. K. Harshman | USA | 30 | Unknown (2) Myelofibrosis/polycythemia vera, n = 1 Colon cancer, n = 1 Prostate cancer, n = 2 Breast cancer, n = 1 Parathyroid cancer, n = 1 | |
| 2008 | T. Hawkins | United Kingdom | 118 | Prostate cancer, n = 38 | |
| 2001 | P. M. Windsor | United Kingdom | 75 | Prostate cancer, n = 7 | |
| 2000 | D. Yuksel | Turkey | 9 | Parathyroid adenocarcinoma, n = 4 Prostate cancer, n = 3 Nasopharynx adenocarcinoma, n = 1 Gastric adenocarcinoma, n = 1 | |
| 1994 | L. Berna | Spain | 1200 | Breast, n = 7 Prostate cancer, n = 3 | |
| 1980 | A. R. Constable | United Kingdom | 539 | Prostate cancer, n = 22 | |

Abbreviation: BS, bone scintigraphy.

^aEleven patients showed metastases with superscan patterns and/or extensive metastases.

to evaluate other imaging modalities among cancer patients (Berná et al., 1994; Constable & Cranage, 1981; Harshman et al., 2011; Hawkins & Halewood, 2008; Rathke et al., 2018; Yuksel et al., 2000). These studies were conducted in highly selected populations and therefore are not representative for evaluation of the incidence. Many different cancer types were included in these studies; however, prostate cancer was the most common cause of superscans (Table 1). The remaining two studies examined treatment with Ra-223 dichloride and strontium-89 therapy among prostate cancer patients with bone metastases, and although these are not suitable for

indicating the incidence, they showed an unfavourable response and poor prognosis among patients with superscans (Gayed et al., 2018; Windsor, 2001).

3.3 | Cohort studies with nonmalignant diseases

Our search revealed six studies reporting superscans in nonmalignant diseases as detailed in Table 2 (Al-Jurayyan et al., 2002; El-Desouki & Al-Jurayyan, 1997; El-Desouki et al., 2004; Gupta et al., 1993; Kim

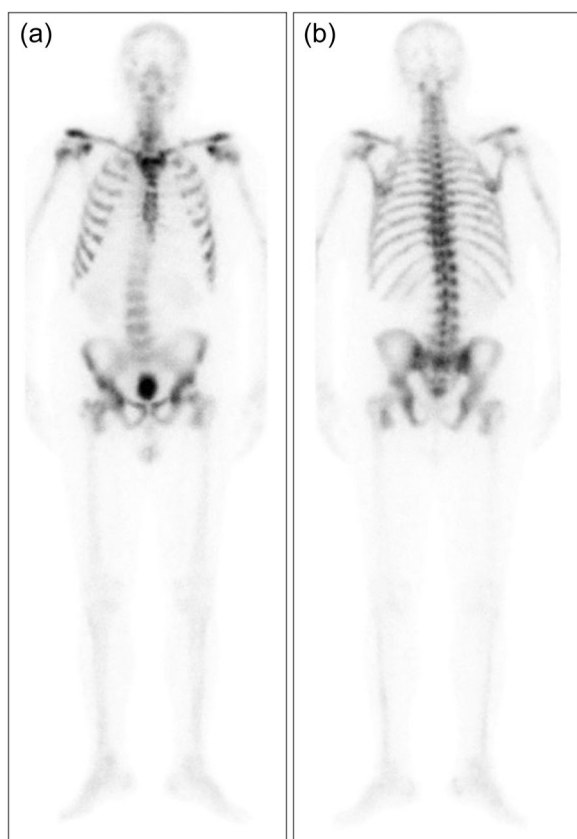

FIGURE 2 A 69-year-old man with high-risk prostate cancer and no bone metastases at primary staging was treated with peripheral androgen blockade. Shortly after, the patient was diagnosed with noninvasive urothelial tumour with high malignancy from a bladder polyp. One year later a bone scintigraphy in anterior view (a) and posterior view (b) revealed widespread skeletal metastasis—superscan, which can be easily misinterpreted as normal scanning. Biopsy from the iliac bone revealed metastases from the urothelial carcinoma.

et al., 1998; Kotb et al., 2007). One prospective study examined the presence of metabolic superscans in association with hypermetabolic status in various groups of hyperthyroidisms and found an incidence of metabolic superscans of 90% in patients with Graves' disease (27 patients out of 30), whereas the incidence of superscans was only 2 out of 10 patients (20%) in toxic nodular goitre patients. Superscans were not encountered among the 5 patients with autonomous toxic adenoma (0/5, 0%) (Kotb et al., 2007). In addition, a reasonable correlation was found between thyroid uptake on thyroid scintigraphy and superscan features in Graves' patients, but no correlation was shown between thyroid stimulating hormone, thyroxine and tri-iodothyronine levels and superscan features (Kotb et al., 2007).

Three prospective studies conducted in the Kingdom of Saudi Arabia examined a total of 164 patients (both children and adults) with nutritional rickets and osteomalacia to assess the usefulness of bone mineral density and BS. BS revealed superscans in all patients (164/164 patients, 100%) at the time of diagnosis (Al-Jurayyan et al., 2002; El-Desouki & Al-Jurayyan, 1997; El-Desouki et al., 2004). Similarly, a study from India showed that chronic environmental fluoride intoxication induced increased bone turnover in the whole skeleton, resulting in a superscan pattern in all patients (17/17, 100%). This study was conducted in a population diagnosed with osteodystrophy and thus was not representative for evaluating the incidence of superscans (Gupta et al., 1993).

3.4 | Case reports

A total of 48 case reports were included, reporting 54 patients. In 34 case reports, malignancy was the cause of the superscan, and prostate cancer ($n = 15$) was the most common cause, followed by gastric cancer ($n = 10$). Other less common cancers that caused superscans included metastatic pheochromocytoma (Tan et al., 2015),

TABLE 2 Cohort studies—benign disease.

| Year | Author | Country | Number of patients | Disease with superscan, n | Incidence in % |
|---|-------------------|-------------------------|--------------------|-------------------------------------|----------------------------|
| 1993 | S. K. Gupta | India | 17 | Skeletal fluorosis, $n = 17$ | 100% |
| 1997 | M. I. El-Desouki | Kingdom of Saudi Arabia | 26 | Osteomalacia, $n = 26$ | 100% |
| 2002 | N. A. Al-Jurayyan | Kingdom of Saudi Arabia | 42 | Osteomalacia and rickets, $n = 26$ | 100% (26/26 ^a) |
| 2004 | M. I. El-Desouki | Kingdom of Saudi Arabia | 96 | Osteomalacia, $n = 96$ | 100% |
| 2007 | M. H. Kotb | United Kingdom | 45 | Hyperthyroidism | |
| | | | - $n = 30$ | - Graves' disease, $n = 27$ | - 90% |
| | | | - $n = 10$ | - Toxic nodular goitre, $n = 2$ | - 20% |
| | | | - $n = 5$ | - Autonomous toxic adenoma, $n = 0$ | - - |
| The patients in the following studie have been selected based on their superscan appearance on BS | | | | | |
| 1998 | Chan-Duck Kim | Korea | 19 | Renal osteodystrophy | |

Abbreviation: BS, bone scintigraphy

^aBS were performed only in 26 patients.

paediatric neuroblastoma (Tripathi et al., 2015), intracranial glioma (Shinya et al., 2007), multiple myeloma (Anscombe & Walkden, 1983) and angiogenic myeloid metaplasia (Pour et al., 2004).

Thirteen case reports presented patients with a nonmalignant cause of superscans. In addition to kidney disease ($n = 2$) (Campeau et al., 1987; Ohashi et al., 1991), hyperparathyroidism ($n = 3$) (Benameur et al., 2017; Gupta et al., 2020; Zanglis et al., 2006) and hyperthyreose ($n = 1$) (Koizumi & Matsumoto, 1998), rare diseases such as Castleman disease (Washington et al., 2010), osteopetrosis (Kim et al., 2001) and systemic mastocytosis presented as superscans (Khoury et al., 2003; Pinto-Lopes et al., 2013).

Finally, 1 case report reported a superscan in 1 patient caused by both renal osteodystrophy and prostate cancer (Liu, 2011).

4 | DISCUSSION

In the present structured review, three cohort studies revealed superscans in 15%–23% of patients with prostate cancer and 1.3%–2.6% among patients with other types of cancer undergoing BS (Choi et al., 1995; Liu et al., 1996; Manohar et al., 2017; Shih et al., 1991; Simsek et al., 2020). In a large study with 6027 patients undergoing BS due to cancer, prostate cancer was the most common cause of superscans, followed by ductal breast carcinoma and lung and gastric cancer (Manohar et al., 2017). Whether this represents a higher frequency of superscans among prostate cancer patients or reflects the fact that patients with prostate cancer are most likely to undergo BS cannot be determined based on the present review. Metastatic superscans in patients with prostate cancer have also been reported combined with other imaging modalities or tracers, such as 68-Ga-PSMA PET/CT, 99m-Tc-PSMA SPECT/CT and 99m Tc (V) DMSA scintigraphy (Rathke et al., 2018; Simsek et al., 2020; Yüksel et al., 2000). A study showed that PSMA scanning provided a clear advantage over bone scanning by reducing the number of equivocal findings in most patients (Rathke et al., 2018).

Due to homogenous tracer accumulation, superscans can sometimes be overlooked. To counter the risk of false negatives, several studies aiming to develop new techniques/methods have been conducted (Hawkins & Halewood, 2008; Yüksel et al., 2000).

Although the superscan pattern on BS is mostly associated with cancer, it is also seen in patients with nonmalignant disease with increased bone turnover. In three studies from Saudi Arabia, all patients with known specific metabolic bone disorders such as nutritional rickets and osteomalacia presented with superscans on BS. In addition to the superscan pattern, the BS provided additional information by demonstrating pseudofractures, disease activity and response to therapy.

Likewise, an increased bone turnover state leading to increased tracer uptake in the appendicular skeleton and a superscan pattern is also seen in chronic environmental fluoride intoxication, renal osteodystrophy and other endocrinological diseases, such as hyperparathyroidism and hyperthyroidism. Chronic kidney disease is

associated with secondary hyperparathyroidism and consequently abnormal mineral metabolism. The decreased kidney function leads to phosphorus retention, hypocalcemia, high PTH production and high osteoblast activity and consequently high uptake of 99mTc-labelled bisphosphonates (de Graaf et al., 1984). Similarly, in patients with hyperthyroidism, an abnormal bone metabolism is seen due to stimulation of bone cells by high levels of circulating thyroid hormones that may be normalized through anti-thyroid treatment (Kotb et al., 2007). In one study, Graves' disease was associated with the highest frequency of a superscan appearance among hyperthyroid patients (Kotb et al., 2007). It is well known that superscans are associated with a poor prognosis among cancer patients, but there is a lack of information on whether superscans are associated with the prognosis among patients with benign disease. An important feature of BS in metabolic diseases is the ability to provide an overview of the entire skeletal system in one (short) investigation and its high sensitivity. When using BS to evaluate patients with metabolic disease, the main value is the detection of both focal and generalized conditions including the ability to detect complications for example, in terms of fractures.

It is important to highlight that the pattern of uptake seen in metastatic disease is diffuse homogenous uptake in the axial skeleton due to the dilation of metastatic disease involving areas where red marrow is abundant. Metabolic superscans are different, with diffuse, homogenous tracer uptake that may involve both the appendicular and the axial skeleton with additional characteristic features, for example, increased uptake by the calvaria, mandible, sternum and costochondral junctions (Abdelrazek et al., 2012).

Our study has several limitations. Firstly, the data is descriptive as no proper meta-analysis is feasible due to the low quality of included studies. Also, the search was only conducted in Pubmed. The majority of included studies were case reports which prevents risk of bias assessment and will most likely skew the results towards rare pathologies. Moreover, some disease entities (e.g., prostate cancer) are more well studied than others, resulting in publication bias. Due to these limitations and lack of high-quality data, the findings in our review are presented as descriptive.

5 | CONCLUSION

Our review revealed metastatic prostate cancer to be the most frequent cause of superscan. Other malignant diseases have also been reported to result in a superscan pattern on BS, for example, lung cancer, breast cancer, gastric cancer, nasopharyngeal cancer and bladder cancer. However, our study also revealed several other nonmalignant conditions to present with superscan on BS, such as nutritional rickets and osteomalacia, Grave's disease, skeletal fluorosis, hyperparathyroidism and kidney disease.

When encountering an unexpected superscan, the interpreter should always take the patient history into account before arriving at a conclusion, and supplementary diagnostics can be suggested as the superscan phenomenon can be seen in several different conditions.

AUTHOR CONTRIBUTIONS

The authors are credited in the presented order of authorship. Adrienn Kovacsne was responsible for the completion of the present project. Adrienn Kovacsne and Helle D. Zacho developed the concept and designed the study. Adrienn Kovacsne, Isabella Kozon and Morten Bentestuen searched the databases, screened the literature and extracted data. Helle D. Zacho was included in cases of disagreement or uncertainty. Drafts were written by Adrienn Kovacsne. All authors (Adrienn Kovacsne, Isabella Kozon, Morten Bentestuen and Helle D. Zacho) revised the drafts, contributed to the final result and approved the final manuscript.

ACKNOWLEDGEMENTS

No external funding has been received. No other individuals or institutions have contributed to the completion of this review.

CONFLICT OF INTEREST STATEMENT

The authors declare no conflict of interest.

DATA AVAILABILITY STATEMENT

The present paper is a systematic review and consequently does not have any original data.

ORCID

Adrienn Kovacsne  <http://orcid.org/0000-0002-1232-1640>

Helle D. Zacho  <http://orcid.org/0000-0001-9089-288X>

REFERENCES

- Abdelrazek, S., Szumowski, P., Rogowski, F., Kociura-Sawicka, A., Mojsak, M. & Szorc, M. (2012) Bone scan in metabolic bone diseases. *Nuclear Medicine Review. Central & Eastern Europe*, 15(2), 124–131.
- Al-Jurayyan, N.A., El-Desouki, M.E., Al-Herbish, A.S., Al-Mazyad, A.S. & Al-Qhtani, M.M. (2002) Nutritional rickets and osteomalacia in school children and adolescents. *Saudi Medical Journal*, 23(2), 182–185.
- Anscombe, A. & Walkden, S.B. (1983) An interesting bone scan in multiple myeloma—? Myeloma superscan. *The British Journal of Radiology*, 56(667), 489–492.
- Benameur, Y., Guerrouj, H., Ghfir, I. & Ben Rais Aouad, N. (2017) Unusual pathological fracture of the clavicle revealing primary hyperparathyroidism: a case report. *Journal of Medical Case Reports*, 11(1), 342.
- Berná, L., Torres, G., Carrió, I., Estorch, M., Germá, J.N. & Alonso, C. (1994) Antigranulocyte antibody bone marrow scans in cancer patients with metastatic bone superscan appearance. *Clinical Nuclear Medicine*, 19(2), 121–128.
- Brenner, A.I., Koshy, J., Morey, J., Lin, C. & DiPoce, J. (2012) The bone scan. *Seminars in Nuclear Medicine*, 42(1), 11–26.
- Campeau, R.J., Bellah, R.D. & Varma, D.G.K. (1987) Pathologic fractures in a patient with renal osteodystrophy. Failure of early detection on bone scans. *Clinical Nuclear Medicine*, 12(7), 510–513.
- Choi, C.W., Lee, D.S., Chung, J.K., Lee, M.C., Kim, N.K. & Choi, K.W. et al. (1995) Evaluation of bone metastases by Tc-99m MDP imaging in patients with stomach cancer. *Clinical Nuclear Medicine*, 20(4), 310–314.
- Constable, A.R. & Cranage, R.W. (1981) Recognition of the superscan in prostatic bone scintigraphy. *The British Journal of Radiology*, 54(638), 122–125.
- El-Desouki, M. & Al-Jurayyan, N. (1997) Bone mineral density and bone scintigraphy in children and adolescents with osteomalacia. *European Journal of Nuclear Medicine*, 24(2), 202–205.
- El-Desouki, M.I., Othman, S.M. & Fouda, M.A. (2004) Bone mineral density and bone scintigraphy in adult Saudi female patients with osteomalacia. *Saudi Medical Journal*, 25(3), 355–358.
- Gayed, I., Salama, V., Dawood, L., Canfield, S., Wan, D., Cai, C. et al. (2018) Can bone scans guide therapy with radium-223 dichloride for prostate cancer bone metastases? *Cancer Management and Research*, 10, 3317–3324.
- de Graaf, P., Pauwels, E.K.J., Vos, P.H., Schicht, I.M., te Velde, J. & de Graeff, J. (1984) Observations on computerized quantitative bone scintigraphy in renal osteodystrophy. *European Journal of Nuclear Medicine*, 9(9), 419–425.
- Gupta, N., Pruthi, A., Verma, R. & Manocha, A. (2020) An unusual case of hyperparathyroidism, presenting as multiple skeletal lesions. *World Journal of Nuclear Medicine*, 19(2), 149–151.
- Gupta, S.K., Gambhir, S., Mithal, A. & Das, B.K. (1993) Skeletal scintigraphic findings in endemic skeletal fluorosis. *Nuclear Medicine Communications*, 14(5), 384–390.
- Harshman, L.K., Latifi, H.R. & Griffeth, L.K. (2011) Visualization of discrete sacral foramina as an ancillary sign of superscan. *Clinical Nuclear Medicine*, 36(1), 21–24.
- Hawkins, T. & Halewood, M.M. (2008) Technical note: identifying the prostate cancer 'superscan' by quantitative skeletal scintigraphy. *Nuclear Medicine Communications*, 29(7), 654–659.
- Huang, J.F., Shen, J., Li, X., Rengan, R., Silvestris, N., Wang, M. et al. (2020) Incidence of patients with bone metastases at diagnosis of solid tumors in adults: a large population-based study. *Annals of Translational Medicine*, 8(7), 482.
- Khoury, J., Jerushalmi, J., Cohen, H.I., Loberant, N. & Zaina, A. (2003) Super scan leading to definitive diagnosis in a patient with recurrent syncope. *Clinical Nuclear Medicine*, 28(11), 886–889.
- Kim, C.D., Kim, S.H., Kim, Y.L., Cho, D.K. & Lee, J.T. (1998) Bone marrow immunoscintigraphy (BMIS): a new and important tool for the assessment of marrow fibrosis in renal osteodystrophy? *Advances in Peritoneal Dialysis. Conference on Peritoneal Dialysis*, 14, 183–187.
- Kim, S., Park, C. & Kim, B. (2001) "Superscan" in an autosomal-dominant benign form of osteopetrosis. *Clinical Nuclear Medicine*, 26(7), 636–637.
- Koizumi, M. & Matsumoto, S.I. (1998) Distinctive patterns of super scan appearance in bone metastasis and hyperthyroidism. *Clinical Nuclear Medicine*, 23(6), 391–392.
- Kotb, M.H., El-Maghraby, T., Khalafallah, K., Omar, W., Grace, B.D. & Al-Nahhas, A. (2007) Clinical significance of metabolic superscan in patients with hyperthyroidism. *Nuclear Medicine Review. Central & Eastern Europe*, 10(2), 76–81.
- Liu, R.S., Chu, Y.K., Chu, L.S., Yeh, S.H., Yen, S.H., Chen, K.Y. et al. (1996) Superscan in patients with nasopharyngeal carcinoma. *Clinical Nuclear Medicine*, 21(4), 302–306.
- Liu, Y. (2011) Super-superscan on a bone scintigraphy. *Clinical Nuclear Medicine*, 36(3), 227–228.
- Manohar, P.R., Rather, T., Khan, S. & Malik, D. (2017) Skeletal metastases presenting as superscan on Technetium 99m methylene diphosphonate whole body bone scintigraphy in different type of cancers: a 5-year retro-prospective study. *World Journal of Nuclear Medicine*, 16(1), 39–44.
- Ohashi, K., Smith, H.S. & Jacobs, M.P. (1991) "Superscan" appearance in distal renal tubular acidosis. *Clinical Nuclear Medicine*, 16(5), 318–320.
- Osmond, 3rd J.D., Pendergrass, H.P. & Potsaid, M.S. (1975) Accuracy of 99mTc-diphosphonate bone scans and roentgenograms in the detection of prostate, breast and lung carcinoma metastases. *The American Journal of Roentgenology, Radium Therapy and Nuclear Medicine*, 125(4), 972–977.
- Pinto-Lopes, P., Fonseca, F.A., Silva, R., Hafe, P. & Fonseca, E. (2013) Indolent systemic mastocytosis limited to the bone: a case report

- and review of the literature. *Sao Paulo Medical Journal*, 131(3), 198–204.
- Pour, M.C., Simon-Corat, Y. & Horne, T. (2004) Diffuse increased uptake on bone scan: super scan. *Seminars in Nuclear Medicine*, 34(2), 154–156.
- Rathke, H., Afshar-Oromieh, A., Giesel, F.L., Kremer, C., Flechsig, P., Haufe, S. et al. (2018) Intraindividual comparison of (99m)Tc-methylene diphosphonate and prostate-specific membrane antigen ligand (99m)Tc-MIP-1427 in patients with osseous metastasized prostate cancer. *Journal of Nuclear Medicine*, 59(9), 1373–1379.
- Shih, W.J., Mitchell, B., Wierzbinski, B., Magocum, S. & Ryo, U.Y. (1991) Prediction of radionuclide bone imaging findings by Gleason histologic grading of prostate carcinoma. *Clinical Nuclear Medicine*, 16(10), 763–767.
- Shinya, T., Akaki, S., Ogata, T., Sato, S. & Kanazawa, S. (2007) Super scan in a patient with diffuse bone metastases from intracranial glioma. *Clinical Nuclear Medicine*, 32(6), 481–483.
- Simsek, D.H., Sanli, Y., Civan, C., Engin, M.N., Isik, E.G., Ozkan, Z.G. et al. (2020) Does bone scintigraphy still have a role in the era of 68 Ga-PSMA PET/CT in prostate cancer? *Annals of Nuclear Medicine*, 34(7), 476–485.
- Stadlnik, R.C., Manier, S.M. & Van Nostrand, D. (1984) Super bone scan. *Seminars in Nuclear Medicine*, 14(1), 46–47.
- Sy, W.M., Patel, D. & Faunce, H. (1975) Significance of absent or faint kidney sign on bone scan. *Journal of Nuclear Medicine: official Publication, Society of Nuclear Medicine*, 16(6), 454–456.
- Tan, T.H., Wong, T.H., Hassan, S.Z.A. & Lee, B.N. (2015) Unusual bone superscan, MIBG superscan, and 68Ga DOTATATE PET/CT in metastatic pheochromocytoma. *Clinical Nuclear Medicine*, 40(11), 867–868.
- Tripathi, M., Arora, S., Dhull, V., Mukherjee, A., Tulsyan, S. & Behera, A. (2015) Metastatic superscan on (99m)Tc-methylene diphosphonate bone scintigraphy in pediatric neuroblastoma. *Indian Journal of Nuclear Medicine*, 30(3), 286–287.
- van den Bergh, R.C.N., O'Hanlon, S., Cornford, P. & Mottet, N., EAU-EANM-ESTRO-ESUR-SIOG Guideline Panel on Prostate Cancer. (2021) Reply to Michael Froehner, Rainer Koch, and Markus Graefen's Letter to the Editor re: Nicolas Mottet, Roderick C.N. van den Bergh, Erik Briers, et al. EAU-EANM-ESTRO-ESUR-SIOG guidelines on prostate cancer-2020 update. Part 1: screening, diagnosis, and local treatment with curative intent. *Eur Urol* 2021;79:243-62. Comorbidity measurement in patients with prostate cancer. *European Urology*, 79(5), e139–e140.
- Washington, T., Vora, A. & Mihalescu, D. (2010) A case of hypercalcemia associated with Castleman disease. *Endocrine Practice*, 16(6), 1007–1011.
- Windsor, P.M. (2001) Predictors of response to strontium-89 (Metastron) in skeletal metastases from prostate cancer: report of a single centre's 10-year experience. *Clinical Oncology*, 13(3), 219–227.
- Yüksel, D., Ilgan, S., Arslan, N., Uğur, Ö., ÖZTÜRK, E. & Bayhan, H. (2000) The role of Tc-99m (V) DMSA scintigraphy in the evaluation of superscan on bone scintigraphy. *Clinical Nuclear Medicine*, 25(3), 193–196.
- Zanglis, A., Andreopoulos, D., Zissimopoulos, A. & Baziotis, N. (2006) Multiple brown tumors with Tc-99m MDP superscan appearance and negative Tc-99m MIBI uptake. *Clinical Nuclear Medicine*, 31(10), 640–643.

How to cite this article: Kovacsne, A., Kozon, I., Bentestuen, M. & Zacho, H.D. (2023) Frequency of superscan on bone scintigraphy: a systematic review. *Clinical Physiology and Functional Imaging*, 43, 297–304.

<https://doi.org/10.1111/cpf.12821>