

Stability of the anterior maxillary segment and teeth after segmental Le Fort I osteotomy and postoperative skeletal elastic fixation with or without occlusal splint

Blæhr, Tue Lindberg; Jensen, Thomas; Due, Karen Margrete; Neumann-Jensen, Bjarne

Published in:
Program and abstract book

Publication date:
2015

Document Version
Publisher's PDF, also known as Version of record

[Link to publication from Aalborg University](#)

Citation for published version (APA):

Blæhr, T. L., Jensen, T., Due, K. M., & Neumann-Jensen, B. (2015). Stability of the anterior maxillary segment and teeth after segmental Le Fort I osteotomy and postoperative skeletal elastic fixation with or without occlusal splint. In *Program and abstract book : 37th Congress of the Scandinavian Association of Oral and Maxillofacial Surgeons in collaboration with Danish Association of Oral and Maxillofacial Surgeons* (pp. 20)

General rights

Copyright and moral rights for the publications made accessible in the public portal are retained by the authors and/or other copyright owners and it is a condition of accessing publications that users recognise and abide by the legal requirements associated with these rights.

- Users may download and print one copy of any publication from the public portal for the purpose of private study or research.
- You may not further distribute the material or use it for any profit-making activity or commercial gain
- You may freely distribute the URL identifying the publication in the public portal -

Take down policy

If you believe that this document breaches copyright please contact us at vbn@aub.aau.dk providing details, and we will remove access to the work immediately and investigate your claim.



PROGRAM AND ABSTRACT BOOK

**37th Congress of The Scandinavian Association
of Oral and Maxillofacial Surgeons in collaboration
with Danish Association of Oral and Maxillofacial
Surgeons 3-5 June 2015, Copenhagen Denmark**



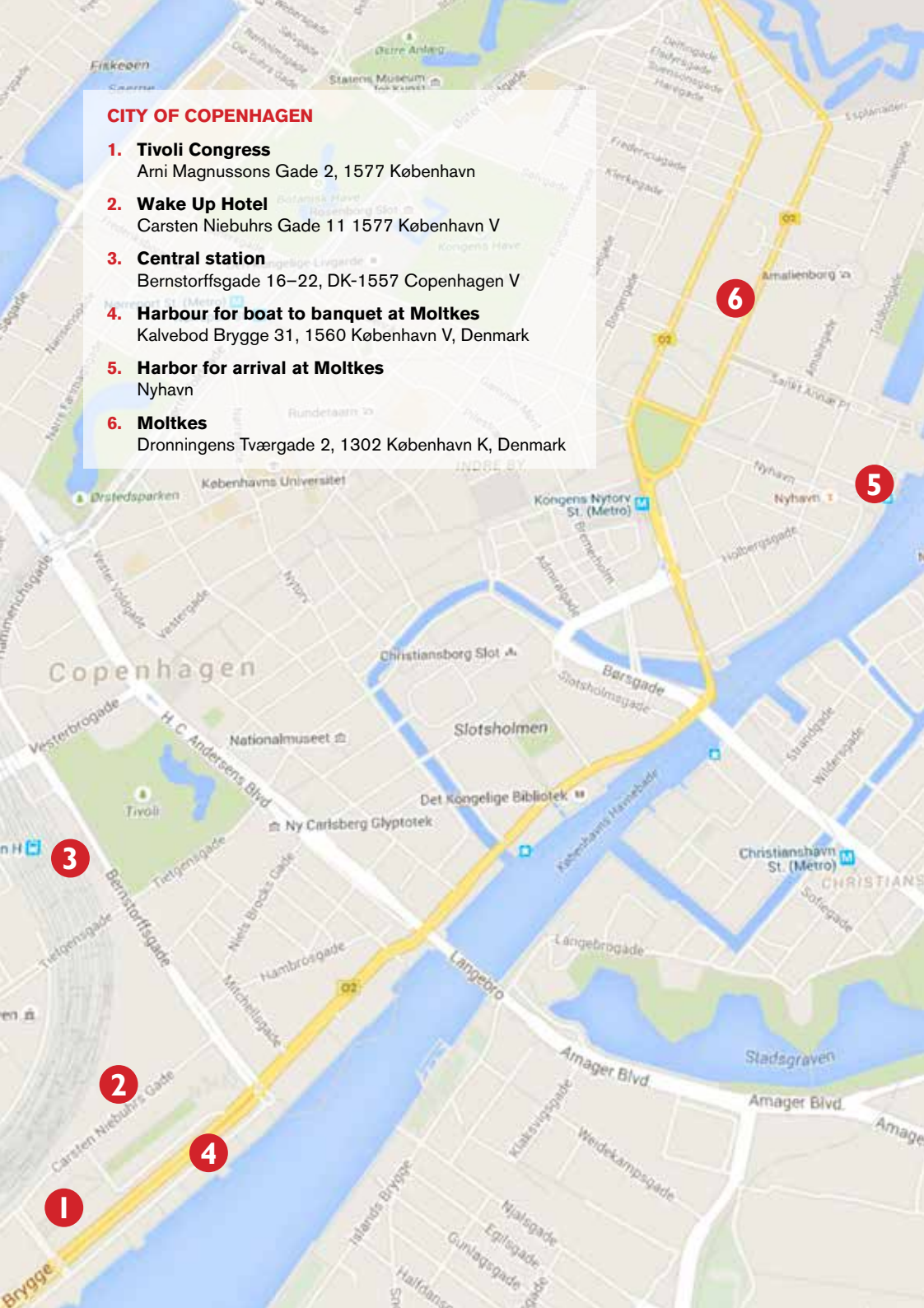
Scandinavian Association
of Oral and Maxillofacial Surgeons

DSOMK

DANSK SELSKAB FOR
ORAL OG MAXILLOFACIAL KIRURGI

CITY OF COPENHAGEN

- 1. Tivoli Congress**
Arni Magnussons Gade 2, 1577 København
- 2. Wake Up Hotel**
Carsten Niebuhrs Gade 11 1577 København V
- 3. Central station**
Bernstorffsgade 16–22, DK-1557 Copenhagen V
- 4. Harbour for boat to banquet at Moltkes**
Kalvebod Brygge 31, 1560 København V, Denmark
- 5. Harbor for arrival at Moltkes**
Nyhavn
- 6. Moltkes**
Dronningens Tværgade 2, 1302 København K, Denmark



WELCOME TO THE CONGRESS

The Scandinavian Association of Oral and Maxillofacial Surgeons in collaboration with the Danish Association of Oral and Maxillofacial Surgeons warmly welcome you to the 37th Congress here in Copenhagen, June 3-5, 2015. This congress marks the 50th anniversary of the founding of the Scandinavian Association of Oral and Maxillofacial Surgeons in Copenhagen the 20th June 1965.

We are very pleased about the high number of interns, colleagues, and friends who have signed up for the conference and about the many abstracts that have been submitted for oral presentations and posters. We are very much looking forward to sharing these days with you enjoying lectures given by our honorary members, well known scientists, and less experienced interns. The evenings will offer entertainment and dining, all to make this 50th anniversary congress a memorable one!

Enjoy Copenhagen!

Michael Skøien With, CONGRESS CHAIR

Janek Dalsgaard Jensen, CONGRESS CO-CHAIR

Thomas Jensen, SCIENTIFIC ORGANIZER

Janicke Liaaen Jensen, PRESIDENT SFOMK



Scandinavian Association
of Oral and Maxillofacial Surgeons

DSOMK
DANSK SELSKAB FOR
ORAL OG MAXILLOFACIAL KIRURGI

We thank our sponsors and exhibitors for their support and participation!

PLATINUM



GOLD



SILVER



EXHIBITORS

Biomet Microfixation ▪ Brainlab Sales GmbH ▪ Dental Digital Norge AS
Karl Storz Endoskopi ▪ Mectron ▪ Operations Instrument AB
Planmeca ▪ PO Medica AB ▪ Puredent ApS ▪ Unident AB

PROGRAM Wednesday 3 June

Hall Pjerrot

PRE COURSE

Dr. G. William Arnett;
Planning orthognathic surgery and facial reconstruction

08.00 Registration to the pre course

08.30 Pre-congress course starts

10.00 – 10.30 Coffee break

12.00 – 13.00 Lunch

14.30 – 15.00 Coffee break

17.00 Course ends

17.30-18.30 KKF Annual Meeting

SFOMK CONGRESS

17.00 – 20.00 Registration to the congress

19.00 – 22.00 Get Together Evening - Welcome Reception in the exhibition

PROGRAM Thursday 4 June

All lectures are in Hall Pjerrot

Exhibition, lunch and coffee breaks are in Hall Harlekin-Columbine

08.00 – 08.45 Registration

08.45 – 09.00 Conference program starts
Welcome by Professor Janicke Liaaen Jensen, President SFOMK

09.00 – 10.00 Dr Daniel M. Laskin, Professor and Chairman emeritus.
The history of oral and maxillofacial Surgery.

10.00 – 10.30 **COFFEE and EXHIBITION**

10.30 – 11.30 Christian J. Lindqvist
Reconstruction of the facial skeleton – from external fixation to 3D and stemcells

11.30 – 11.50 Dr Søren Aksel Christian Krarup
Clinical Aspects of a Novel Implant
Company sponsored symposium, Straumann

11.50 – 12.10 Michael Mey (Junior Product Support Manager – Product Management Implant Systems),
New Technologies in Craniomaxillofacial Surgery: Additive Manufacturing!
Company sponsored symposium, LJ Medical /KLS Martin

12.10 – 12.30 **Free papers**

Chairman: Michael Skøien With, DDS, MPM, Department of Otolaryngology and Maxillofacial Surgery, Koege Hospital, Denmark.

12.10 – 12.30 **Update on the scandinavian osteonecrosis database**

Morten Schiødt¹, Cecilia Larsson Wexell²,
Bente Brokstad Herlofson³, Sven Erik Nørholt⁴, Vera Ehrenstein⁵,
Henrik Toft Sørensen⁵.

¹Department of Oral & Maxillofacial Surgery, Rigshospitalet, Copenhagen, Denmark.

²Department of Oral & Maxillofacial Surgery, Southern Alvsborgs Hospital, Region Vstra Gotaland, Boras, Sweden.

³Department of Oral Surgery and Oral Medicine, Faculty of Dentistry, University of Oslo, Oslo, Norway.

⁴Aarhus University and Department of Oral & Maxillofacial Surgery, Aarhus University Hospital, Aarhus, Denmark.

⁵Department of Clinical Epidemiology, Aarhus University Hospital, Aarhus, Denmark.

12.30 – 13.30 LUNCH, EXHIBITION and POSTERS

13.30 – 14.30 Free papers

Orthognatic surgery:

Chairman: Sven Erik Nørholt, Professor, DDS, PhD, Department of Oral and Maxillofacial Surgery, Aarhus University Hospital, Aarhus, Denmark.

13.30 – 13.40 Reconstruction of alveolar cleft defects with a minimal extensive chin bone harvesting technique.

John Jensen, DDS, PH.D, Martin Dahl, DDS,
Sven Erik Nørholt, DDS, PHD.

Department of Oral and Maxillofacial Surgery, Aarhus University Hospital,
Aarhus, Denmark.

13.40 – 13.50 Improved apnea hypopnea index and lowest oxygen saturation after maxillomandibular advancement with OR without counterclockwise rotation in patients with obstructive sleep apnea a meta-analysis.

Thorkild Knudsen.

Department of Oral and Maxillofacial Surgery, Køge Hospital, Denmark.

13.50 – 14.00 Le fort I patients might have difficulties getting used to their new facial appearance.

Kuhlefelt Marina, Laine Pekka, Thorén Hanna.

Oral and maxillofacial deceases, University of Helsinki and Helsinki University Hospital.

14.00 – 14.10 Stability of the anterior maxillary segment and teeth after segmental le fort I osteotomy and postoperative skeletal elastic fixation with or without occlusal splint.

Tue Lindberg Blæhr¹, Thomas Jensen¹, Karen Margrethe Due²,
and Bjarne Neumann-Jensen¹.

¹Department of Oral and Maxillofacial Surgery, Aalborg University Hospital,
Aalborg, Denmark.

²Center for Cardiovascular Research, Aalborg University Hospital, Aalborg, Denmark.

14.10 – 14.20 Skeletal stability after large mandibular advancement (>10 mm) with bilateral sagittal split osteotomi and skeletal elastic intermaxillary fixation.

Kristoffer Schwartz^{1,2}, Thomas Jensen¹.

¹Department of Oral Maxillofacial Surgery, Aalborg University Hospital, Aalborg,
Denmark.

²Department of Oral Maxillofacial Surgery, Aarhus University Hospital, Aarhus, Denmark.

14.20 – 14.30 Transverse expansion of segmented maxillary procedures.
Kasper Stokbro¹, Esben Aagaard¹, Peter Torkov¹, R Bryan Bell²,
Torben Thygesen¹.

¹Department of Oral and Maxillofacial Surgery, Odense University Hospital, Denmark.

²Department of Oral and Maxillofacial Surgery, Oregon Health and Science
University, SDOMS, Portland, OR, USA.

14.30 – 15.00 COFFEE and EXHIBITION

15.00 – 16.00 Free papers

Orthognathic surgery and osteonecrosis:

Chairman: Bente B. Herlofson, Department of Oral Surgery and
Oral Medicine, Faculty of Dentistry, University of Oslo, Norway.

**15.00 – 15.10 Gender determines bleeding in orthognathic surgery.
A prospective clinical study of a healthy patient population.**

Jesper Jared Olsen, Johannes Sidelmann, Janne Ingerslev,
Jens Thorn, Else Marie Pinholt, Jørgen Gram.

Unit for Thrombosis Research, Institute of Public Health, University of Southern
Denmark,

Department of Oral and Maxillofacial Surgery, Hospital of South West Denmark, Esbjerg,

Department of oral diagnostics, Institute of Odontology, The University of
Copenhagen, Faculty of Health and Medical Sciences.

**15.10 – 15.20 Factors influencing intraoperative blood loss in
orthognathic surgery.**

Thastum M, Andersen K, Rude K, Nørholt SE, Hvas A, Blomlöf J.

Department of Oral and Maxillofacial Surgery, Aarhus University Hospital, Aarhus,
Denmark.

**15.20 – 15.30 Complications and side effects related to the early
treatment with bone anchors: a retrospective case study
of 82 patients.**

Anne-Mette Wegge-Larsen¹, Thomas Klit Pedersen², Jytte Buhl¹
and Sven Erik Nørholt¹.

¹Department of Oral and Maxillofacial Surgery, Aarhus University Hospital, Denmark.

²Department of Orthodontics, Aarhus University Hospital, Denmark.

- 15.30 – 15.40 Eight danish cases of herpes zoster related osteonecrosis of the jaw from 1982 to 2014.**
 Camilla Ottesen¹, Michael With², Ole Schwartz¹, Jesper Reibel³, Morten Schiodt¹
¹Department of Oral & Maxillofacial Surgery, Rigshospitalet, Copenhagen University Hospital, Denmark.
²Department of Oral & Maxillofacial Surgery, Koege Hospital, Region Zealand, Denmark.
³Oral Pathology, Department of Odontology, University of Copenhagen, Denmark.
- 15.40 – 15.50 Surgical treatment of antiresorptive induced osteonecrosis of the jaw. Outcome of 14 consecutive patients using PRF.**
 Nørholt SE, Krogh H
 Department of Oral and Maxillofacial Surgery, Aarhus University and University Hospital, Aarhus, Denmark.
- 15.50 – 16.00 Bone remodeling may be altered by Alendronate's effect on human osteoblasts.**
 Tormod B. Krüger¹, Maria A. Landin², Janne E. Reseland², Bente B. Herlofson¹.
¹Department of Oral Surgery and Oral Medicine, Faculty of Dentistry, University of Oslo, Norway.
²Department of Biomaterials, Faculty of Dentistry, University of Oslo, Oslo, Norway.
- 16.00 – 17.00 SFOMK general assembly: For all members of SFOMK**
- 18.00 Boat leaves for Congress Banquet & 50th Anniversary Celebration**



PROGRAM Friday 5 June

09.00 – 10.30 Symposium on implant dentistry.

Professor Daniel Buser, Bern, Switzerland.
Aesthetic challenges in implant dentistry.

10.30 – 11.00 **COFFEE, EXHIBITION AND POSTERS**

11.00 – 11.45 Dr Simon Storgård Jensen, Copenhagen, Denmark.
Materials used in bone augmentation procedure.

11.45 – 12.30 Dr Thomas Jensen, Aalborg, Denmark.
Sinus augmentation procedure.

12.30 – 13.30 **LUNCH, EXHIBITION and POSTERS**

13.30 – 14.30 **Free papers**

**Implantology, bone augmentation,
and dentoalveolar surgery:**

Chairman: Eivind Andersen, Department of Oral Surgery and Oral Medicine,
Faculty of Dentistry, University of Oslo, Norway.

13.30 – 13.40 **Effect of antibiotic prophylaxis in dental implant surgery.**

Bodil Lund, Margareta Hultin, Sofia Tranæs, Aron Naimi-Akbar,
Björn Klinge.

Department of Oral and Maxillofacial Surgery, Karolinska University Hospital,
Stockholm.

Div of Oral and Maxillofacial Surgery, Department of Dental Medicine,
Karolinska Institutet, Sweden.

13.40 – 13.50 **Synchrotron μ CT Imaging – an interdisciplinary team
work – characteristics and future in Scandinavia**

Pinholt EM¹, Vinther B², Feidenhansl' R³

¹Professor, DDS, M Sci, dr. odont., Consultant, University of Southern Denmark
Hospitals, Hospital of South West Denmark, Department of Oral & Maxillofacial
Surgery, Esbjerg, Denmark. ²Professor, PhD, ³Professor, PhD, Head of Institute,
Niels Bohr Institute, Copenhagen, Denmark.

13.50 – 14.00 **Reconstruction of severe maxillary atrophy in 50 patients.**

Jens Thorn, Janne Ingerslev.

Department of Oral & Maxillofacial Surgery, Hospital of South West Denmark,
Esbjerg.

14.00 – 14.10 The effect of hydrofluoric acid treatment of titanium surface on human gingival fibroblasts.

Maria H. Pham¹, Alessandra Rinna¹, Håvard J. Haugen¹,
Jan Eirik Ellingen², Janne E. Reseland¹.

¹Department of Biomaterials, and ²Department of Prosthodontics Institute for Clinical Dentistry, Faculty of Dentistry, University of Oslo, Oslo, Norway.

14.10 – 14.20 Recording of clinical data after mandibular third molar surgery: utilizing a novel e-infrastructure for data recording in clinical research.

H. Øyri, T. Bjørnland, P. Barkvoll, J. L. Jensen.

Dept. Oral Surgery and Oral Medicine, Institute of Clinical Dentistry, University of Oslo, Norway.

14.20 – 14.30 Stem cells in bone regeneration, a systematic approach and pilot study in humans.

Cecilie Gjerde, Sølve Hellem, Mohamed Yassin, Kamal Mustafa.
University of Bergen, Institute of Clinical Dentistry.

14.30 – 15.00 COFFEE and EXHIBITION

15.00 – 16.00 Free papers

Temporomandibular joint disorders:

Chairman: Anders B. Holmlund, DDS, PhD, Professor, Department of Oral and Maxillofacial Surgery, Karolinska Institute, Huddinge, Sweden.

15.00 – 15.10 A Prospective, Single Center Study on Patient Outcomes Following Temporomandibular Joint Replacement Using a Patient Matched Biomet TMJ Implant

Esben Aagaard, DMD, Chief Surgeon, Torben H. Thygesen, DMD, PhD, Assoc. Professor

Department of Oral and Maxillofacial Surgery, Odense University Hospital, Odense C, Denmark.

15.10 – 15.20 Temporomandibular joint pain is negatively correlated to tnfr alpha and osteoprotegerin content in synovial fluid in patients with juvenile idiopathic arthritis.

Heming Olsen-Bergem¹, Tore Bjørnland, Janne E Reseland.

¹Dept. of oral surgery and oral medicine, IKO, Faculty of Dentistry, University of Oslo.

15.20 – 15.30 Retrospective study on arthroscopic lysis and lavage of the temporomandibular joint.

Mattias Ulmner, Carina Kruger-Weiner, Bodil Lund.

Department of Oral and Maxillofacial Surgery, Karolinska University Hospital, Huddinge, Stockholm.

15.30 – 15.40 Prevalence, demography and clinical properties of TMD in Norwegian adolescents.

Østensjø V¹, Moen K^{1,2}, Storesund T³, Rosén A^{1,2}

¹Department of Oral and Maxillofacial Surgery, Institute of Clinical Dentistry, Faculty of Medicine and Dentistry, University of Bergen.

²Department of Oral and Maxillofacial Surgery, Haukeland University Hospital, Bergen, Norway. ³Specialist Oral Health Centre for Western Norway, Stavanger, Norway.

15.40 – 15.50 Patients with severe temporomandibular joint disorders - a multidisciplinary approach.

Rosén A¹, Schjöldt B², Bell RF², Johansson A¹, Paulsberg A-G², Geitung JT³, Berge T¹

¹The Head and neck clinic, Dept. of Oral and Maxillofacial Surgery.

²Centre for Pain Management and Palliative Care, Haukeland University Hospital.

³Department of Radiology, Haraldsplass Deaconess University Hospital, Bergen, Norway.

15.50-16.00 Autoimmunity diseases and inflammatory conditions are associated with an increased risk of TMJD – a hospital based case control study.

Adrian Salinas Fredricson, DDS,¹ Farid Khodabandehlou, DDS,¹ Carina Krüger Weiner, DDS, PhD,¹ Aron Naimi-Akbar, DDS, PhD,¹ Johanna Adami, MD, PhD,² Annika Rosén,^{1,3} DDS, PhD.

¹Division of Orofacial Diagnostics and Surgery, Section of Oral and Maxillofacial Surgery, Department of Dental Medicine, Karolinska Institutet, Stockholm, Sweden; Dept of Oral and Maxillofacial Surgery, Karolinska University Hospital, Stockholm, Sweden

²Clinical Epidemiology Unit, Department of Medicine, Karolinska Institutet, Stockholm, Sweden;

³Department of Clinical Dentistry, division of Oral and Maxillofacial Surgery, University of Bergen, Bergen, Norway;

16.00 – 16.30 Summary and end of Conference

Poster presentation

Thursday 4 June: P1 – P10

- P1. Extreme oral manifestations in a patient with Crohn's disease.**
S.Afnan, B.B Herlofson.
Department Oral Surgery and Oral Medicine, Institute of Clinical Dentistry,
University of Oslo, Norway.
- P2. In vitro assesment of primary stability of bone trust® sinus implant design.**
Aydin Gülses*, Mustafa Ayna**, Metin Sencimen***, Matthias Gierloff****, Yahya Açıl****
*Mevki Military Hospital, Centre of Dentistry and Oral Health, Ankara, Turkey
**Private Practice, Duisburg, Germany
***Gulhane Military Medical Academy, Department of Oral and Maxillofacial Surgery, Ankara, Turkey
****Christian Albrechts University, Department of Oral and Maxillofacial Surgery, Kiel, Germany
- P3. "A night with Venus, a lifetime with Mercury" - Syphilis, the overlooked disease.**
Elisa Kier-Swiatecka, Elisa Kier-Swiatecka, Consultant, Department of OMS, Sydvestjysk Sygehus Esbjerg, Katrine Urth Hansen, Senior Registrar, Department of Clinical Diagnostics, Surgical Pathology, Sydvestjysk Sygehus Esbjerg, Jens Thorn, Head of Department, Ph.d., Department of OMS, Sydvestjysk Sygehus Esbjerg, Else Marie Pinholt, Professor, Dr. Odont., Consultant, Department of OMS, Sydvestjysk Sygehus, Esbjerg.
- P4. Orthognathic surgery or open temporomandibular joint surgery in outpatient settings.**
Göran Gynther, Måns Jungner, Mattias Ulmner
Department of Oral and Maxillofacial Surgery, Karolinska University Hospital, Stockholm, Sweden.
- P5. Withdrawn**
- P6. Fibrous Dysplasia.**
Helle Baugaard Nielsen¹, Lars Nygaard Madsen¹, Daiva Erentaite², Thomas Jensen¹.
¹Department of Oral and Maxillofacial Surgery, Aalborg University Hospital, Aalborg, Denmark.
²Department of Pathology, Aalborg University Hospital, Aalborg, Denmark.
- P7. Orbital compartment syndrome after facial trauma in a patient on warfarin: a case report.**
Lado Lako Loro¹, Lotte Erdmann²
¹Dept. of Oral & Maxillofacial Surgery, ²Dept of Ophthalmology, Aalesund Hospital, Moere and Romsdal Health Trust, Norway.

P8. Utilization of intraoperative navigation treating maxillofacial trauma.

Iman Azarmehr DDS, Kasper Stokbro DDS, Torben Thygsen DDS phd
Department of Oral and Maxillofacial Surgery, Odense University hospital, Denmark.

P9. Differentiation Ability of hBMSCs after Transportation and Manufacturing.

Cecilie G. Gjerde, Melanie Liesenfeld, Sølve Hellem, Kamal Mustafa
Department of clinical dentistry, Faculty of medicine and dentistry, University of Bergen, Norway

P10. Teeth alignment in MRI – evaluation of a marker based method.

Jean-Marc Luukinen, Daniel Aalto, Naoko Niikuni, Päivi Jääsaari, Tero Soukka, Riitta Parkkola, Jani Saunavaara, Jarmo Malinen, and Risto-Pekka Happonen.
Department of Oral and Maxillofacial Diseases, University of Turku, Finland.

Friday 5 June: P11 – P20

P11. Delayed open reduction and internal fixation of a condylar neck fracture, is it possible?

Blomlöf Johan
Department of Oral and Maxillofacial Surgery, Aarhus University Hospital, Aarhus, Denmark.

P12. Photodynamic treatment: an alternative approach in the management of oral lichen planus

Juliane Hesse^{1,2}, Trond Warloe³, Sigrid I. Kvaal¹
¹Faculty of Dentistry, University of Oslo, Oslo, Norway; ²The Public Dental Health Service of Troms, Tromsø, Norway; ³Oslo University Hospital, Oslo, Norway.

P13. Ameloblastic Carcinoma.

Kristian Thesbjerg, Jytte Buhl
Department of Oral and Maxillofacial Surgery, Aarhus University Hospital and Department of Oral and Maxillofacial Surgery, Aalborg University Hospital.

P14. Case report: unusual oro-facial infection causing pathologic fracture of the mandibular condyle

Linderup ML, Helleberg M, Schytte S, Pikelis A, Nørholt SE
Department of Oral and Maxillofacial Surgery, Aarhus University Hospital, Denmark.

P15. Treatment of an unicystic ameloblastoma in the maxilla in a 67-years old male.

Nicolai Paaske, DDS, Jytte Buhl, DDS.
Department of Oral and Maxillofacial Surgery, Aarhus University Hospital, Denmark.

P16. Surgical decompression of retrobulbar haemorrhage via a medial eyebrow approach: technical note and a 3-patient series.

Oscar Hammarfjord, Kelly Podlosky, and Leo F. A. Stassen

National Maxillofacial Unit. St James's Hospital, James's Street, Dublin 8, Ireland.

P17. Case report: oral syphilis a possible reemerging infection prompting clinician alertness.

Sebastian Dybeck Udd, Bodil Lund

Department of Oral and Maxillofacial Surgery, Karolinska University Hospital, Stockholm, Sweden.

P18. MMF screws in treatment of mandibular fractures.

Vlad Florescu¹, Thomas Kofod², Else Marie Pinholt³

¹Ph.D Fellow at University of Copenhagen Institute of Clinical Medicine

²DDS, Ph.D and Head of Department at Department of Oral and Maxillofacial Surgery, University Hospital of Rigshospitalet, Copenhagen, Denmark.

³DDS, MS, dr.odont, Professor at Department of Oral and Maxillofacial Surgery at Sydvestjysk Hospital, Esbjerg, Denmark.

P19. Retrospective study on maxillofacial fractures operated at Aalesund hospital

Lado Lako Loro¹, Espen Helgeland², Ida M. Dahle², Jan Inge Leira¹

¹Department of Oral & Maxillofacial Surgery, Aalesund Hospital, Moere and Romsdal Health Trust, Norway.

²Department of Oral Surgery & Oral Medicine, Univ. of Bergen, Bergen, Norway.

P20. Orthodontic closure in the anterior region maintaining the facial profile, a way of avoiding problems with implants.

Salaheddin Omar Abbas¹, Rannvá Matras²

¹Regional orthodontic unit, Region Zealand, Denmark

²Department of Otorhinolaryngology and Oral & Maxillofacial Surgery, Koege Hospital, Denmark

Information to our speakers and poster presenters

Speakers:

We kindly ask you to download your presentation at the latest on the morning of your speech (have it saved with your name)

- Thursday between 8.00 – 8.45
- Friday between 8.30 – 9.00

Poster presenters:

Poster nr 1-10 will be up for Thursday

- Mounting between 8.00 – 8.45 and your poster should be taken down at the end of the conference day

Poster nr 11-20 will be up for Friday

- Mounting between 8.30 – 9.00 and your poster should be taken down at the end of the conference day

ORAL PRESENTATIONS

Abstracts of Oral Presentations

Abstracts of Oral Presentations

Abstracts of Oral Presentations

Abstracts of Oral Presentations

Abstracts of Oral Presentations

Abstracts of Oral Presentations

Abstracts of Oral Presentations

Abstracts of Oral Presentations

Abstracts of Oral Presentations

Abstracts of Oral Presentations

Abstracts of Oral Presentations

Abstracts of Oral Presentations

Abstracts of Oral Presentations

Abstracts of Oral Presentations

Abstracts of Oral Presentations

Abstracts of Oral Presentations

Abstracts of Oral Presentations

Abstracts of Oral Presentations

Abstracts of Oral Presentations

Abstracts of Oral Presentations

Abstracts of Oral Presentations

Abstracts of Oral Presentations

Abstracts of Oral Presentations

Abstracts of Oral Presentations

Abstracts of Oral Presentations

Abstracts of Oral Presentations

Abstracts of Oral Presentations

Abstracts of Oral Presentations

UPDATE ON THE SCANDINAVIAN OSTEONECROSIS DATABASE

Morten Schiødt¹, Cecilia Larsson Wexell², Bente Brokstad Herlofson³, Sven Erik Nørholt⁴, Vera Ehrenstein⁵, Henrik Toft Sørensen⁵

¹*Department of Oral & Maxillofacial Surgery, Rigshospitalet, Copenhagen, Denmark*

²*Department of Oral & Maxillofacial Surgery, Southern Alvsborgs Hospital, Region Västergötland, Borås, Sweden*

³*Department of Oral Surgery and Oral Medicine, Faculty of Dentistry, University of Oslo, Oslo, Norway*

⁴*Aarhus University and Department of Oral & Maxillofacial Surgery, Aarhus University Hospital, Aarhus, Denmark*

⁵*Department of Clinical Epidemiology, Aarhus University Hospital, Aarhus, Denmark*

Email: morten.schioedt@regionh.dk

Background

Osteonecrosis of the jaws (ONJ) is a serious side-effect related to treatment with bisphosphonates and denosumab and occurs with increasing frequency. Data are missing on epidemiology, pathogenesis, and treatment. A small annual number of ONJ cases at each clinic limits the research possibilities. Therefore, we have established a Scandinavian database including Denmark, Sweden and Norway. We presented the establishment of this database at the SFOMK Congress in Stockholm in May 2013.

Aim

To report the progress and current status of the Scandinavian ONJ Database.

Material and methods

We have set up a Scandinavian research infrastructure for a planned epidemiologic study of incidence rates of ONJ among 2,700 cancer patients treated with XGEVA® (denosumab) and Zometa® (zoledronic acid). The study period is from Oct 1, 2011 and 5+ years onwards. Utilizing this infrastructure, we have established a Scandinavian ONJ database including all cases of ONJ, i.e., both cancer patients and patients with osteoporosis and other diseases treated with antiresorptive agents will be included. We have invited all clinics and departments of oral & maxillofacial surgery in Denmark, Sweden and Norway, to participate. A coordinator for each country has been appointed, and each clinic has appointed a local contact person to work with the national coordinator. Information on the database has been distributed. The first patients have been enrolled from the three countries.

Results

The first scientific paper reporting the establishment of the database and initial progress was published in January 2015 (Schiødt et al. Existing data sources for clinical epidemiology: Scandinavian Cohort for Osteonecrosis of the Jaw – work in progress and challenges. *Clinical Epidemiology* 2015;7:1-10). We have so far (February 2015) enrolled ONJ cases into the database from Denmark (n=244), Sweden (n=155) and from Norway (n=145) comprising a total of 544 ONJ cases.

Conclusions

Each national coordinator will report the challenges, the progress, and details on the ONJ cases from their country. We believe that this large-scale systematic collection of data on ONJ will give us a tool for future scientific projects including improvement of treatment and better understanding of this challenging group of patients.

RECONSTRUCTION OF ALVEOLAR CLEFT DEFECTS WITH A MINIMAL EXTENSIVE CHIN BONE HARVESTING TECHNIQUE

John Jensen, DDS, PH.D, Martin Dahl, DDS, Sven Erik Nørholt, DDS, PHD

Department of Oral and Maxillofacial Surgery, Aarhus University Hospital, Aarhus, Denmark.

svenoe@rm.dk

Aim: The aim of the current study was to assess the postsurgical morbidity and patient satisfaction after reconstruction of alveolar cleft bone defects with a minimal extensive chin bone harvesting technique.

Material and methods: In the period 2010-2011 97 patients with alveolar clefts – 75 unilateral (UCLP) and 22 bilateral (BCLP) had a reconstruction of an alveolar defect at the Department of Oral and Maxillofacial Surgery, Aarhus University Hospital, Denmark. The inclusion criteria for this study were patients with a minimal extend of UCLP which only had a demand of 1-3 cc of bone for reconstruction. At the donor site in the symphyseal region of the mandible the bone was attended through a vertical incision in the inferior labial frenulum. After periosteal elevation the bone graft was harvested by use of a piezoelectric device (Piezosurgery, Mectron, Carasco, Italy) and chisels and directly adapted to the bony alveolar cleft defect. Post-surgical morbidity was documented in the records as encountered. All patients were mailed a questionnaire used in former studies of complications in relation to reconstruction of alveolar defects in cleft patients (Booij, 2005). The questionnaire contained multiple choice questions concerning perioperative and post-operative pain, as well as its severity and duration. Moreover, the questionnaire focused on sensory disturbances of skin and oral mucosa, contour changes of the chin, perception of scarring, and the general level of satisfaction and general acceptance of the surgical procedure and outcome.

Results: 18 UCLP patients were included in the study. The mean age at surgery was 9.9 years (range 7.1-14.9 years). The duration of hospitalization was in all cases one day. A low level of morbidity was encountered, mainly bleeding and swelling (11.4%). The results from the questionnaire revealed a high satisfaction with the outcome of the treatment, and no sensory disturbances were registered postsurgically.

Conclusion: Reconstruction of a minimal extend of UCLP with the described technique in young patients with a cleft is a safe procedure, and few complications are encountered by this minimal invasive surgical technique. Furthermore, the use of a vertical incision in the midline of the chin region may eliminate the risk of neurosensory disturbances and improve the readaptation of the mentalis muscle.

IMPROVED APNEA HYPOPNEA INDEX AND LOWEST OXYGEN SATURATION AFTER MAXILLOMANDIBULAR ADVANCEMENT WITH OR WITHOUT COUNTERCLOCKWISE ROTATION IN PATIENTS WITH OBSTRUCTIVE SLEEP APNEA A META-ANALYSIS.

Purpose

This study investigated whether patients with obstructive sleep apnea (OSA) who undergo maxillomandibular advancement (MMA) with counterclockwise (CCW) rotation compared with those who undergo MMA without CCW rotation have better outcomes.

Materials and Methods

This was a systematic review with meta-analysis. The Medline and Cochrane databases were searched for randomized controlled trials using Medical Subject Headings. The predictor variable was operative technique, namely MMA with or without CCW rotation of the maxillofacial complex. The key outcome variables were changes in pre- and postsurgical values of pharyngeal volume measured on computed tomogram or cone-beam computed tomogram and changes in Apnea-Hypopnea Index (AHI) and lowest oxygen saturation (LSAT) values after surgery. Data were subjected to a meta-analysis based on odds ratios (OR) with 95% confidence intervals (CIs) and *P* values lower than .05 by χ^2 test were considered significant.

Results

Twenty-one randomized controlled trials were identified and 4 were assessed for the variables of interest. Postoperative AHI and LSAT measurements showed vast improvement. The sample was not large enough to make a correlation between pharyngeal volume changes and surgical method used. Postoperative parameters included an AHI lower than 5 (OR = 14.9; 95% CI, 2.7-83.5; *P* = .002), an AHI lower than 20 (OR = 114.8; 95% CI, 23.5-561.1; *P* < .00001), pooled results of a 50% decrease in the AHI (OR = 6.1; 95% CI, 2.2-17.0; *P* = .0006), and an increase greater than 90% in LSAT measurements during sleep (OR = 6.0; 95% CI, 1.8-19.9; *P* = .003). The funnel plot showed no evidence of publication bias.

Conclusion

CCW-MMA or MMA in patients with OSA results in a statistically meaningful decrease in postoperative AHI and a statistically meaningful increase in postoperative LSAT.

LE FORT I PATIENTS MIGHT HAVE DIFFICULTIES GETTING USED TO THEIR NEW FACIAL APPEARANCE

Kuhlefelt Marina¹, Laine Pekka², Thorén Hanna³

Oral and maxillofacial deceases, University of Helsinki and Helsinki University Hospital

marina@hammasfreda.com

Aim: There are very few studies dealing with the patient's subjective adaption to the new facial appearance and treatment result in Le Fort I patients. The aim of this prospective study was to identify factors Le Fort I patients found difficult after completed surgical and orthodontic treatment.

Material and methods: In this prospective study with a one year follow up, we recorded factors Le Fort I patients found difficult after completed treatment. We asked the patients what they found most difficult of the following: Facial appearance, neurosensory disturbance, occlusal change, scars or something else.

Results: Eleven patients (6 female, 54.5%) with a mean age of 29.0 years (range 18.4 years to 50.2 years) completed the study. There was no drop out. One patient was a smoker and one had asthma. All patients were satisfied with the treatment and would go true the same treatment again. Still 4 patients found it hard to get used to their new facial appearance, and one of these patients found it hard to learn to smile after the treatment. Two patients found the neurosensory disturbance most difficult after treatment. Five patients had no difficulties after treatment.

Conclusions: There are indications that patients undergoing Le Fort I osteotomies have difficulties in getting accustomed to their new appearance, even if they are satisfied with the occlusion and treatment outcome. Some of these patients would probably benefit from psychological support during treatment, but larger prospective studies with a sufficient follow up time is needed, before any far going conclusions can be made.

STABILITY OF THE ANTERIOR MAXILLARY SEGMENT AND TEETH AFTER SEGMENTAL LE FORT I OSTEOTOMY AND POSTOPERATIVE SKELETAL ELASTIC FIXATION WITH OR WITHOUT OCCLUSAL SPLINT

**Tue Lindberg Blæhr¹, Thomas Jensen¹, Karen Margrethe Due²,
and Bjarne Neumann-Jensen¹**

¹*Department of Oral and Maxillofacial Surgery, Aalborg University Hospital, Aalborg Denmark*

²*Center for Cardiovascular Research, Aalborg University Hospital, Aalborg Denmark*

Email of presenting author: t.blaehr@rn.dk

Aim

To assess the short term dental and skeletal stability of the anterior maxillary segment after segmental Le Fort I osteotomy with postoperative elastic fixation with or without occlusal splint.

Material and Methods

29 consecutive patients underwent segmental Le Fort I osteotomy and elastic skeletal fixation was applied. Patients were divided into two groups according to whether a fixed occlusal splint was used for six weeks (group A) or dismounted perioperatively (group B). Changes in landmarks and reference planes between the two timepoints were estimated on lateral cephalometric radiographs.

Results

Group A: The upper incisor had a mean intrusion of -0.56 mm (SD 0.77; range -2.04 to 1.08 mm) and a mean posterior movement of -0.93 mm (SD 1.03; range -2.52 to 0.96 mm). The mean change in the axial inclination of the upper incisor was -0.33° (SD 2.56; range -6° to 4°) (95% CI: -1.75 to 1.08°). Group B: The upper incisor had a mean intrusion of -0.13 mm (SD 1.36; range -1.92 to 3.6 mm) and a mean anterior movement of 0.11 mm (SD 1.78; range -2.88 to 3.84 mm). The mean change in the axial inclination of the upper incisor was -0.07° (SD 3.05; range -5° to 5°) (95% CI: -1.83 to 1.69°). There was no statistically significant difference in stability between the two groups at the P value 0.05.

Conclusion

The skeletal anterior fixation with postoperative elastics for eight weeks may not compromise the early postoperative dental and skeletal stability of the anterior segment in segmental Le Fort I osteotomy.

SKELETAL STABILITY AFTER MANDIBULAR ADVANCEMENT WITH BILATERAL SAGITTAL SPLIT OSTEOTOMY AND SKELETAL ELASTIC INTERMAXILLARY FIXATION

Kristoffer Schwartz

Department of Oral Maxillofacial Surgery, Aalborg University Hospital and Department of Oral Maxillofacial Surgery, Aarhus University Hospital, Denmark. E-mail: k.schwartz@rn.dk

Thomas Jensen

Department of Oral Maxillofacial Surgery, Aalborg University Hospital, Denmark

Aim: The purpose of the present study was to evaluate the skeletal stability after large mandibular advancement with bilateral sagittal split osteotomy and skeletal elastic intermaxillary fixation.

Material and methods: From January 2007 until December 2012 a total of 33 consecutively patients underwent double-jaw surgery to correct skeletal Class II malocclusion, with a mandibular advancement > 10 mm at B-point. The patients were treated postoperatively with skeletal elastic intermaxillary fixation. Lateral cephalograms were traced presurgically (T1), 8 weeks postoperatively (T2) and 18 month postoperatively (T3).

Results: 20 females and 13 males with a mean age of 22.9 years (16-46). The mean follow-up time was 19 month (17-30). The mean advancement at B-point and Pog were 11.62 mm and 13.50 mm, respectively. Relapse at follow-up was -1.31 at B-point and -1.58 mm at Pog.

Conclusion: Bilateral sagittal split osteotomy is characterized as a stable surgical procedure to correct Class II malocclusion. However, in large mandibular advancements (>7 mm) there is an increased risk of relapse. The present study demonstrated a limited amount of skeletal relapse in large mandibular advancement (> 10 mm at B-point) with bilateral sagittal split osteotomy and skeletal elastic intermaxillary fixation.

TRANSVERSE EXPANSION OF SEGMENTED MAXILLARY PROCEDURES

Kasper Stokbro^{*}, Esben Aagaard^{*}, Peter Torkov^{*}, R Bryan Bell[§], Torben Thygesen^{*}.

^{}Department of Oral and Maxillofacial Surgery, Odense University Hospital, Denmark*

[§]Department of Oral and Maxillofacial Surgery, Oregon Health and Science University, SDOMS, Portland, OR, USA

e-mail address of presenting author: kasper.stokbro@rsyd.dk

Aim

To evaluate, to which extent the planned transverse expansion is obtained during segmented maxillary procedures in orthognathic surgery?

Material and methods

We evaluated 13 segmented procedures, controlled by 17 nonsegmented procedures. Orthognathic surgical planning was performed virtually by Dolphin 3D (Dolphin Imaging and Management, Chatsworth, CA, USA) with a Cone Beam CT-scan (NewTom 3G, QR-Srl, Verona, Italy) both preoperatively and at 1 week follow-up. The planned expansion of the virtual plan was compared with the expansion obtained in the CBCT-scan at 1-week follow-up. Transverse width was measured between the mesiobuccal cusps of the first molars.

Results

The study showed a mean difference between planned and obtained expansion of -1.4 mm (Standard deviation: 1.0 mm).

Conclusion

The results raise questions regarding the benefit of segmented procedures in expansions of less than 1.5 mm. Do the benefits still outweigh the risk of a segmentation?

Segmented procedures have potential for improvement. Further research is necessary.

GENDER DETERMINES BLEEDING IN ORTHOGNATHIC SURGERY - A PROSPECTIVE CLINICAL STUDY OF A HEALTHY PATIENT POPULATION

**Jesper Jared Olsen^{1,2}, Johannes Sidelmann, Janne Ingerslev, Jens Thorn,
Else Marie Pinholt, Jørgen Gram**

*¹Unit for Thrombosis Research, Institute of Public Health, University of Southern Denmark,
Department of Oral and Maxillofacial Surgery, Hospital of South West Denmark, Esbjerg,
Department of oral diagnostics, Institute of Odontology, The University of Copenhagen, Faculty
of Health and Medical Sciences,
²jesper.jared.olsen@rsyd.dk*

Aim:

The aim was to conduct a prospective clinical trial on predictors of intraoperative bleeding in the bimaxillary orthognathic surgical population. Although this group of patients is homogenous regarding age and health status a variation in intraoperative bleeding volume has been observed. The ability to identify excessive bleeding in advance could prove useful when planning for surgery, but little is known regarding hemorrhage predictors in the healthy surgical patient.

Material and methods:

The sample size consisted of 41 ASA class I patients, ≥ 18 years, scheduled for bimaxillary OS at the Department of Oral and Maxillofacial Surgery, Hospital of South West Denmark in 2010-11. Whole blood samples were collected preoperatively, 2½ - and 48 hours postoperatively. Intraoperative blood volume was precisely estimated. Blood platelet count, activated partial thromboplastin time, prothrombin time, plasma fibrinogen concentration, F1+2 and D-dimer concentrations were determined by routine methods. The viscoelastic properties of whole blood samples were evaluated by thromboelastography (TEG), a global coagulation assay.

Results:

Patient data were sorted according to gender. The main finding was a correlation between gender and intraoperative bleeding volume (400 ± 300 -500ml vs. 200 ± 163 -288 ml, $p=0.001$). Significant differences in perioperative D-dimer, pre- and postoperative fibrinogen levels and preoperative F1+2 levels were found ($P<0.016$). The precise outcome will be disclosed at the oral presentation in Copenhagen June 2015.

Conclusion:

Gender correlates with intraoperative bleeding volume, D-dimer, fibrinogen and F1+2 concentrations in bimaxillary OS patients. The exact mechanism is not fully understood but is suggested to lie within the hemostatic balance. Further studies that target fibrin formation and degradation in healthy individuals are suggested.

FACTORS INFLUENCING INTRAOPERATIVE BLOOD LOSS IN ORTHOGNATHIC SURGERY

Thastum M, Andersen K, Rude K, Nørholt SE, Hvas A, Blomløf J

Purpose: Procedures for surgical correction of dentofacial deformities may in some cases cause abundant blood loss. The aim of the present study was to identify factors of importance for intraoperative blood loss in a group of patients undergoing orthognathic surgery including Le Fort I osteotomy with segmentation, bilateral sagittal split osteotomy and a combination of the two procedures.

Materials and Methods: The records of 358 adult patients, 207 female and 149 male patient having orthognathic surgery during a 3 year period (January 2010- December 2012) were analyzed retrospectively. Patients were placed in three groups based on the operation performed. Estimated blood loss was correlated with patient's age, sex, BMI, time of operation and type of operation.

Results: Average estimated blood loss for all groups was 323 mL. Bimaxillary procedures resulted in more blood loss than Le Fort I osteotomy with segmentation, which again resulted in more blood loss than bilateral sagittal split osteotomy. Blood loss was significantly related to length of surgery, but not to either sex or age. Only two patients recieved blood transfusion (0.53%) and their average estimated blood loss was 1550 mL.

Conclusions: The study has shown that orthognathic surgery can be performed with only little risk for intraoperative bleeding in amounts that will require blood transfusion. Further more we found a correlation between length of operation time and blood loss and type of surgery and blood loss. Age and sex had no influence on blood loss.

COMPLICATIONS AND SIDE EFFECTS RELATED TO THE EARLY TREATMENT WITH BONE ANCHORS: A RETROSPECTIVE CASE STUDY OF 82 PATIENTS

Anne-Mette Wegge-Larsen¹, Thomas Klit Pedersen², Jytte Buhl¹ and Sven Erik Nørholt¹

¹Department of Oral and Maxillofacial Surgery, Aarhus University Hospital, Denmark and

²Department of Orthodontics, Aarhus University Hospital, Denmark

A-M Wegge-Larsen resident at the department of Oral and Maxillofacial Surgery, Aarhus University Hospital.

anwegg@rm.dk

Aim: To examine the surgical aspect of bone anchor (BA) treatment and associated complications.

Material and methods: The study was a retrospective analysis of 82 patients consecutively treated with BA from March 2010 to Jan 2014. Their age ranged from 11 to 14 years. In 67 patients the aim was to correct a skeletal class III malocclusion with mesial molar relations; in 6 patients vertical discrepancies were the indication for treatment, and in 9 patients a SARME procedure was performed concomitant with insertion of BA. In general, the patients were offered treatment with BA if it was found advantageous to obtain an early modulation of the growth of the jaws. Some patients were treated with fixed appliances and/or hyrax at the same time as BA. A retrospective survey of the patient files was conducted and data concerning surgical procedure, surgical complications and complications experienced by the patients were registered up till February 2015.

Results: Approximately 1/3 of the patients did not experience any complications with this treatment modality, whereas the other 2/3 of the patients did experience one or more episodes with a complication or side effect. This being a period with slight irritation of the mucosa around the BA, gingival hyperplasia, infection or loosening of the BA etc. Of these 14 had additional surgical procedure to replace the BA but most happened when this procedure were new and 14 patients terminated their treatment earlier than planned. The complications very divided into minor, moderate and severe. No irreversible complications very found.

Conclusion: We have found treatment with BA promising though a clear learning curve is seen. The BAs are placed and removed during general anaesthesia. During the period in which this treatment modality has been offered, the department has switched from Bollard miniplate anchorage to Synthes miniplate anchorage. Loosening and/or infection around the BA may be salvaged by discontinuing the elastics for 4-6 weeks and provide chlorhexidine rinsing and antibiotic treatment. If this does not stabilize the BA a second surgery is needed. To avoid problems, we have found following factors of importance: sufficient cortical bone, good oral hygiene, minimal touching of BA with tongue or fingers, BA head placed near keratinized gingiva and no traumatising of gingiva from BA head or elastics. A study evaluation the treatment effect on the same patient group is ongoing, and a prospective study of BA treatment has been initiated.

EIGHT DANISH CASES OF HERPES ZOSTER RELATED OSTEONECROSIS OF THE JAW FROM 1982 TO 2014

Camilla Ottesen¹, Michael With², Ole Schwartz¹, Jesper Reibel³, Morten Schiodt¹

1. Department of Oral & Maxillofacial Surgery, Rigshospitalet, Copenhagen University Hospital, Denmark

2. Department of Oral & Maxillofacial Surgery, Koege Hospital, Region Zealand, Denmark

3. Oral Pathology, Department of Odontology, University of Copenhagen, Denmark

E-mail address of presenting author: camilla.ottesen@regionh.dk

Osteonecrosis of the jaws are often related to radiation or antiresorptive medication. Very rarely, herpes zoster infection involving the trigeminal maxillary and mandibular branches may also be associated with osteonecrosis of the jaws. Only 45 cases have been reported worldwide since 1955, and most publications have been isolated case-reports. We have had 8 cases in Copenhagen since 1982. This is the first time a series of eight cases are reported from the same site. This series has given us the possibility to characterize this extremely rare condition.

Aim: To report the disease spectrum of herpes zoster of the trigeminal nerve and osteonecrosis of the jaws among eight cases.

Material and methods: Consecutive patients with trigeminal herpes zoster and osteonecrosis in Copenhagen since 1982. All patients had clinical, imaging, histological and laboratory examinations.

Results: The patient material included three men and five women, age range 15-79 years. Three cases involved the maxillary branch, four cases the mandibular branch, and one case all three branches of the trigeminal nerve.

Co-morbidities were present in five cases including HIV-related immune deficiency, systemic lupus erythematosus (SLE), CD8 T-cell lymphopenia, multiple myeloma and Hodgkin's-related chemotherapy. However, three cases did not have any known predisposing factors.

The onset of osteonecrosis was spontaneous (n=3), related to tooth extractions (n=4) and related to attempted bone augmentation and implant insertion (n=1). In six cases the osteonecrosis led to loss of teeth, leaving the patients with a characteristic asymmetric dentition, which we name "the herpes zoster dentition". Surgical block resection was performed in three patients, all three patients healed successfully. Five patients healed after spontaneous sequestration. The follow-up time was 90 months on average, median 30 months, range 5 to 348 months. All patients had complete healing of the osteonecrosis at last examination and six patients had dentures made to replace the missing teeth.

Conclusion: Herpes zoster infection located in the trigeminal branches may lead to osteonecrosis of the jaws immediately or at any time after the infection. It is advised to include previous herpes zoster infection in the medical history questionnaire. We propose that a patient with previous herpes zoster will always be at risk of developing osteonecrosis of the jaw. Triggering factors are tooth extractions or other dentoalveolar surgery. The exact pathogenesis by which herpes zoster infection causes osteonecrosis of the jaw is unknown. Prospective studies are required.

SURGICAL TREATMENT OF ANTIRESORPTIVE INDUCED OSTEONECROSIS OF THE JAW. OUTCOME OF 14 CONSECUTIVE PATIENTS USING PRF

Nørholt SE, Krogh H

Department of Oral and Maxillofacial Surgery, Aarhus University and University Hospital, Aarhus, Denmark

svenoe@rm.dk

Aim

To describe the surgical technique for treatment of osteonecrosis of the jaw (ONJ) with the use of platelet rich fibrin (PRF) and to report the outcome of these treatments in 14 consecutive patients.

Material and methods

In a one year period (Feb 2014 – Jan 2015) surgical treatment of ONJ was performed in 14 patients (10 females and 4 males). Age ranged from 54 to 83 years (mean 69).

Eight patients had antiresorptive treatment because of skeletal involvement of malignant disease (4 breast, 2 kidney, 1 prostate, 1 myelomatosis) and six were treated for osteoporosis. Correspondingly, eight had been treated with high-dose antiresorptive (3 Zometa, 1 aredia, 2 bondronate, 2 XGEVA), and six with low-dose (3 alendronate, 3 Prolia).

The surgical treatment (8 in general anaesthesia, 6 in local) included resection of necrotic bone, mobilization of flaps for passive closure (in 5 patients with buccal fat pad) and coverage of the jaw bone with PRF membranes derived from 4 to 8 blood samples (of 10 ml) obtained from the patient before surgery. Ten lesions occurred in the mandible, three in the maxilla and one in both jaws. The stage of ONJ at time of surgery was 2 in 12 patients and 3 in 2.

Results

In 12 patients a complete coverage of the exposed bone was obtained. The remaining two patients had improvement to stage 1 (one male, alendronate and one female, Zometa) with minor areas of exposed bone without symptoms.

Conclusion

Surgical treatment of ONJ is challenging with a risk of recurrence of bone exposure. Therefore, we have sought for means to optimize the surgical procedure. In this series of cases a success rate of 86% was obtained. The use of PRF membranes appears to be a promising technique that warrants further investigation.

BONE REMODELLING MAY BE ALTERED BY ALENDRONATE'S EFFECT ON HUMAN OSTEOBLASTS

Tormod B. Krüger¹, Maria A. Landin², Janne E. Reseland², Bente B. Herlofson¹

¹*Department of Oral Surgery and Oral Medicine, Faculty of Dentistry, University of Oslo, Norway*

²*Department of Biomaterials, Faculty of Dentistry, University of Oslo, Oslo, Norway*

Presenting authors email: t.b.kruger@odont.uio.no

Aim:

Bisphosphonates have a well-documented ability to inhibit bone resorption by promoting apoptosis in mature osteoclasts. The effect on human osteoblasts is less clear, as most in vitro studies are done on murine cell lines. In this study we tested the effect of alendronate, a widely used bisphosphonate, on vitality, and the expression and secretion of bone markers and cytokines from human primary osteoblasts.

Material and methods:

Normal human osteoblasts (Cambrex) from femur of 2 donors, were incubated with alendronate dissolved in cell culture medium to final concentrations of 20 and 100 µM. Cells and cell culture media were harvested after 1, 3, 7 or 14 days of incubation, and untreated cells at each time point were used as control. Lactate dehydrogenase (LDH) activity was used as measure of cytotoxicity. Multianalyte profiling of factors secreted to the cell culture medium was performed using the Luminex 200TM system and the XY Platform, and gene expression was monitored using SYBR green detection.

Results:

Neither of the alendronate concentrations tested had cytotoxic effect, measured as LDH activity, compared to untreated osteoblasts. The secretion of several factors, including osteoprotegerin (OPG), osteocalcin (OC), adiponectin, granulocyte colony-stimulating factor (G-CSF), interleukin-1b (IL-1b), IL-4, IL-5, monocyte chemoattractant protein-1 (MCP-1), soluble IL-2 reseptor alpha (sIL-2Ra), tumor necrosis factor-a (TNF-a) and vascular endothelial growth factor (VEGF) were not affected by the alendronate. In addition, numerous factors tested were below the set parameter for detection; leptin (LEP), insulin, eotaxin, IL-1Ra, interferon-γ (IFN-γ), IL-2, IL-6, IL-10, IL-12p40, IL-13, IL-17, IP-10, macrophage inflammatory protein-1a (MIP-1a) and MIP-1β.

There was a dose-dependent increase in the levels of IL-8 and regulated on activation normal T-cell expressed (RANTES), whereas the secretion of osteopontin (OPN), IL-7 and IL-15 where decreased by alendronate when compared to control. Alendronate enhanced the expression of LEP mRNA and induced a dose-dependent decrease in the expression of OC, alkaline phosphatase (ALP) and collagen type 1 alpha 1 (Col1A1) during the study period.

Conclusions:

There is a dose-dependent increase in the secretion of immune parameters from human osteoblasts treated with alendronate, indicating that higher dosages of alendronate may cause undesirable local changes in bone. The high rate of proliferation in alveolar bone combined with a change in osteoblasts signalling might change the quality of this bone compared to other sites.

EFFECT OF ANTIBIOTIC PROPHYLAXIS IN DENTAL IMPLANT SURGERY

Bodil Lund, Margareta Hultin, Sofia Tranæs, Aron Naimi-Akbar, Björn Klinge.

*Dep of Oral and Maxillofacial Surgery, Karolinska University Hospital, Stockholm
Div of Oral and Maxillofacial Surgery, Dep of Dental Medicine, Karolinska Institutet, Sweden*

Aim: The benefit of antibiotic prophylaxis during implant placement is a controversial subject. Available literature, including systematic reviews, displays disparate results. The aim of this study was to revisit the available scientific literature regarding perioperative antibiotics in conjunction with dental implant placement by combining the Health Technology Assessment methods recommended for systematic reviews and primary studies, resulting in a complex systematic review.

Material and methods: A search of Medline (OVID), The Cochrane Library (Wiley) and EMBASE, PubMed and Health technology assessment (HTA) organisations was performed, in addition to a complementary hand-search. Selected systematic reviews and primary studies (randomized controlled trials) were assessed independently by two reviewers in a two stage approach using AMSTAR and GRADE, respectively. The main out-come measure was implant losses on patient level. Statistical heterogeneity was estimated using Chi-square (Q value) and I² analyses. A narrative analysis regarding clinical heterogeneity was performed as well as subsequent random effect model meta-analyses for risk ratio and risk difference.

Results: The literature search identified 846 papers of which 10 primary studies and 7 systematic reviews were included. Quality assessment of the systematic reviews revealed two studies of moderate risk of bias and five with high risk of bias. The two systematic reviews of moderate risk of bias stated divergent numbers needed to treat (NNT). Four of the primary studies comparing antibiotic prophylaxis with no antibiotic treatment were estimated to be of low or moderate risk of bias and subjected to meta-analysis. None of these four studies individually show a statistical significant benefit of antibiotic prophylaxis. The NNT to prevent one patient from implant loss was 50 (pooled RR 0.39, 95% CI 0.18, 0.84; P = 0.02). However, the narrative analysis of the studies eligible for meta-analysis reveals clinical heterogeneity regarding intervention and smoking with no beneficial effect of antibiotic prophylaxis in uncomplicated cases.

Conclusion: Antibiotic prophylaxis in conjunction with implant placement reduced the risk for implant loss by 2%. However, the sub-analysis of the primary studies suggests that there is no benefit of antibiotic prophylaxis in uncomplicated implant surgery in healthy patient. When stating recommendations for antibiotic prophylaxis, the calculated risk reduction at the patient level should be put in relation to the risk of adverse reactions, side-effects and the emerging problems with antibiotic resistance.

SYNCHROTRON μ CT IMAGING – AN INTERDISCIPLINARY TEAM WORK - CHARACTERISTICS AND FUTURE IN SCANDINAVIA

Pinholt EM*, Vinther B **, Feidenhansl' R*.**

**Professor, DDS, M Sci, dr. odont., Consultant, University of Southern Denmark Hospitals, Hospital of South West Denmark, Department of Oral & Maxillofacial Surgery, Finsensgade, Esbjerg, Denmark.*

*** Professor, PhD, *** Professor, PhD, Head of Institute, Niels Bohr Institute, Blegdamsvej 17, Copenhagen, Denmark.*

E-mail-adr: else.marie.pinholt@rsyd.dk

Aim: The aim is to present high resolution Synchrotron μ CT characteristics of bone, bone substitutes and peri-implant tissues. The aim is also to bring an eye-opener for the application of Synchrotron μ CT imaging within maxillofacial research, and for the Max - IV Institute in Lund, Sweden – an inter-Scandinavian research facility in its development.

Material and methods: Synchrotron μ CT was performed at the European Synchrotron Facilities, Grenoble, France, and μ CT was performed at the AO- Research Facilities, Davos, Switzerland, and at the Technische Universität, Munich, Germany, on specimens of an experimental goat mandible augmentation model. Reconstruction and data-treatment was performed at the Niels Bohr Institute.

Results: High resolution images of pixel-size 10 μ m, 5 μ m, 1.8 μ m and 1.4 μ m were obtained. Uncertainty of virtual histology readings were double in 2D – compared to those of 3D results.

Conclusion: Synchrotron μ CT makes it possible to evaluate specimens in 3D without cutting and grinding- and due to high resolution and vast numbers of images, results are significantly more precise than those of 2 D evaluations. The MedMax IV institute will be presented.

RECONSTRUCTION OF SEVERE MAXILLARY ATROPHY IN 50 PATIENTS.

Jens Thorn & Janne Ingerslev

Dept. Of Oral & Maxillofacial Surgery, Hospital of South West Denmark, Esbjerg.

jens.thorn@rsyd.dk

Aim:

To assess the method of rehabilitation of patients with severe maxillary atrophy by the use of autologous bone from the iliac crest in combination with BioOss (Geistlich) and a two-stage implant procedure.

Methods:

64 patients with extreme atrophy (Cawood & Howell Class V & VI) were treated from 2001 to 2013 with bone from the posterior iliac crest as particulated bone mixed with BioOss as inlay grafts combined with cortical veneer grafts for transverse correction of bone atrophy. In three patients the procedure was combined with Le Fort I osteotomy. Six months later 6-8 implants were placed and prosthetic rehabilitation was completed after a period of 6 months. 50 patients were followed prospectively from 1 to 10 years after use of their dental reconstructions with a medium observation period of 36 months. 32 had fixed bridges and 28 removable dentures.

Results:

The donor site morbidity was minimal and the grafting procedure was characterized by very few complications. There was good patient satisfaction with the final dental reconstruction. One patient lost one implant and another patient lost 6 implants. The overall implant survival rate was 97,5%. Eleven patients (22%) had periimplantitis of some degree. There have been no complications noted with the prosthetic rehabilitation of any patient except for the one with the many lost implants.

Conclusions:

The method used in our Department for treatment of patients with severe maxillary atrophy is in accordance with international standards with respect to: reliability, complication rate and patient satisfaction.

THE EFFECT OF HYDROFLUORIC ACID TREATMENT OF TITANIUM SURFACE ON HUMAN GINGIVAL FIBROBLASTS

Maria H. Pham¹, Alessandra Rinna¹,
Håvard J. Haugen¹, Jan Eirik Ellingen², Janne E. Reseland¹.

¹Department of Biomaterials, and ²Department of Prosthodontics Institute for Clinical Dentistry, Faculty of Dentistry, University of Oslo, Oslo

Corresponding author: hmnpham@odont.uio.no

Background and aim: Fluoride on the titanium implant surface is suggested to have a stimulatory effect on osteogenic cell lines and thus accelerate bone regeneration; however hydrofluoric acid treatment on Ti and TiO₂ surfaces gave no effect proliferation or differentiation on primary human osteoblast cells in vitro. The improved peri-implant tissue response of fluoride on the surface of metallic titanium (Ti) may be due to primary activation of other cells/tissues, like fibroblasts. In this study our aim is to test the effect of fluoride modification of Ti coins on primary human gingival fibroblasts (HGF-1).

Material and methods: Grit-blasted titanium (Ti) coins went through a surface modification procedure with 0.2 vol. % HF in 120 sec giving a fluoride-modified TiO₂ surface. Untreated coins were used as control. HGF-1 cells were incubated for 1, 3, 7 and 14 days with 3 biologic replica studies. Bone markers in the cell culture media were quantified using Luminex. Expression of genes related to fibroblast differentiation was evaluated by qRT-PCR. Proliferation studies were studied using ³H-Thymidine incorporation.

Results: The proliferation was significantly higher with fluoride modified surfaces compared to control. The addition of soluble sodium fluoride (NaF) (1, 10 and 100 µg/mL) had no significant effect on proliferation, demonstrating that the effect was due to the surface modification. Results in vitro study showed significant increase in protein release by Luminex of IL-6, OPG, SOST and confirming significant increase in gene expression by qRT-PCR of IL-6 and OPG.

Conclusion: The hydrofluoric acid treatment of TiO₂ surfaces induced enhanced growth of fibroblasts and stimulated the secretion of pro-inflammatory factors, with similarities to the initial molecular steps in wound healing.

RECORDING OF CLINICAL DATA AFTER MANDIBULAR THIRD MOLAR SURGERY: UTILIZING A NOVEL E-INFRASTRUCTURE FOR DATA RECORDING IN CLINICAL RESEARCH

H. Øyri, T. Bjørnland, P. Barkvoll, J. L. Jensen.

Dept. Oral Surgery and Oral Medicine, Institute of Clinical Dentistry, University of Oslo, NORWAY.

E-mail presenting author: hauk.oyri@odont.uio.no

Background

Primary recording of clinical data on a computer as opposed to “the pen and paper method” may reduce workload for researchers, and facilitates access to data for further analysis. University Health Network (UHN) is an e-infrastructure that enables creation of questionnaires and allows for secure collection, storage and sharing of anonymized patient data. As mandibular third molar (3M) surgery is frequently performed in our department, morbidity related to this procedure was chosen for data collection.

Aims

1. Describe our initial experience with UHN, a novel e-infrastructure for recording of data in clinical research.
2. Report results of a 1-year prospective study of morbidity one week after 3M surgery in our department utilizing UHN.

Material and methods

A prospective clinical study of patients followed up for the first week after 3M surgery was performed during a 1-year period, from September 2012-August 2013. Demographic data, indication for surgery and clinical findings were recorded. Chosen outcome variables were days requiring analgesic, days absent from work/school, and postoperative complications. Data were recorded using a UHN-based questionnaire. The study was approved by the Norwegian Social Science Data Service. Data were consolidated within the UHN system and exported for statistical analysis.

Results

A total of 527 procedures (448 patients) were performed. 396 procedures (362 patients) were recorded in UHN, thus giving an inclusion of 75% of the procedures. Mean number of days requiring analgesics was 3.8, and mean number of days absent from work/school was 0.6. Minor complications were reported by 7% of patients. Alveolar osteitis was the most commonly reported complication (3.5%). UHN simplified data recording, consolidation, and analysis. Some patients and some parameters were not recorded for reasons unrelated to UHN.

Conclusions

Recording and handling of data utilizing InReach was satisfactory. Unfortunately, computerized registration still allows for human errors, and constant calibration and motivation of the clinicians involved in the study are necessary. A pilot study is advised when implementing new methods for data recording in clinical research. In general, morbidity during the first week after 3M surgery was low. Prophylactic removal of 3Ms was associated with fewer days requiring analgesics and days absent from work/school as compared to teeth removed due to local disease.

STEM CELLS IN BONE REGENERATION, A SYSTEMATIC APPROACH AND PILOT STUDY IN HUMANS

Cecilie Gjerde, Sølve Hellem, Mohamed Yassin, Kamal Mustafa

University of Bergen, Institute of Clinical Dentistry, cecilie.gjerde@ok.uib.no

Aim: To reconstruct the atrophied posterior alveolar mandibular ridge using biomaterial and autologous bone marrow derived stem cells and to insert an implant into the new bone in a prosthetically guided position.

Material and method: Twelve patients presenting with the need of an implant retained restauration in the posterior mandibula and an alveolar ridge of maximum 4.5 mm width.

A clinical examination, x- rays and Cone Beam CT were accessed. A sample of the patients` bone marrow is extracted from the posterior iliac crest, immediately shipped to the collaborating GMP cell laboratory for cell expansion, and returned after 21 days. The stem cells mixed with Tri Calcium Phosphate are then used to augment the alveolar ridge. The material is covered with a titanium reinforced membrane before closure of the site. After four to six months a bone biopsy is performed and implants are installed in the regenerated bone.

Results: At present time, 10 patients have had the stem cell augmentation, and the first five patients have implants installed. Excellent primary implant stability was confirmed using the Ostell device. Histology and Micro-CT revealed excellent results.

Conclusion: This pilot study indicate that the use of bone marrow derived stem cells in the applied protocol for augmentation of the atrophied mandibular ridge have results comparable to the gold standard; autologous bone transplantation.

A PROSPECTIVE, SINGLE CENTER STUDY ON PATIENT OUTCOMES FOLLOWING TEMPOROMANDIBULAR JOINT REPLACEMENT USING A PATIENT MATCHED BIOMET TMJ IMPLANT

1. Esben Aagaard, DMD, Chief Surgeon, 2. Torben H. Thygesen, DMD, PhD, Assoc. Professor, Department of Oral and Maxillofacial Surgery, Odense University Hospital, Soender Boulevard 29, 5000 Odense C, Denmark, Europe

Introduction: Traditionally, treatments of temporomandibular disorders were based on diagnostic assessments, patient information, splint therapy, arthroscopies, arthrocentesis and finally, open joint surgeries. Earlier results of alloplastic TMJ surgery revealed inconsistent outcomes. In recent years, promising results with total joint reconstruction using new prosthesis types are published.

Aim: This prospective clinical study aimed to describe a wide range of pre- and postoperative clinical variables following uni- or bilateral total alloplastic TMJ reconstruction (TAR) using Biomet Microfixation Patient Matched Temporomandibular Joint (TMJ) Implant.

Material and methods: One hundred and forty six patients underwent unilateral (n=106) or bilateral (n=40) TMJ replacement surgery. Mean age was 47.5 ± 15.8 years; 90.3 % of joints were implanted in females. Patients were seen preoperatively and postoperatively at 1 week, 1, 3, 12, 18, 24, 36, 48, 60, 72 and 84 months. Patients were classified by the Wilkes Classification. Jaw pain intensity (VAS), maximum incisal opening (MIO) and adverse events were assessed.

Results: Mean follow up was 55.9 ± 16.8 months (range: 1-7 years). Wilkes Classification was Class V (n=59), Class IV (n=27) or Class III (n=12). Previous nonsurgical treatment and surgical treatment occurred in 96.7% and 91.9% of enrolled joints, respectively. Significant improvements in MIO relative to baseline (29.2 ± 11.1 mm) were observed beginning at 3 months (36.0 ± 7.6 mm; $p < 0.005$), and were maintained long term out to 4 years (40.2 ± 9.6 mm; $p < 0.005$). Patients experienced significant reductions in pain scores relative to baseline (6.6 ± 0.8) beginning 4 weeks (2.4 ± 0.2 ; $p < 0.005$) that were observed long term up to 4 years (1.5 ± 0.2 ; $p < 0.005$). The incidence of adverse events related to total alloplastic joint reconstruction was low. In 5.4% (10/186) of alloplastic joints, adverse events such as hematoma, infection, swelling and heterotopic bone formation were observed. One patient had mild trismus. In 9 cases the adverse events were possibly related to the alloplasty. Most events were resolved through proper treatment according to clinical diagnosis. Two joints (1.1%, 2/186) had to be explanted in two patients due to infection. One of them, originally a CrCo-implant was changed to a titanium implant. Six joints (3.2%, 6/186) were revised without explantation. The remaining adverse events resolved through proper treatment with antibiotics.

Conclusions: The present study indicates that TAR is a relevant treatment option, even in patients with a broad range of temporomandibular disorders. Our results show, that patients gained acceptable range of mouth opening and a significant reduction in pain following surgery. Although, our results seem promising, it should be emphasized, that TAR is associated with side effects and, thus, should only be used as an end stage treatment and when less invasive procedures fail. A comprehensive presurgical work up is pertinent. Furthermore the level of patient information should be high in order to obtain realistic expectations. Ongoing prospective studies are needed to consolidate possible significant treatment outcomes.

TEMPOROMANDIBULAR JOINT PAIN IS NEGATIVELY CORRELATED TO TNF ALPHA AND OSTEOPROTEGRIN CONTENT IN SYNOVIAL FLUID IN PATIENTS WITH JUVENILE IDIOPATHIC ARTHRITIS

Heming Olsen-Bergem*, Tore Bjørnland, Janne E Reseland

*Dept. of oral surgery and oral medicine, IKO, Faculty of Dentistry, University of Oslo

Aim. Temporomandibular joint (TMJ) involvement occurs in up to 80% of children with juvenile idiopathic arthritis (JIA). Little is known with regard to the complexity of the protein profile in synovial fluid (SF) from JIA arthritis during growth as compared to both JIA and rheumatoid arthritis (RA) of adults.

Material and methods. Synovial fluid was collected from 54 joints/30 patients with TMJ arthritis (JIA 35 joints/20 patients, JIA adults 9 joints/5 patients, RA 10 joints/5 patients). Three cytokines and seven bone markers were quantified using Luminex multiplex assays and compared to demographic and clinical data of function and pain.

Results. Pain (spontaneous and upon palpation) and duration of pain were all negatively correlated with the TMJ SF content of tumor necrosis factor (TNF)- α . The level of Adrenocorticotrophic hormone (ACTH) was negatively correlated to TMJ pain upon palpation and post-treatment pain and function. The concentration of ACTH was significantly lower in SF in JIA (1.4 ± 2.8 pg/ml) compared to adults with JIA (4.7 ± 12.2 pg/ml) and significantly higher compared to adults with RA (0.8 ± 1.5 pg/ml). Osteoprotegerin (OPG) was negatively correlated to spontaneous pain.

Conclusions. Our results indicate that the local concentrations of TNF- α , ACTH and OPG in TMJ fluid may not contribute to TMJ pain and tissue destruction in JIA/RA patients.

RETROSPECTIVE STUDY ON ARTHROSCOPIC LYSIS AND LAVAGE OF THE TEMPOROMANDIBULAR JOINT

Mattias Ulmner, Carina Kruger-Weiner, Bodil Lund

*Department of Oral and Maxillofacial Surgery, Karolinska University Hospital, Huddinge
S -141 86 Stockholm*

Mattias.ulmner@karolinska.se

Aim

Arthroscopic lysis and lavage of the temporomandibular joint is the primary surgical intervention of choice for patients with arthritis, chronic closed lock or osteoarthritis when not responding to non-surgical treatment. Our aim was to evaluate the success rate of all arthroscopic lysis and lavage performed at the department during the years 2008-2013 in order to identify possible factors for case selection and out-come prediction on individual basis.

Material and methods

All patients who had arthroscopic lysis and lavage at Karolinska University Hospital, Huddinge, from the 1st of January 2008 until 31st December 2013 were included and pre-, per- and postoperative variables regarding gender, medical history, medication, diagnosis, and complications were collected from the patients' medical records (Take Care – CompuGroup Medical). Patients that did not show up for postoperative controls were excluded and so were also individuals with incomplete medical records. Objective outcome measure was mouth opening capacity. Subjective outcome measures of interest were functional disability, joint pain and psychosocial influence.

Results

The preliminary analysis of the results shows that patients with chronic closed lock had better outcome of arthroscopic lysis and lavage than patients with arthritis or osteoarthritis ($p < 0.05$). Female gender predisposed independently for an unfavorable outcome ($p < 0.05$). Patients on medication for depression or anxiety disorder were more prone to unsuccessful treatment ($p < 0.05$). The success rate was correlated to the preoperative mouth opening capacity, where a more pronounced limitation seems to impair prognosis. No patients received prophylactic antibiotics and less than 2% of the operated patients had postoperative infections. No episodes of facial nerve weakness were recorded.

Conclusion

Arthroscopic lysis and lavage is a safe and successful therapy in selected patient-groups. Female gender, preoperative severe limited mouth opening capacity, antidepressant medication and osteoarthritis are possible indicators of an unsuccessful outcome. Tendencies in this material call for a prospective study with defined out-come variables as a basis for an individual diagnostic procedure and prognosis estimation.

PREVALENCE, DEMOGRAPHY AND CLINICAL PROPERTIES OF TMD IN NORWEGIAN ADOLESCENTS

Østensjø V¹, Moen K^{1,2}, Storesund T³ Rosén A^{1,2}

¹ Department of Oral and Maxillofacial Surgery, Institute of Clinical Dentistry, Faculty of Medicine and Dentistry, University of Bergen and ² Department of Oral and Maxillofacial Surgery, Haukeland University Hospital, Bergen, Norway. ³Specialist Oral Health Centre for Western Norway, Stavanger, Norway.

vegard.ostensjo@iko.uib.no

Aim: Estimate the prevalence of temporomandibular disorders (TMD) among adolescents, which has never been investigated in Norway. Age and sex distribution, general health, socio-economic status and demography were also investigated.

Material and methods: 563 adolescents, aged 13-19 years, were recruited consecutively at the time of their yearly examination at the public dentist in urban and rural areas in Rogaland County. A general health history was recorded together with socio-economic and demographic information. TMD-pain was recorded by asking two validated questions (Nilsson et al 2006). All participants that scored yes were then subjected to a more specific questionnaire and a clinical examination where the range of movement (ROM) of the mandible and the muscle tenderness to palpation were assessed according to the Research Diagnostic Criteria for TMD. Pain intensity was scored on a visual analogue scale (VAS) with the end points 0-10 (0=no pain and 10=worst unbearable pain). A control group was recruited among those patients that answered no.

Results: Among the 563 patients 41 patients (30 females and 11 males, with a median age of 17 years) reported a yes on the TMD-pain score which gave a TMD prevalence of 7.3%. When comparing the prevalence in the urban area clinics (9%), with the rural district clinic (3.4%) a significant difference ($p=0.018$) was seen. The prevalence of TMD was significantly increased among those who reported frequent headache, severe menstrual pain ($p<0.001$; $p=0.046$), and if they were living in families with divorced or single parents ($p=0.008$). Regular physical activity gave significantly less TMD ($p=0.025$). The clinical examination revealed primarily myalgia in 22 patients, joint disorders in 9 and 10 with a combination. Pain intensity ranged on the VAS scale from 0 to 7.5; for myalgia 2.5; joint disorder 3.6 and a combination 4.1. Pain in movement was reported in 80%. ROM ranged from 35-60 mm and joint sounds were found in 38%. Tenderness to palpation over the joint in 69% and in the muscles 80%.

Conclusion: The TMD prevalence in Norway is comparable with other countries. Female male ratio for TMD was 3:1. The prevalence was increased for adolescents living in urban areas, with frequent headaches, severe menstrual pain and divorced/single parents. Less TMD was seen among those who were regularly physically active. The pain intensity was higher with joint/muscles- than for solely muscle- disorders.

PATIENTS WITH SEVERE TEMPOROMANDIBULAR JOINT DISORDERS -A MULTIDISCIPLINARY APPROACH

Rosén A,* Schjöldt B,[□] Bell RF,[□] Johansson A,* Paulsberg A-G,[□] Geitung JT,[#] Berge T*

The Head and neck clinic, Dept. of Oral and Maxillofacial Surgery; Centre for Pain Management and Palliative Care[□], Haukeland University Hospital; Department of Radiology[#], Haraldsplass Deaconess University Hospital, Bergen, Norway*

Aim

Temporomandibular joint disorder (TMD/TMJ) is a disabling state for many patients. The symptoms are moderate to severe pain originating from the jaw muscles and/or the joint. Jaw function causes movement related pain and/or pain at rest. The Norwegian Ministry of Health has commissioned a project involving the multidisciplinary evaluation of TMD/TMJ patients.

Material and Methods

Sixty patients have been referred and consecutively evaluated by a multidisciplinary team comprising dental- and medical specialists and Pain Clinic staff. Prior to the first visit the patients completed a comprehensive questionnaire including, pain history, jaw function, lifestyle factors and validated measures of anxiety and depression. In addition, magnetic resonance images (MRI), orthopantomograms, and photographs were taken. The clinical examination included assessment of static/dynamic occlusion, jaw function and muscles tender to palpation. Facial sensitivity to light touch and pin-prick was examined, and sensitivity- and pain thresholds were measured with different devices. Pain intensity was scored on a numeric rating scale (NRS). The specialist consultations were planned for three separate appointments. At the final (4th) meeting the team had a dynamic feedback meeting with the patient presenting results and a treatment plan.

Results

So far 42 patients have been evaluated. Preliminary results show that females dominate (37:5), mean age 46 years. Fifty percent of the patients indicate trauma as the likely cause of TMD/TMJ, while 19% report general joint hypermobility. All have long-lasting pain histories (mean 12.8 years). Orofacial pain at rest occurred in 98% and pain on mandibular movement in 74%. Most of the patients had elevated scores on the mandibular functional index questionnaire. Maximum jaw opening was decreased in 57% of the patients (<40 mm). MRI showed osteoarthritis in 64%, most of them mild to moderate findings but 10% had severe osteoarthritis, with degenerative destructions in their joints. The disc was in 59% of the patients anteriorly displaced. 75% reported sleep disturbance. Almost all had elevated catastrophizing scores.

Conclusion

All patients have a long history of pain. Most of them suffer from impaired mandibular function in addition to pain. A majority report sleep disturbance, 1/3 have widespread pain, 50% score for anxiety and/or depression while almost all have elevated catastrophizing scores. Management of complex pain problems requires a multidisciplinary approach.

AUTOIMMUNITY DISEASES AND INFLAMMATORY CONDITIONS ARE ASSOCIATED WITH AN INCREASED RISK OF TMJD – A HOSPITAL BASED CASE CONTROL STUDY

Authors: Adrian Salinas Fredricson, DDS,¹ Farid Khodabandehlou, DDS,¹ Carina Krüger Weiner, DDS, PhD,¹ Aron Naimi-Akbar, DDS, PhD,¹ Johanna Adami, MD, PhD,² Annika Rosén,^{1,3} DDS, PhD

*1*Division of Orofacial Diagnostics and Surgery, Section of Oral and Maxillofacial Surgery, Department of Dental Medicine, Karolinska Institutet, Stockholm, Sweden; *Dept of Oral and Maxillofacial Surgery, Karolinska University Hospital, Stockholm, Sweden*

2 Clinical Epidemiology Unit, Department of Medicine, Karolinska Institutet, Stockholm, Sweden;

*3*Department of Clinical Dentistry, division of Oral and Maxillofacial Surgery, University of Bergen, Bergen, Norway;

email: aron.naimi-akbar@ki.se

Abstract

Aim

Temporomandibular joint disorders (TMJD) involve orofacial pain and functional limitations that disables important daily activities such as chewing and speaking. The purpose of this study was to investigate predictors of TMJD.

Material and methods

The study population consisted of patients with diagnosed TMJD, chronic closed lock (CCL) or painful clicking (PC), and treated surgically during the years 2007-2011 at the Division of Oral and Maxillofacial Surgery, Department of Dental Medicine, Karolinska Institute, Huddinge, Sweden. The control group was selected among patients that had undergone tooth extraction at the Department of Dental medicine, Karolinska Institutet, Huddinge, Stockholm, Sweden during the same period. The controls were randomly selected stratified on age and gender.

Results

A total number of 146 cases and 151 in the controls were included in the analyses. Response rate for the case group was 55.3% and 21.8% for the control group. The male/female ratio for patients suffering from TMJD was 1:4.4. There were significant associations between TMJD and pneumonia (odds ratio (OR), 2.1), asthma (OR, 2.1), allergies (OR, 1.8), headaches (OR, 3.1), general joint hypermobility (OR, 3.8), orofacial trauma (OR, 3.9), rheumatism (OR, 2.5) and orthodontic treatment (OR, 2.4) ($p < 0.05$ for all outcomes).

Conclusion

In conclusion the study indicates that autoimmunity diseases and inflammatory conditions are associated with an increased risk of TMJD. Moreover, lung affections seem to predict subsequent development of TMJD.

POSTER PRESENTATIONS THURSDAY 4 JUNE: P1 – P10

EXTREME ORAL MANIFESTATIONS IN A PATIENT WITH CROHN'S DISEASE

S.Afnan, B.B Herlofson.

Dep. Oral Surgery and Oral Medicine, Institute of Clinical Dentistry, University of Oslo, NORWAY. E-mail presenting author: *shoresht@tannlegeafnan.no*

Background

Crohn's disease is an inflammatory bowel disease that may affect any part of the gastrointestinal tract from the mouth to anus. The incidence of Crohn's disease in Europe is 6.3 per 100,000 person-years in 2010. Between 20-50% of these patients will experience oral manifestation.

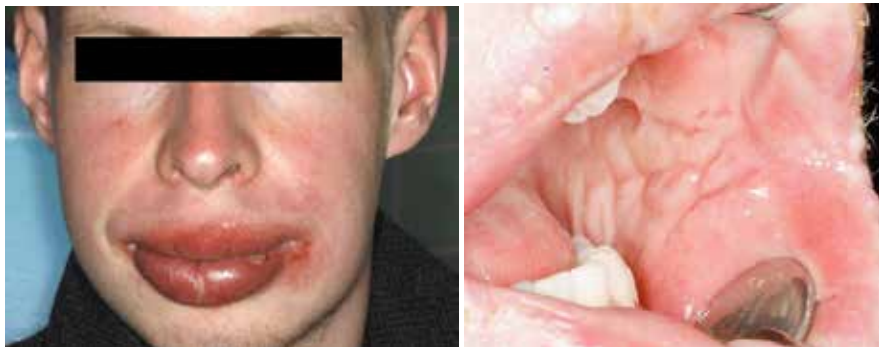Case report

A 25-year-old man was referred to our department of oral surgery and oral medicine, University of Oslo. He was diagnosed with Crohn's disease 6 months earlier and was under treatment at a nearby local hospital. The last 3 months he experienced severe swelling and soreness of both upper and lower lips. Clinical examination showed marked swelling, erythema, deep fissures and ulcerations of the lips. Cobblestone like appearance of the buccal mucosa bilaterally was seen. (Fig1)

The patient was undergoing treatment with immunosuppressive medication, Humira and Azathioprin with no effects on the oral manifestations. Due to this therapy, systemic corticosteroid treatment could not be given. Instead local corticosteroids and Low Level Laser Therapy (LLLT) in combination were tried. A positive effect on the ulcerations could be observed but not as much as we hoped for. When his intestinal conditions got better, the treating hospital physicians changed the immunosuppressive medication. First Humira was discontinued, and the patient was only on Azathioprin. Systemic corticosteroid was tried to alleviate especially his soar and swollen lips. Unfortunately this made his intestinal condition worse, and the corticosteroid therapy had to be discontinued together with Azathioprin. Humira injections were again introduced.

After a discussion with the treating physicians, we decided to try intralesional injection into the lips with Depo-medrol 40 mg/ml once every 3 weeks. After 6 weeks the lip swelling and the patients discomfort were reduced.

Conclusion: Oral manifestations in patients with systemic diseases may have great impacts on their oral health and wellbeing. The importance of a good collaboration between dental-and-medical health personnel in the management of such patients is demonstrated in this case report and results of the treatment so far will be presented.



IN VITRO ASSESMENT OF PRIMARY STABILITY OF BONE TRUST® SINUS IMPLANT DESIGN

Aydin Gülses*, **Mustafa Ayna****, **Metin Sencimen*****,
Matthias Gierloff****, **Yahya Açıll******

* Mevki Military Hospital, Centre of Dentistry and Oral Health, Ankara, Turkey

** Private Practice, Duisburg, Germany

*** Gulhane Military Medical Academy, Department of Oral and Maxillofacial Surgery, Ankara, Turkey

**** Christian Albrechts University, Department of Oral and Maxillofacial Surgery, Kiel, Germany

Presenting author:

Assoc. Prof. Dr. Aydin GULSES, Mevki Military Hospital, 06130 Diskapi Altindag, Ankara, Turkey

Phone: 00905326954048, Fax: 00903123114609, e-mail: aydingulses@gmail.com

**The authors would like to present their study as a poster.*

Aim Insufficient bone height involving the edentulous maxillary posterior region often presents a great challenge because of proximity to the maxillary sinus. Moreover, the ability to ensure high primary implant stability in a severely atrophied ridge is of chief concern. The BoneTrust® Sinus implant (BTSI) which was developed in cooperation with Dr. Kay Pehrsson at Haranni Clinic, Herne, in Germany, was introduced by Medical Instinct® (Medical Instinct Production GmbH, Bovenden, Germany) in 2011. According to the informations provided by the manufacturer, the BoneTrust® Sinus implant enables higher primary stability by its special design with reduced thread section in cases of reduced vertical bone availability, thus allowing in many cases a one-step operative procedure (augmentation and simultaneous implantation), even if less than 5mm of the bone level is available in the sinus region. The aim of this study was to analyze the primary stability of BTSI which suggested to enable higher primary stability by its special design with reduced thread section in cases of reduced vertical bone availability, in comparison with standart BoneTrust® implants (SBTIs) in vitro.

Material and methods A bone window of 3 cm (length) x 4 cm (widtht) x 3 cm (depth), resembling the maxillary bone window of the lateral sinus wall with a 4 mm of residuel bone height was prepared at the dorsal side of the freshly slaughtered bovine ribs. One single BoneTrust® Sinus implant and a single standart BoneTrust® implant in the same diameter (4 or 5 mm) was placed in each window. After implant placement, the ISQ was measured by using RFA with the Osstell device.

Results A total of 88 implants were placed. ISQ values varied between 63 to 84. Among the implants with 4 mm diameter, all BTSIs showed higher ISQ values compared to SBTIs. One-way ANOVA showed significant difference between BTSIs/SBTIs ($p<.05$). BTSIs with 4 mm showed statistically higher values compared to BTSIs with 5 mm diameter($p<.05$). Among the implants with 5 mm diameter, all SBTIs showed higher ISQ values compared to BTSIs but there was no significant difference.

Conclusion The use of BoneTrust® Sinus implants in 4 mm diameter could present higher ISQ values during simultaneous implant placement in conjunction with lateral sinus floor augmentation.

**“A NIGHT WITH VENUS, A LIFETIME WITH MERCURY”
- SYPHILIS, THE OVERLOOKED DISEASE**

Elisa Kier-Swiatecka

Elisa Kier-Swiatecka, Consultant, Dep. of OMS, Sydvestjysk Sygehus Esbjerg

Katrine Urth Hansen, Senior Registrar, Dep. of Clinical Diagnostics, Surgical Pathology, Sydvestjysk Sygehus Esbjerg

Jens Thorn, Head of Department, Ph.d., Dep. of OMS, Sydvestjysk Sygehus Esbjerg

Else Marie Pinholt, Professor, Dr. Odont., Consultant, Dep. of OMS, Sydvestjysk Sygehus Esbjerg

E-mail: *Elisa@Swiatecki.com*

Aim

Syphilis is a notifiable sexually-transmitted disease (STD) caused by the anaerobic spirochete bacteria, *Treponema Pallidum*. Since the turn of the century, there has been a significant increase in the number of cases of infectious syphilis. In 2008, 10 million cases were estimated worldwide by the World Health Organisation (WHO). In Denmark the number of cases reported has increased 10 fold between 2009 and 2013. Syphilis facilitates the transmission of HIV and other STDs. Men who have sex with men (MSM) constitute the largest risk group.

The oral cavity is the main location of extragenital primary syphilis but the disease is often overlooked or misdiagnosed as asymptomatic, non-specific oral ulceration.

Materials, methods and results

A 45-year-old male Caucasian was referred from his dentist for evaluation of persistent oral ulcerations. The appearance of the oral lesions was similar to that seen in erosive lichen planus, except for one. The differential diagnostic considerations will be presented. Only by correlating the patient's medical history with the clinical and histological evidence, was it possible to reach the diagnosis of oral syphilis. This was later confirmed by serological testing.

Conclusion

Oral syphilis is easily misdiagnosed with serious consequences for the patient. It is important, therefore, that clinicians have an understanding of the difficulties associated with the recognition of the disease in order to reduce the risk of transmission of not only syphilis but HIV also.

ORTHOGNATHIC SURGERY OR OPEN TEMPOROMANDIBULAR JOINT SURGERY IN OUTPATIENT SETTINGS

Göran Gynther, Måns Jungner, Mattias Ulmner

Department of Oral and Maxillofacial Surgery, Karolinska University Hospital, Stockholm, Sweden.

E-mail: goran.gynther@karolinska.se

Aim

To investigate the possibility to routinely perform orthognathic surgery or open temporo-mandibular joint (TMJ) surgery in office-based outpatient setting in order to save hospital resources.

Material and methods

During a six months period patients with treatment plans for Le Fort 1-osteotomy, surgical assisted rapid maxillary expansion (SARME), bilateral sagittal split osteotomy (BSSO) or TMJ discectomy were scheduled for outpatient surgery. Exclusion criteria were: ASA 3-4, BMI >35, blood pressure >150/80 or earlier anesthesia complications.

Results

Preliminary results indicate that the course of treatment was uneventful in the majority of the cases. Minor complications such as extended bleeding were seen in a few patients, affecting the time of discharge.

Conclusion

It seems possible to perform each of the investigated procedures in a safe, efficient, and cost effective way as an outpatient surgical procedure in order to save hospital and community resources.

WITHDRAWN

FIBROUS DYSPLASIA

Helle Baungaard Nielsen¹, Lars Nygaard Madsen¹, Daiva Erentaite², Thomas Jensen¹

¹*Department of Oral and Maxillofacial Surgery, Aalborg University Hospital, Aalborg, Denmark.*

²*Department of Pathology, Aalborg University Hospital, Aalborg, Denmark.*

Background: Fibrous dysplasia is a benign fibro-osseous lesion, characterized by a pathological replacement of normal bone by an excessive amount of benign fibrous tissue intermixed with irregular immature bony trabeculae. Fibrous dysplasia usually develops during childhood and early adolescence and stabilizes when skeletal maturity is reached. Growth of the lesion is usually slow and a painless swelling of the affected area is a common feature causing potential cosmetic deformity, displacement of teeth and functional problems. Depending of the nature and size of the lesion treatment varies from regular recall examinations to surgical intervention of the affected areas.

Case study: A twelve-year-old boy was referred to the Department of Oral and Maxillofacial Surgery, Aalborg University Hospital for diagnosis and treatment of an asymptomatic swelling in the upper jaw. Histological examination revealed the diagnosis of FD. The patient was treated with surgical contouring. At 2 years post-operative follow-up, the patient had no cosmetic or functional complains.

Conclusion: Fibrous dysplasia is benign fibro-osseous lesion with the jaws being among the most commonly affected sites. A long-term clinical and radiological follow-up is recommended considering development of FD can cause cosmetic and functional deformities, weakening of the bone with the risk of jaw fracture and in rare cases malignant transformation. At 2 years post-operative clinical and radiographical follow-up the patient showed stationary conditions.

ORBITAL COMPARTMENT SYNDROME AFTER FACIAL TRAUMA IN A PATIENT ON WARFARIN: A CASE REPORT

Lado Lako Loro¹, Lotte Erdmann²

¹Dept. of Oral & Maxillofacial Surgery, ²Dept of Ophthalmology, Aalesund Hospital, Moere and Romsdal Health Trust, Norway.

E-mail: lado.lako.loro@helse-mr.no / lado.loro@gmail.com

Aim: To report a case of orbital compartment syndrome after blunt assault injury to the left eye in a 58 year-old female on warfarin therapy.

Material and methods: CT-scans, ophthalmological evaluation, management of bleeding with human prothrombin complex (Octaplex), lateral canthotomy, inferior and superior cantholysis.

Results: Severe pain, a large, very firm and tender left periocular hematoma, closed left eyelids, proptosis, loss of vision, increased intraocular pressure (44 mm Hg), restricted eye motility, conjunctival edema and bleeding, mild hyperemia and venostasis. INR = 4,1 at admission. CT-scans showed intraorbital bleeding, periorbital oedema, mild exophthalmus and optic nerve stretching. Coagulation deficiency was managed with human prothrombin complex. Emergent canthotomy was attempted in local anesthesia but was aborted due to massive swelling and severe pain. Lateral canthotomy, inferior and superior cantholysis were performed in general anesthesia. On the first postoperative day the patient had light perception in the left eye but subsequent ophthalmological evaluations showed that the patient was blind in the left eye.

Conclusions: Coagulation deficiency and orbital compression were adequately managed in this case. Unfortunately, vision was permanently lost because of prolonged increased intraorbital compression. Orbital compartment syndrome is an uncommon ophthalmologic emergency that oral and maxillofacial surgeons should be well familiar with. Timely decompression of the orbit and globe by canthotomy and cantholysis is essential in the prevention of permanent loss of vision. Patients on anticoagulant therapy are at a higher risk for loss of vision.

UTILIZATION OF INTRAOPERATIVE NAVIGATION TREATING MAXILLOFACIAL TRAUMA

Iman Azarmehr DDS, Kasper Stokbro DDS, Torben Thygsen DDS phd

Oral and maxillofacial surgical resident at Odense University hospital, Denmark.

iman.azarmehr@rsyd.dk

Aim: To investigate the utility of intraoperative navigation in the field of maxillofacial trauma surgery for the last five years and present a relevant case of complex unilateral orbital secondary reconstruction.

Materials and methods: One patient referred to the maxillofacial department of Odense University hospital was treated for secondary orbital reconstruction. An earlier attempt to treat the patient had failed, resulting in a malpositioned titanium mesh traversing in to the lateral nose wall. The patient suffered from enophthalmus, diplopia and dystopia. The utilization of stereolithographic technique allowed the unaffected side to be mirrored and superimposed onto the affected side. In conjunction with this case, a systematic search of the literature for the use of intraoperative navigation for treatment of maxillofacial trauma was carried out. Databases such as the MEDLINE (pubmed), the Cochrane library and Embase were screened for relevant headlines published during the last five years using adequate medical subject heading (MeSH) terms in different combinations.

Results: The stereolithographic technique allowed the production of a custom made titanium mesh. The operation was carried out under general anesthesia via a transconjunctival approach. During a followed-up of six weeks the patient showed normalized conditions in terms of enophthalmus, diplopia and dystopia. The literature search produced a total number of 722 hits, out of those 27 headlines were regarded as relevant for screening of abstract. Nine articles were chosen for full screening. The majority of the articles were related to mid-facial trauma with orbital reconstruction dominating as a major indication for the utilization of intraoperative navigation.

Conclusions: Stereolithographic modeling has in this case shown to be a useful tool for complex secondary orbital reconstruction. Additionally, the literature search shows that intraoperative navigation can be an excellent tool when treating mid-facial trauma. The technique facilitates placement of osteosynthesis material, localization of important anatomic landmarks and/or alignment of severely displaced fractures.

DIFFERENTIATION ABILITY OF BMSCS AFTER TRANSPORTATION AND MANUFACTURING

Melanie Liesenfeld

M.Liesenfeld¹, C.G.Gjerde¹, S.Hellem¹, K.B.Mustafa¹

¹M.Liesenfeld, C.G. Gjerde, S. Hellem, K.B. Mustafa, Institute for clinical dentistry, University of Bergen, Bergen, NORWAY

Objectives: The objective of this work is to evaluate the ability of BMSCs harvested from patients to differentiate after a manufacturing and transportation procedure. How is the effect of transport directly on osteoblast, chondroblast and a dipocyte differentiation?

Methods: Harvesting of bone marrow was performed at Haukeland University hospital in Bergen, Norway and an aspirate was then shipped in a heparin solution at RT to the University hospital in Ulm, Germany, where several controls were executed before a cell culture was set up. The cells were conditioned in a proprietary medium without any animal proteins. After the expansion in a GMP environment with plasma lysate from human, the cells were sent back to the Department of clinical dentistry in Bergen, Norway. The cells were further cultivated either with D-MEM (high glucose), alpha-MEM, each with 15% FBS, or MesenCult medium with supplement and then differentiated into osteoblasts, adipocytes or chondroblasts, respectively.

Results: After the whole procedure of harvesting, transportation, manufacturing and transportation again, the cells were found to be in good condition. The adaption to the new conditions and further cultivation with FBS were well accepted by the cells. The verification of differentiation was done by histochemically staining with Alizarin Red S for osteoblasts, Oil Red O for adipocytes and Alcian Blue for chondrocytes. The cells, treated with differentiation medium either for osteogenic, adipogenic or chondrogenic differentiation, showed the typical staining, respectively, while the control group (treated with normal cultivation medium) showed no staining.

Conclusions: After harvesting, transportation, manufacturing procedure and cultivation with FBS, BMSCs keep their ability to differentiate. Even cultivation of the BMSCs with different media showed no negative effect to the differentiation ability.

TEETH ALIGNMENT IN MRI - EVALUATION OF A MARKER BASED METHOD

Jean-Marc Luukinen, Daniel Aalto, Naoko Niikuni, Päivi Jääsaari, Tero Soukka, Riitta Parkkola, Jani Saunavaara, Jarmo Malinen and Risto-Pekka Happonen

*Department of Oral and Maxillofacial Diseases, University of Turku, Finland
jean-marc.luukinen@utu.fi*

Aim

The long-term goal is to use a computational model to predict the changes in speech production due to anatomical changes in vocal tract. The anatomical parameters of the computational model are obtained by magnetic resonance imaging (MRI). However, the crowns of teeth, an important structure of vocal tract, are invisible in the MRI. In this study, the accuracy of a marker based teeth alignment method is evaluated.

Material and methods

Ten patients (6 male) undergoing orthognatic surgery were enrolled. Supraglottal airways were imaged preoperatively using structural MRI. Four vegetable oil impregnated and epoxy coated wooden markers were fixed bilaterally to the maxillary incisors and molars. Inter-marker distances were measured three times from the dental casts, the MRI of the dental casts, and the patient MRI. The differences between these measurements were compared using t-tests. Twenty repeated measurements of one patient MR images were done in order to evaluate the accuracy of the MRI measurements.

Results

Distances measured from the dental casts were 0.4 ± 1.1 mm larger than those measured from MRIs of the dental casts (t-test: $t=2.3$, $df=45$, CI: 0.1-0.8 mm) and 0.6 ± 1.2 mm larger than those between patient attached markers in MRI ($t=3.9$, $df=48$, CI: 0.3-0.9 mm). Patient MRI and dental cast MRI measurements were not significantly different ($t=-0.7$, $df=41$, CI: -0.5-0.3 mm). 18% of the measurements were missing because of a loose marker. Repeated measurements showed a standard deviation of 0.3 mm.

Conclusion

The markers are clearly visible in MRI. The marker localization showed systematically 0.5 mm smaller distances compared to dental cast measurements and the accuracy of the localization was 1.2 mm. To further evaluate the method, the vertical position of the markers in MRI with respect to the cranial landmarks will be compared with cephalogram.



POSTER PRESENTATIONS FRIDAY 5 JUNE: P11 – P20

DELAYED OPEN REDUCTION AND INTERNAL FIXATION OF A CONDYLAR NECK FRACTURE, IS IT POSSIBLE?

Blomlöf Johan

Dpt. of Oral and Maxillofacial Surgery, Aarhus University Hospital, Aarhus, Denmark. e-mail: perblo@rm.dk

Aim

The aim of this case presentation is to open the discussion to treatment possibilities and limitations when it comes to timing of treatment of fractures to the mandibular condylar neck.

Material and methods

A 57 year old man with spastic handicap who during a spastic episode had fallen and hit his chin. The patient was seen by his regular dentist 5 weeks after the incident, chief complaint was malocclusion. Clinical and radiographic examinations confirmed a fracture to the condylar neck on the right side. Open reduction and internal fixation was proposed and accepted by the patient. During the operation fibrous tissue as a sign of secondary bone healing was seen in the fracture area. Fibrous tissue was removed and fresh bone surfaces created by instrumentation. Postoperative IMF was not used.

Results

Postoperative follow up was uneventful. Subjectively the patient was satisfied with the treatment result. A stabile occlusion and good function was restored. Mouth opening of over 40 mm, was achieved and normal function of the facial nerve. Radiographs also showed signs of good bone healing in the fracture area.

Conclusion

Fractures to the condylar neck of the mandible are most often closed fractures. Closed fractures generally allow for more flexibility when it comes to timing of treatment. In the present case treatment was delayed mainly because the patient. Delayed treatment of fractures to the mandibular condylar neck is not optimal but may be possible.

PHOTODYNAMIC TREATMENT: AN ALTERNATIVE APPROACH IN THE MANAGEMENT OF ORAL LICHEN PLANUS

Juliane Hesse^{1,2}, Trond Warloe³, Sigrid I. Kvaal¹

¹*Faculty of Dentistry, University of Oslo, Oslo, Norway;* ²*The Public Dental Health Service of Troms, Tromsø, Norway;* ³*Oslo University Hospital, Oslo, Norway*

juliahes@student.odont.uio.no

Background:

Oral lichen planus (OLP) is a chronic immunologic mucocutaneous inflammatory disease affecting the oral mucosa. Such lesions rarely undergo spontaneous remission and are difficult to palliate. About two thirds of OLP patients report oral discomfort from mild burning sensations to severe pain affecting normal masticatory function. Conventional treatments of OLP are pharmacological with both topical and systemic corticosteroids. One side effect is candidiasis. Prolonged use of these drugs may occasionally result in diminished biological effectiveness.

Photodynamic treatment (PDT):

The agent 5-aminolevulinic acid (5-ALA) and its methylester (MAL) have been used for treatment of basal cell carcinomas and actinic keratosis. Photodynamic therapy is based on the accumulation of the photosensitizer protoporphyrin IX (PpIX) in premalignant or malignant cells. Upon illumination PpIX generates reactive oxygen species, which in turn kill the cells.

PDT may be an alternative approach to treat OLP in patients with severe symptoms. In PDT of OLP a topical application of MAL (Metvix®) is used in combination with light at 630nm to induce cell and tissue damage. In OLP the PpIX accumulates in the subcutaneous T-cells.

MAL appears to be more rapidly absorbed by T-cells, which dominate the histological picture of OLP. It is likely that the result of PDT is mainly caused by the effect on T-cells.

It has been shown that this treatment of OLP leads to a significant improvement after 6 months and seems to have good long-term results after only one treatment session. The therapy is easy to perform with little inconvenience to the patient and no registered side effects.

Case-report:

One case will be presented.

AMELOBLASTIC CARCINOMA

Kristian Thesbjerg, Jytte Buhl

DDS, Resident oral and maxillofacial surgery Dept of OMFS, Aarhus University Hospital and Dept of OMFS, Aalborg University Hospital

krisitan@thesbjerg.net

Aim: To present a rare case of ameloblastic carcinoma including reconstruction with a microvascular free fibula graft, and to provide a short review of the literature concerning ameloblastic carcinomas.

Material and methods:

A 58-year old woman was referred to the department of OMFS, Aarhus University Hospital with the initial diagnosis of osteomyelitis in the right mandible. At the first consultation a normal oral mucosa was observed and the dentition was partial with absence of the molars in the right side of the jaw. CT-scan showed destruction of trabecular and cortical bone in the right side of the mandibular ramus and corpus and remnants of the roots of an earlier coronectomized third molar. Soft tissue and hard tissue biopsies were taken. The biopsies showed squamous cell carcinoma of unknown origin. At a multidisciplinary treatment conference with oncologists, ENT surgeons, plastic- and maxillofacial surgeons a total resection of the right mandible and the surrounding soft tissue and reconstruction with a microvascular free fibular graft, was planned. The required reconstruction included replacement of bone from the right mandibular condyle, mandibular ramus and corpus to the canine area. By use of a 3D-model of the mandible the resection was simulated and a titanium reconstruction plate was prepared. The surgical treatment was carried out in cooperation between the ENT surgeons, plastic - and maxillofacial surgeons.

Results

Treatment of the patient with resection and free fibula graft was carried out successfully. The patient had normal neuromuscular and neurosensory function 6 weeks postoperative, though with parasthesia at the innervation area of the right inferior alveolar nerve. The occlusion on the remaining dentition was also found fully acceptable, and range of motion was 35 mm 6 weeks postoperative.

Conclusion

Treatment of ameloblastic carcinoma requires radical resection including both hard and soft tissue, and therefore the use of micro vascular graft is often mandatory to reconstruct the continuity of the mandible. In this case an acceptable shape of the mandible and function was established.

CASE REPORT: UNUSUAL ORO-FACIAL INFECTION CAUSING PATHOLOGIC FRACTURE OF THE MANDIBULAR CONDYLE

Linderup ML, Helleberg M, Schytte S, Pikelis A, Nørholt SE

Trainee at the Department of Oral and Maxillofacial Surgery, Aarhus University Hospital, Denmark, metkli@rm.dk

Aim: To describe and analyze an unusual and serious infection developed after tooth extraction.

Material and Methods: A 46-years old man was referred to the Department of Oral and Maxillofacial Surgery, Aarhus University Hospital with a severe oro-facial infection after tooth extraction in the left side of the mandible. At first hand he denied treatment at the hospital, but one month later the infection had escalated dramatically, and he accepted treatment. The infection had caused an extensive abscess formation including compression of the airways, depression of the internal jugular vein and a pathologic fracture of the mandibular condyle. The severe swelling and the aggressive behavior gave rise to suspicion of malignancy and therefore the treatment was performed in collaboration with specialists in otolaryngology. The surgical procedure included drainage, extraction of one molar, biopsies of soft tissue and bone and debridement by both intraoral and extraoral approach.

Results: The biopsies showed no signs of malignancy. A cultivation of pus from the abscess revealed coagulase negative staphylococci and the infection was successfully treated. The fracture was managed with a non-surgical approach. Clinical control 8 weeks postoperative showed healing of all cicatrices, normal occlusion of the teeth and good mobility of the jaw. Next control is planned for April 2015.

Conclusion: This case report details the examination and management of an unusual oro-facial infection and the reflections about the cause and differential diagnoses.

TREATMENT OF AN UNICYSTIC AMELOBLASTOMA IN THE MAXILLA IN A 67-YEARS OLD MALE

Nicolai Paaske, DDS, Jytte Buhl, DDS.

*Department of Oral and Maxillofacial Surgery, Aarhus University Hospital, Denmark,
e-mail: nicopaas@rm.dk.*

Aim:

The ameloblastoma is the most common, clinically significant odontogenic tumor of the maxillofacial region. Ameloblastomas are tumors of odontogenic epithelial origin, and are slow-growing, locally invasive tumors that run a benign course in most cases. Ameloblastomas have been categorized broadly into 3 clinical / radiological variants: unicystic variant, solid or multicystic variant and peripheral or extraosseous variant. Ameloblastomas are rarely seen in the maxilla. The unicystic ameloblastoma is a rare and less aggressive variant of the tumor. It is often seen in younger patients, and seldom in the maxilla. Because of a local aggressive growth and a relatively high rate of recurrence, the treatment of choice is radical resection. The aim of this presentation is to describe a case of unicystic ameloblastoma in the maxilla and a soft tissue preserving treatment of the tumor. The rate of recurrence related to different ways of treatment will be discussed.

Material and methods:

A 67-years old male diagnosed with a unicystic ameloblastoma in the right premolar region of the maxilla. 5,4,3+ (15, 14, 13) was extracted and the mucosa allowed to heal properly to preserve the attached gingiva in the region. The tumor was afterwards treated with en bloc resection, and iliac graft reconstruction was made. After osseous healing implants were inserted and prosthetic reconstruction made.

Results:

The attached gingiva in the region was successfully preserved, which made it possible to achieve a good aesthetic and functional outcome of the implant and prosthetic treatment in the grafted area. The patient is controlled regularly for recurrence, and no signs of recurrence are seen two years postoperatively.

Conclusion:

Extracting teeth and waiting for proper soft tissue healing in a region where resection of a benign tumor is planned, can give the effect of better outcome, functionally and aesthetically, of the implant and prosthetic treatment. It is important to control the patient for recurrence of the tumor for a long period of time.

SURGICAL DECOMPRESSION OF RETROBULBAR HAEMORRHAGE VIA A MEDIAL EYEBROW APPROACH: TECHNICAL NOTE AND A 3-PATIENT SERIES

Oscar Hammarfjord, Kelly Podlosky, and Leo F. A. Stassen

National Maxillofacial Unit, St James's Hospital, James's Street, Dublin 8, Ireland.

oscar.hammarfjord@gmail.com

Aim

Retrobulbar haematoma (RBH) can result from trauma, surgical procedures involving the orbit, and retrobulbar injections. While RBH is relatively uncommon, it is a surgical emergency and delay in definitive treatment can result in permanent complete loss of vision. We describe the management of three patients that presented with RBH following trauma.

Material and methods

All patients presented, within an 11-month period, with medially located RBH following a fracture of the medial orbital wall. The diagnosis was made clinically and was confirmed using computer tomography (CT). The haematomas were decompressed using a medial approach, which in contrast to the more frequently described lateral canthotomy and inferior cantholysis, deals with the pathology directly by draining the haematoma and results in a good aesthetic outcome. The procedure was performed in the emergency room under local anesthesia and sedation. A 15mm V-shaped incision was made about 1cm superomedial to the globe. The orbital rim was identified followed by blunt dissection in a posterior direction, using a “mosquito” artery forceps, along the medial orbital wall to about 25mm where the haematoma was encountered and evacuated. The incision was left open to allow drainage. A lateral canthal incision was made and with gentle dissection a lateral cantholysis was performed through a 5mm incision (blunt dissection) using a “mosquito” artery forceps.

Results

Post-treatment ophthalmological assessment was performed during the week following the event as well as after 3 months. Vision was preserved in all three patients, although it was decreased in one patient due to delay in treatment.

Conclusion

When the RBH is medially positioned we found that a medial approach is a simple, safe, and effective way to manage this potentially sight-threatening condition.

CASE REPORT: ORAL SYPHILIS A POSSIBLE REEMERGING INFECTION PROMPTING CLINICIAN ALERTNESS

Sebastian Dybeck Udd, Bodil Lund

Dep of Oral and Maxillofacial Surgery, Karolinska University Hospital, Stockholm, Sweden

Introduction

Syphilis is rare disease in industrialized countries. However, surveillance data from the Public Health Agency of Sweden shows a 37 % increase of reported cases of syphilis between year 2012 and 2013. The increasing incidence, in combination with changing sexual habits, indicates a possible reemergence of oral manifestations of this infection. Therefore, clinicians need to be aware that ambiguous oral manifestations may in fact be caused by oral syphilis.

Case report

Here we present a case of oral syphilis with extensive diagnostic delay. Over a 6 month period the patient sought health care repeatedly and was examined by five different medical doctors ranging from general practitioners, emergency care doctors and an ENT (ear-, nose and throat) doctor. During this period the patient was misdiagnosed with fungal infections on three occasions, twice told he had aphthous stomatitis and three times informed that his oral lesions were stress-related. He received repeated courses of anti-fungal treatment and topical corticosteroid treatment without improvement. Despite the patient's own request, he was denied a referral to a STD-clinic with the motivation that aphthous stomatitis was strongly suspected.

After 6 months of increasing complaints and severity of disease the patient was referred to an oral and maxillofacial surgeon where the correct diagnose received. With treatment of intra-muscular injections of benzyl-penicillin the patient symptoms quickly subsided.

Conclusion

This case high-light the importance that oral mucosal lesions of unclear origin, or not responding to standard treatments, should be referred to an oral and maxillofacial surgeon.

MMF SCREWS IN TREATMENT OF MANDIBULAR FRACTURES

Vlad Florescu¹, Vlad Florescu, Thomas Kofod², Else Marie Pinholt³

¹*Ph.D Fellow at University of Copenhagen Institute of Clinical Medicine*

²*DDS, Ph.D and Head of Department at Department of Oral and Maxillofacial Surgery
Univeristy Hospital of Rigshospitalet, Copenhagen, Denmark*

³*DDS, MS, dr.odont, Professor at Department of Oral and Maxillofacial Surgery at Sydvestjysk
Hospital, Esbjerg, Denmark*

vaflorescu@hotmail.com

Aim: The aim of this study was, to investigate the morbidity using MMF screws in treatment of mandibular fractures, at the University Hospital of Rigshospitalet, Copenhagen Denmark. A literature review regarding iatrogenic damage caused by mandibulo-maxillary fixation screws was carried out in February 2015. The results were compared to the literature review.

Material and methods: Patient charts with SKS diagnosis code DS026 from the year 2007 to August 2013 were extracted at the Department of Oral & Maxillofacial Surgery at the University Hospital Rigshospitalet, Copenhagen for this study. Fracture type, X-rays, treatment modality, MMF screw type and total number were registered. A search was likewise carried out on the Databaseses Pubmed and the Cochrane Library in February 2015 using the following keywords and Mesh-words alone and in combination with one another: *IMF screw, MMF screw, Intracortical bone screw, Intermaxillary fixation, Mandibulo maxillary fixation, maxilla mandibular fixation, mandibular fractures*. Abstracts were handled according to inclusion/exclusion criterias by the authors authors VF and EMP and included articles were obtained and handled in full text

Results: The current study is based on a patient population of 159 in the period 2007-2013. Results will be discussed according to the following parameters and complications: iatrogenic root damage, periapical periodontitis as result of root damage, achievement of habitual occlusion, midline deviation, healing of fracture, screw loosening, loss of screw, infection as result of screw insertion, and iatrogenic nerve damage as result of screw insertion.

Conclusion: Based on the current material and a literature review, MMF-screws seem to be a valid alternative to arch-bars in reduction of mandibular fractures.

RETROSPECTIVE STUDY ON MAXILLOFACIAL FRACTURES OPERATED AT AALESUND HOSPITAL

Lado Lako Loro¹, Espen Helgeland², Ida M. Dahle², Jan Inge Leira¹

¹*Dept. of Oral & Maxillofacial Surgery, Aalesund Hospital, Moere and Romsdal Health Trust, Norway,* ²*Dept. of Oral Surgery & Oral Medicine, Univ. of Bergen, Bergen, Norway*

E-mail: lado.lako.loro@helse-mr.no / lado.loro@gmail.com

Aim: Analyses of demographics, aetiology and complications in patients operated for maxillofacial fractures at Aalesund Hospital 2002-2009.

Material and methods: Data was collected from journals of patients operated for maxillofacial fractures in the period 1st January 2002 to 31st December 2009. PASW Statistics 18 software (SPSS, IBM, USA) was used for statistical analyses. The level of statistical significance was set at $p < 0.05$.

Results: A total of 188 fractures in 139 patients were surgically treated in the study period. The male to female ratio was 3.6:1 and the mean age 35.7 ± 17.2 years. Males were significantly younger than females ($p < 0.05$). Mandibular (52.7 %) and zygomatic complex fractures (33.5 %) were the most frequent. Most patients (41.7 %) sustained their injuries as a result of interpersonal violence (IPV) followed by falls (25.9 %) and traffic accidents (15.8 %). Significantly more males were victims of IPV ($p < 0.05$). Almost half of the female cohort sustained their injuries by falling. More than half of those who sustained their injuries between midnight and morning were intoxicated. The majority of cases were treated by open reduction and internal fixation (56.8%). Posttraumatic and postoperative complications were seen in 25 % of patients, with infection (8.6 %) occurring most frequently.

Conclusions: Mandibular and zygomatic complex fractures were the most frequent in our study. IPV in association with alcohol and drugs was a major cause of maxillofacial fractures, especially among young adult males. Falls were the predominant cause of fractures among females.

ORTHODONTIC CLOSURE IN THE ANTERIOR REGION MAINTAINING THE FACIAL PROFILE, A WAY OF AVOIDING PROBLEMS WITH IMPLANTS

Salaheddin Omar Abbas¹ and Rannvá Matras²

¹*Regional orthodontic unit, Region Sealand, Denmark*

²*Department of Otorhngolaryngology and Maxillofacial Surgery, Koege Hospital, Denmark*

Email of presenting author: s_abbass@yahoo.com

Aim

This presentation will illustrate an alternative to implants as a substitute in the region of agenesis. Closing the space by the help of temporary anchorage devises is well known and well described in the literature. Never the less, improvements in the technical and biomechanical protocols are in very fast development. Some of the most modern and effective techniques will be illustrated with clinical pictures. The main aim is to demonstrate an actual alternative to the implant solution to resolve the problem of agenesis, which can be of superior results when indicated.

Materials and Method

Several cases and results will be presented. Cases shown were taken from the orthodontic clinic in Region Sjælland. Skeletal anchorage devices have been the main supplement for treatment biomechanics. The most modern technology is demonstrated, never the less the improvement and the refinement of the treatment protocol is still ongoing. Results shown are directly after the finish of orthodontic treatment and before any prosthetic adjustments.

Results

Very reasonable functional and esthetic results have been achieved. The occlusion was stable with good intercuspitation. Good support for the lips and the soft tissues has been planned and established. The agenesis was not a factor when deciding the position of the incisors, as tooth movement was completely controlled by the temporary anchorage appliance. Soft tissue support and patients profiles were very comparable to cases treated with implants. Many patients have decided not to do any prosthetic adjustments after the orthodontic treatment despite our recommendation, as most patients were satisfied with the end product. The average treatment time was not increased compared to the implant option. Treatment time was about two years in most patients. Faster treatment time was not the result of faster tooth movement, but rather due to the elimination or reduction of the biomechanical side effects.

Conclusion

Closing the agenesis by the use of the most modern technologies and protocols of temporary anchorage devices is a very powerful and effective treatment modality. This is the most biological solution, as well as the cheapest both for the patient and the society as a whole. This option should be evaluated and considered for every patient suffering from agenesis. Satisfactory functional and esthetic results can be achieved and has been documented. Never the less, careful choose of patients as well as thorough information for the patient about the expected results, advantages and disadvantages are mandatory for satisfactory results.



Congress secretariat SFOMK
congress.denmark@resia.com
Phone +46 (0)18-18 35 35

More than
primary stability.
The new tapered standard.



The perfect symbiosis of design, material and surface –
the Straumann® Bone Level Tapered Implant:

- Roxolid® material – Reducing invasiveness with smaller implants
- SLActive® surface – Designed to maximize your treatment success and predictability
- Apically tapered – Excellent primary stability even in compromised bone situations
- CrossFit® connection – Simplified handling, legacy of Bone Level System

In combination with:

www.nordic.straumann.com

