



Aalborg Universitet

AALBORG UNIVERSITY
DENMARK

Vertebral defect, anal atresia, cardiac defect, tracheoesophageal fistula/esophageal atresia, renal defect, and limb defect association with Mayer-Rokitansky-Küster-Hauser syndrome in co-occurrence

two case reports and a review of the literature

Bjørsum-Meyer, Thomas; Herlin, Morten; Qvist, Niels; Petersen, Michael B

Published in:
Journal of Medical Case Reports

DOI (link to publication from Publisher):
[10.1186/s13256-016-1127-9](https://doi.org/10.1186/s13256-016-1127-9)

Creative Commons License
CC BY 4.0

Publication date:
2016

Document Version
Publisher's PDF, also known as Version of record

[Link to publication from Aalborg University](#)

Citation for published version (APA):

Bjørsum-Meyer, T., Herlin, M., Qvist, N., & Petersen, M. B. (2016). Vertebral defect, anal atresia, cardiac defect, tracheoesophageal fistula/esophageal atresia, renal defect, and limb defect association with Mayer-Rokitansky-Küster-Hauser syndrome in co-occurrence: two case reports and a review of the literature. *Journal of Medical Case Reports*, 10(1), [374]. <https://doi.org/10.1186/s13256-016-1127-9>

General rights

Copyright and moral rights for the publications made accessible in the public portal are retained by the authors and/or other copyright owners and it is a condition of accessing publications that users recognise and abide by the legal requirements associated with these rights.

- ? Users may download and print one copy of any publication from the public portal for the purpose of private study or research.
- ? You may not further distribute the material or use it for any profit-making activity or commercial gain
- ? You may freely distribute the URL identifying the publication in the public portal ?

CASE REPORT

Open Access



Vertebral defect, anal atresia, cardiac defect, tracheoesophageal fistula/esophageal atresia, renal defect, and limb defect association with Mayer-Rokitansky-Küster-Hauser syndrome in co-occurrence: two case reports and a review of the literature

Thomas Bjørsum-Meyer^{1,2*}, Morten Herlin³, Niels Qvist^{1,2} and Michael B. Petersen^{3,4}

Abstract

Background: The vertebral defect, anal atresia, cardiac defect, tracheoesophageal fistula/esophageal atresia, renal defect, and limb defect association and Mayer-Rokitansky-Küster-Hauser syndrome are rare conditions. We aimed to present two cases with the vertebral defect, anal atresia, cardiac defect, tracheoesophageal fistula/esophageal atresia, renal defect, and limb defect association and Mayer-Rokitansky-Küster-Hauser co-occurrence from our local surgical center and through a systematic literature search detect published cases. Furthermore, we aimed to collect existing knowledge in the embryopathogenesis and genetics in order to discuss a possible link between the vertebral defect, anal atresia, cardiac defect, tracheoesophageal fistula/esophageal atresia, renal defect, and limb defect association and Mayer-Rokitansky-Küster-Hauser syndrome.

Case presentation: Our first case was a white girl delivered by caesarean section at 37 weeks of gestation; our second case was a white girl born at a gestational age of 40 weeks. A co-occurrence of vertebral defect, anal atresia, cardiac defect, tracheoesophageal fistula/esophageal atresia, renal defect, and limb defect association and Mayer-Rokitansky-Küster-Hauser syndrome was diagnosed in both cases.

We performed a systematic literature search in PubMed ((VACTERL) OR (VATER)) AND ((MRKH) OR (Mayer-Rokitansky-Küster-Hauser) OR (mullerian agenesis) OR (mullerian aplasia) OR (MURCS)) without limitations. A similar search was performed in Embase and the Cochrane library. We added two cases from our local center.

All cases ($n = 9$) presented with anal atresia and renal defect. Vertebral defects were present in eight patients.

Rectovestibular fistula was confirmed in seven patients. Along with the uterovaginal agenesis, fallopian tube aplasia appeared in five of nine cases and in two cases ovarian involvement also existed.

(Continued on next page)

* Correspondence: thomas.bjoersum-meyer@rsyd.dk

¹Department of Surgery, Odense University Hospital, Sdr. Boulevard 29, Odense C 5000, Denmark

²University of Southern Denmark, Campusvej 55, Odense M 5230, Denmark

Full list of author information is available at the end of the article



(Continued from previous page)

Conclusions: The co-occurrence of the vertebral defect, anal atresia, cardiac defect, tracheoesophageal fistula/esophageal atresia, renal defect, and limb defect association and Mayer-Rokitansky-Küster-Hauser syndrome is extremely rare. This group of patients has unusual phenotypic characteristics. The long-term outcome after treatment of defects is not well reported. A single unifying cause is not known and the etiology probably includes both genetic and non-genetic causes. We stress the importance of future studies to optimized treatment, follow-up, and etiology.

Keywords: Congenital abnormalities, Syndrome association, VACTERL association, Mullerian aplasia, Rare diseases

Background

The vertebral defect, anal atresia, cardiac defect, tracheoesophageal fistula/esophageal atresia, renal defect, and limb defect (VACTERL) association and Mayer-Rokitansky-Küster-Hauser (MRKH) syndrome are rare conditions. The co-occurrence of the VACTERL association and MRKH syndrome is extremely rare and has only been casuistically reported. Even with optimal surgical corrections of malformations, patients affected by the VACTERL association can face medical challenges throughout life such as back pain (scoliosis), fecal incontinence (anal atresia, AA), and functional impairment (limb anomalies) [1]. The medical challenges are highly dependent on type and severity of the specific malformation. Women affected by the MRKH syndrome are unable to bear children and the syndrome may have a long-lasting negative impact on their level of psychological distress and self-esteem [2]. Reporting cases of rare conditions is important to expand knowledge on possible etiological factors, treatment, and outcome. We have treated two patients at our center with the VACTERL association and MRKH co-occurrence, which add further knowledge to the condition. To the best of our knowledge a possible embryologic or genetic cause in the development of the VACTERL association and MRKH syndrome has not been addressed in the literature so far. We aimed to collect existing knowledge in embryopathogenesis and genetics in order to discuss a possible link between two rare disease entities.

Our objectives were:

- To present two cases with the co-occurrence of the VACTERL association and the MRKH syndrome from our surgical center.
- To perform a systematic review of the literature to detect cases with the co-occurrence of the VACTERL association and the MRKH syndrome in order to characterize patients regarding clinical presentation, outcome, and treatment.
- To discuss possible embryopathogenesis and genetics in patients with the co-occurrence of the VACTERL association and the MRKH syndrome.

VACTERL association

VACTERL association (Online Mendelian Inheritance in Man, OMIM, 192350) is the co-occurrence of birth defects including vertebral defect, AA, cardiac defect, tracheoesophageal fistula (TEF)/esophageal atresia, radial and renal dysplasia, and limb defects. It is generally accepted that the diagnostic criteria are the occurrence of at least three of the mentioned birth defects. The prevalence has been estimated to be 1:10,000 to 1:40,000 in live births [3–5]. Most cases of VACTERL appear sporadic although familial occurrence has been described. Genetic factors have been proposed but so far no single gene mutation or chromosomal anomaly has been identified as the unifying cause [6]. Vertebral anomalies have been reported in 60 to 80% of patients [7–12] and are often accompanied by rib anomalies. Typical vertebral anomalies are hemivertebrae, vertebral fusions, and supernumerary or absent vertebrae. There was a great variety in the reports of the severity of vertebral malformations [9, 12]. A common clinical presentation is scoliosis [13]. AA is reported in 55 to 90% of patients with VACTERL association [7–11]. In contrast to vertebral anomalies, AA is often recognized during the immediate clinical examination after birth. In more subtle cases AA may present later as constipation, which appears in up to 21% of the patients [14]. Some clinicians require an imperforate anus to address it as a VACTERL association while others allow minor AA to be included. Cardiac malformations are also common and observed in 40 to 80% of patients [9–11]. They range from life-threatening malformations, which require complicated surgical procedures, to small asymptomatic defects which are discovered incidentally [10, 11, 13]. A persistent ductus arteriosus and foramen ovale should not be registered as a defect in the VACTERL association [1]. TEF is reported in 50 to 80% of patients with VACTERL [7–11]. TEF is a potentially life-threatening condition and often requires surgery in the first few days of life. The prevalence of renal malformations is 50 to 80%, of which there is a great variation in severity [8–11]. They present as horseshoe kidney, cystic kidney, dysplastic kidney, or unilateral or bilateral agenesis. Limb anomalies are

traditionally defined as radial anomalies including aplasia/hypoplasia of the thumb. Other limb anomalies have also been described, for example anomalies of lower extremities. They are reported in 40 to 50% of patients with VACTERL [3, 7, 8, 10, 12, 15]. The first sign of the VACTERL association may be the presence of a single umbilical artery diagnosed prenatally and this finding should lead to a comprehensive examination for other defects in the VACTERL association [16, 17].

MRKH syndrome

MRKH syndrome (OMIM 277000) is a congenital disorder of the Müllerian ducts, characterized by agenesis or aplasia of the uterus and upper two-thirds of the vagina in females with normal secondary sex characteristics (thelarche and pubarche) and a normal karyotype (46,XX) [18]. Prevalence has been estimated to be 1 in 5000 live female births [19, 20] and MRKH syndrome is considered the second most common cause of primary amenorrhea after ovarian failure [21]. Patients typically present in their adolescence with complaints of primary amenorrhea; however, other complaints include lower abdominal pain, dyspareunia, and infertility. MRKH syndrome is classified into three groups [22]: type I/typical MRKH is characterized by isolated uterovaginal agenesis, type II/atypical MRKH is associated with renal and ovarian malformations, and the third type is Müllerian duct aplasia, renal aplasia, and cervicothoracic somite dysplasia (MURCS; OMIM 601076) association with renal, skeletal, and cardiac malformations, and hearing impairment. However, the definition and application of this classification in the literature are still inconsistent. The cause(s) of MRKH syndrome still remains unknown. Reports of discordance in monozygotic twins have suggested a non-genetic etiology. Previously, diethylstilbestrol (DES) and thalidomide were suspected as possible teratogenic causes [23, 24]; however, increasing reports of familial occurrence of MRKH syndrome and its associated extragenital malformations [25] have led to several investigations searching for a genetic etiology. Most studies conducted so far have found no clear association. Mutations in the *WNT4* gene have been associated with uterovaginal agenesis in virilized females [26] – an entity believed to be different from the MRKH syndrome. The management of MRKH syndrome involves counselling about the functional and psychosexual impacts and the creation of a neovagina in order to allow sexual intercourse. The American College of Obstetricians and Gynecologists (ACOG) recommends vaginal dilatation as first choice therapy due its few complications, but several other surgical procedures are also being used [27].

Case presentation

Patient medical report – case 1

A white girl was delivered by caesarean section at 37 weeks of gestation due to suspected mechanical disproportion. Her family history was without known in-born abnormalities and consanguinity. Her birthweight was 2600 g and her Apgar scores were 10/1 and 10/5. A physical examination revealed AA. An analysis of the prenatal amniotic fluid showed a normal female karyotype. Prenatal ultrasound (US) showed left-sided renal cysts and a TEF was suspected. Plain X-ray indicated esophageal atresia with TEF and high AA. Meconium was observed from her vaginal introitus. A colostomy was opened during her first day of life together with an end-to-end anastomosis of her esophagus and closure of the TEF. Ultrasonography during her fifth day of life showed a left hydronephrosis and three communicating renal cysts with a normal right kidney. A renography performed at 2 years of age showed no function of her left kidney. A late posterior sagittal anorectoplasty (PSARP) was performed when she was 3-years old. Perioperatively a vaginal aplasia was found and no uterus was found. Two months after the PSARP the colostomy was closed and a left nephrectomy performed. She developed a thoracolumbar scoliosis confirmed by a computed tomography (CT) scan (Fig. 1) which was corrected during childhood and adolescence through several operations. At the age of 15 years vaginal dilations treatment was started. At 20 years of age she was admitted to hospital with lower abdominal pain. A transvaginal US showed an abscess at her vaginal top, which was treated with transvaginal drainage and antibiotics. The following 4 weeks were uneventful and it was decided to attempt a surgical extension of her vagina. The procedure was complicated by a lesion of her bladder neck which was treated conservatively with a urethral catheter for 4 weeks without further complications. A magnetic resonance (MR) scan afterwards showed no restoration of the abscess. Her left ovary was absent and her fallopian tube appeared rudimentary on the left side. A normal ovary was documented on her right side. In 2015 at the age of 22 years a new attempt at dilations was made, which was now preceded by a small incision at the top of her vaginal pouch. The dilation treatment resulted in an 8 cm-long vagina.

She fulfilled the criteria for VACTERL association with vertebral anomalies, AA, TEF, and kidney defect. Her diagnostic criteria for MRKH syndrome were aplasia of the vagina, absent uterus, and a multicystic dysplastic left kidney.

Patient medical report – case 2

A white girl born at a gestational age of 40 weeks with a birthweight of 3088 g presented with AA (Fig. 2) and a

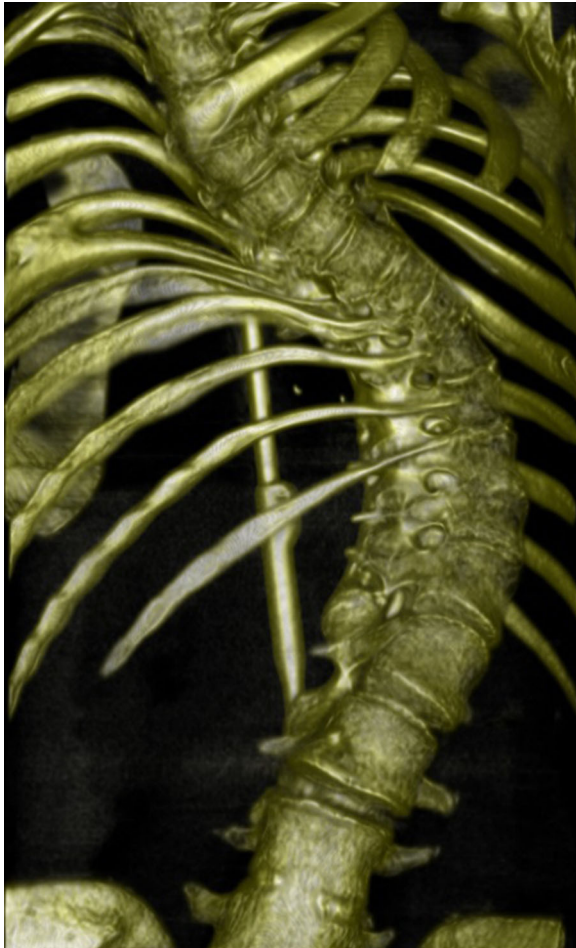

Fig. 1 Case 1, computed tomography reconstruction of the spine showing a thoracolumbar scoliosis

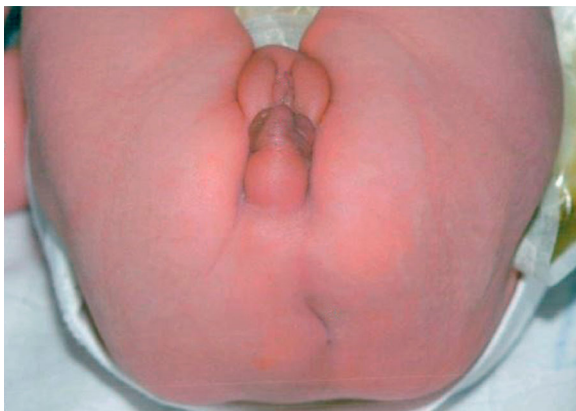

Fig. 2 Case 2 (6-days old), clinical photograph of the patient in the supine position showing an absent anus. Fistula opening is not presented

fistula opening near her vaginal introitus. Her family history was without known inborn abnormalities and consanguinity. Her Apgar scores were 8, 9, and 10 after 1, 5, and 10 minutes respectively. The pregnancy was uneventful. A diverging colostomy was created at 11 days of age. Perioperatively a remnant of vagina was found and the uterus was absent. Normal fallopian tubes and ovaries were demonstrated on both sides. A duplex kidney was found on her right side with hydroureter. A severe sacral dysgenesis was suspected clinically. She had a normal karyotype. PSARP was performed at the age of 4 months. After 6 months the colostomy was closed. A MR scan at 21 months of age revealed a tethered spinal cord and an intradural lipoma from L4 to S2.

Despite dietary restrictions and laxatives our patient had chronic constipation and an appendicostomy for antegrade colonic enema was created at 7 years of age. She continued to have abdominal pain, nausea, and vomiting. A sigmoidoscopy showed a siphon-like configuration at her colonic anastomosis; therefore, it was decided to perform a resection of her anastomotic colon, which was complicated by anastomotic leakage necessitating an intermittent diverting colostomy.

Her criteria for the VACTERL association were tethered cord and sacral scoliosis, AA, and duplex kidney. Absent uterus and proximal vaginal agenesis were diagnostic for MRKH syndrome.

Discussion

Search strategy and data collection

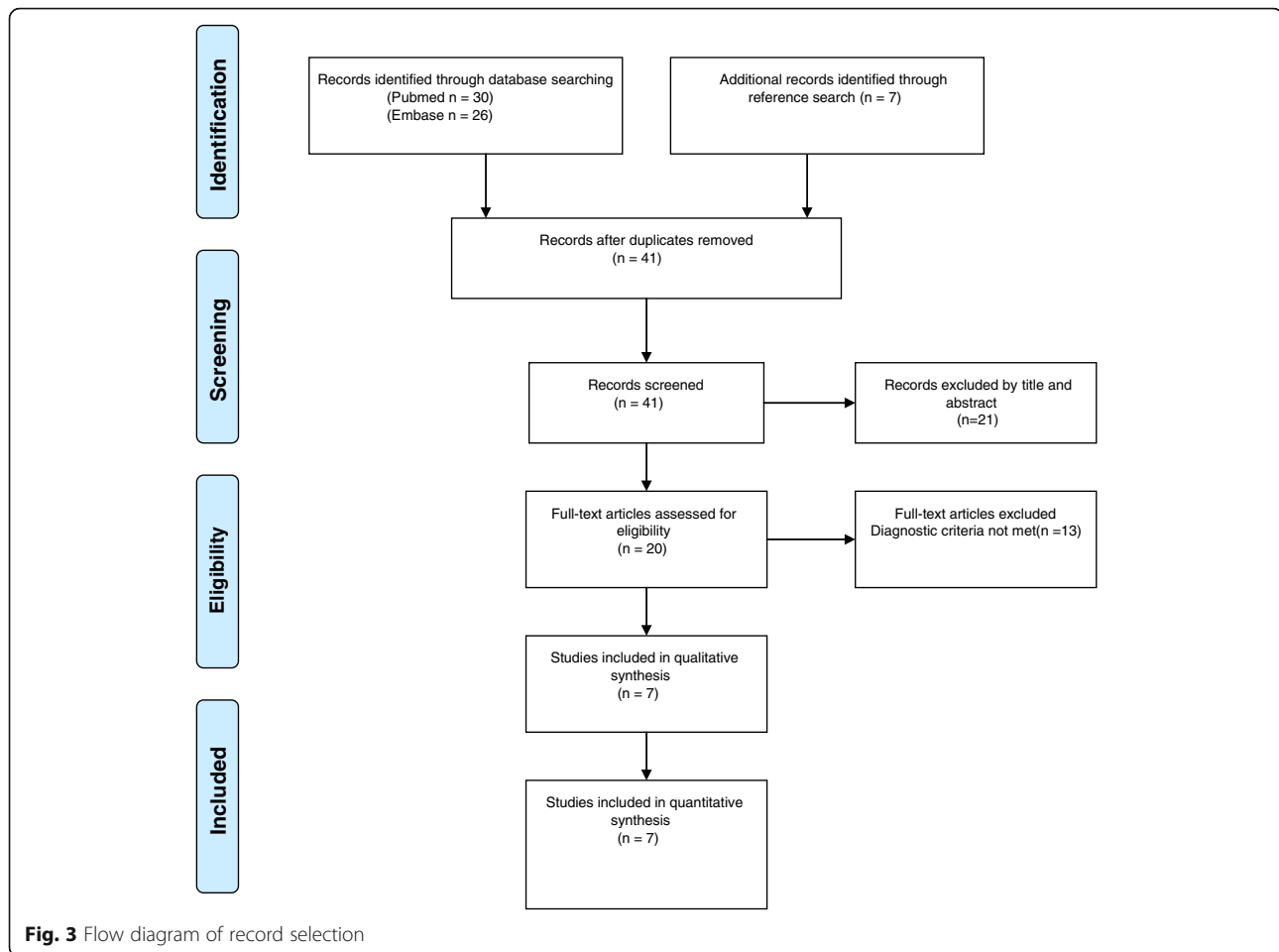
A literature search was conducted in the PubMed database using the following search terms: ((VACTERL) OR (VATER)) AND ((MRKH) OR (Mayer-Rokitansky-Küster-Hauser) OR (mullerian agenesis) OR (mullerian aplasia) OR (MURCS)) from inception to 18 September 2015 (Fig. 3) without limitations. A similar literature search was performed in Embase and the Cochrane Library. Furthermore a reference search was made. Identified cases are shown in Table 1. Three authors were contacted regarding further information on their cases and one responded. To be included, the cases had to meet the diagnostic criteria for both the VACTERL association and MRKH syndrome and not fulfill the criteria for other syndromes or associations. Karyotype had to be normal but we also included cases without information on karyotype.

Diagnostic criteria for the VACTERL association: ≥ 3 of the following: vertebral defect, AA, cardiac defect, TEF/esophageal atresia, renal defect, and limb defect.

Diagnostic criteria for MRKH syndrome: agenesis of the upper vagina and uterus.

Quality assessment of case reports

The transparency and accuracy of included case reports were assessed using the CARE checklist [28]. Each of the



14 items included in the CARE checklist was denoted either 0 = missing, 1 = fair, 2 = good or not applicable. A total score of <50% of a possible maximum was denoted poor, 50 to 74% = fair and $\geq 75\%$ = good. Two of the included cases were not described in case reports and the CARE checklist was therefore not applicable. Of the five quality assessed case reports, four were estimated as fair whereas one case report was estimated as poor.

Demographics and clinical presentation

Six of the seven case reports were published in the twenty-first century whereas one study was published in 1977. Most studies ($n = 5$) were European, one was from Asia, and one was from USA.

A single umbilical artery was not described in any of the nine cases.

In all cases ($n = 9$) reported with the VACTERL association and MRKH syndrome anorectal malformations and renal defects were present (Table 1). In all but one case, a vertebral defect was detected. In one case all features of the VACTERL association were present. Numbers of involved VACTERL components varied

from three to all six components. In seven patients a rectovestibular fistula was present.

Along with the uterovaginal agenesis, fallopian tube aplasia appeared in five of nine cases and in two cases there was also ovarian involvement. Associated anomalies were described in six out of nine cases.

Surgical approach

PSARP was the preferred surgical technique for repair of anorectal malformations; it was applied in six out of nine patients. In one patient an anterior sagittal anorectoplasty (ASARP) was preferred. The surgical techniques for uterovaginal malformations were sigmoid loop vaginoplasty ($N = 2$), modified Vecchietti, and vaginal dilations. Two patients died within the first 3 months of life and no surgical repair performed.

Conclusions

Clinical presentation and treatment strategies

All included cases with the VACTERL association and MRKH syndrome presented with AA. Totonelli *et al.* assessed the outcome in patients with AA as part of the VACTERL association (VACTERL+) [29]. In 174 patients

Table 1 Co-occurrence of vertebral defect, anal atresia, cardiac defect, tracheoesophageal fistula/esophageal atresia, renal defect, and limb defect association and Mayer-Rokitansky-Küster-Hauser syndrome in the literature and two cases from our local center

Authors	VACTERL features					Uterovaginal malformation	Other anomalies	Karyotype	Surgical and neovaginal procedures	Bowel and/or urogenital symptoms at follow-up	
	V	A	C	T	E						R
Günsar et al. [75]	X	X				X	UVag agenesis	Rib anomalies	46,XX	PSARP + sigmoid loop vaginoplasty (one-stage operation)	5-years old (none)
King et al. [76]	X	X	X	X			UVagF agenesis	Rib anomaly	46,XX	NS	Died at 3 months of age
Komura et al. [77]	X	X	X	X	X	X	UVag agenesis	Left facial nerve palsy, left hearing impairment, seizures	NS	PSARP	3 years (tracheostomy tube, mosapride for GERD, carbamazepine for seizures)
Linke et al. [78]		X	X	X	X		UVagF agenesis	Right esophageal lung, duodenal atresia	46,XX	None	Died at 4 weeks of age
Rall et al. [30]	X	X				X	UVagO agenesis	Hearing impairment, right ear tag	46,XX	PSARP, modified Vecchietti technique	3 months after modified Vecchietti operation (no vaginal symptoms)
Teo et al. [79]	X	X	X	X	X		UVagF agenesis	Bilateral vesico-ureteric reflux, overactive bladder	46,XX	PSARP	NS
Wester et al. [80]	X	X				X	UVagF agenesis	None	NS	ASARP + sigmoid loop vaginoplasty (one-stage operation)	18 months (laxatives)
Bjørsum-Meyer et al. (this report)	X	X	X	X	X		UVagFO agenesis	None	46,XX	PSARP, vaginal dilatations	22 years (vaginal dilatations)
	X	X				X	UVag agenesis	None	46,XX	PSARP	10 years (laxatives)

A anal atresia, ASARP anterior sagittal anorectoplasty, C cardiac anomaly, F fallopian tube, GERD gastroesophageal reflux disease, L limb anomaly, NS not stated, O unilateral ovary, PSARP posterior sagittal anorectoplasty, R renal and/or radial anomalies, TE tracheoesophageal fistula and/or esophageal atresia, U uterus, V vertebral anomaly, Vag vagina

with AA, 31 (18%) patients fulfilled criteria for the VACTERL association. Rectovestibular fistula was present in seven (23%) of these patients (VACTERL+) which was similar to patients without VACTERL. The poorer functional outcome in patients with VACTERL+ might be related to a higher incidence of spinal anomalies. In all cases reported with coexisting VACTERL and MRKH, AA was present and eight out of nine cases also had a vertebral defect.

In a cohort of 346 patients with MRKH syndrome, Rall et al. only found the presence of AA in three patients whereas one patient presented with the VACTERL association [30]. The high incidence of AA in patients who presented with the co-occurrence of the VACTERL association and MRKH syndrome is in accordance with the high incidence of AA in patients with VACTERL. The recommended surgical technique for repair of anorectal malformations with rectovestibular fistula is a PSARP, which is reported to have an excellent functional outcome in highly specialized centers and no associated defects [31]. According to our case report, PSARP was the preferred surgical approach for the repair of anorectal malformation in six of the nine cases presented.

In our detected cases with the co-occurrence of the VACTERL association and MRKH syndrome sparse information exist regarding treatment of the vaginal

aplasia. This can be attributed to a lack of follow-up in reported cases. Non-surgical creation of a neovagina is the preferred treatment option according to ACOG [32]. Treatment of MRKH with vaginal dilations has been reported with anatomical and functional success in 90 to 95% of patients [33, 34]. The first-line approach with vaginal dilations as well as surgical treatment is best planned when the patient is emotionally mature during late adolescence or young adulthood. Surgical treatment is an option in patients who are unsuccessfully treated with vaginal dilations. Ongoing postoperative vaginal dilations or vaginal intercourse can maintain adequate vaginal dimensioning. Several surgical procedures exist to create a neovagina, such as the Abbe-McIndoe operation, the Vecchietti procedure, and modifications of these procedures. No consensus exists on the preferred surgical technique to achieve the best functional outcome [35].

Embryopathogenesis and genetics of VACTERL association and MRKH syndrome

Cases of VACTERL association and MRKH syndrome co-occurrence are extremely rare, and to-date no unifying cause has been reported in these cases. It is therefore imperative to consider current knowledge of each entity when discussing possible etiologies.

The organ systems affected in VACTERL association develop at different stages of organogenesis. The vertebrae develop early (23 to 32 days) in contrast to the formation of anorectal structures, which occur late in organogenesis (45 to 56 days). With this in mind several potential explanations need to be considered, as suggested by Stevenson and Hunter [36]: (1) teratogenic exposure throughout the entire organogenesis, (2) an inaugural malformation disturbing the development of other organs (malformation sequence), (3) disturbance of molecular pathways or single gene mutations involved in the formation of multiple organ systems, and (4) a general disturbance of the developmental process (for example vascular insufficiency). Most cases of VACTERL association are sporadic (~90%) [37] and high discordance rates in both monozygotic and dizygotic twin pairs have been reported [38] suggesting the impact of germline genetics to be minor in the majority of cases. Reports of true familial cases of VACTERL association (≥ 3 component features; CFs) are rare; however, the prevalence of single CFs in relatives of patients with VACTERL association is ~10% suggesting a genetic etiology to some extent [37, 39]. The deletion of genes in the Sonic hedgehog pathway (for example *SHH*, *GLI*, and *HOXD13*) modeled in mice mimics many of the same malformations as found in VACTERL association, which have resulted in a profound interest in these genes [40]. However, only mutations of *HOXD13* [41] and *FOXF1* [42, 43] have been reported in humans with VACTERL association, while *SHH* and *GLI2* mutations are associated with holoprosencephaly [40]. Furthermore, mutations in *ZIC3* have been reported in several cases of VACTERL association [43–45]. Several copy number variations (CNVs) have been reported (thoroughly reviewed by Brosens *et al.* [46]), of which recurrent *de novo* CNVs have been reported at 8q24.3 (*GLI4*) and 17q23 (*TBX2/TBX4*). Finally, a few cases of VACTERL association and mitochondrial dysfunction have been reported [47]. To-date, the only well-established environmental cause of VACTERL association in humans is maternal diabetes mellitus [1]. However, rodent models exposed to adriamycin express many VACTERL-like features supporting the influence of teratogenic exposures [48]. In contrast to VACTERL association, the etiology of VACTERL-hydrocephalus is well established, it is associated with Fanconi anemia (both recessive and X-linked mutations) [49].

As in the case of VACTERL association, the etiology of MRKH syndrome/MURCS association remains elusive. Both *in utero* exposure to teratogens, epigenetics, and genetics have been considered as possible explanations. Decades ago, MRKH syndrome was thought to be caused by teratogens such as thalidomide [24]. The idea of a non-genetic etiology is supported by several reports

of discordance in monozygotic twins [50–53] and recently by a report of a phthalate-induced rodent model phenocopying MRKH syndrome [54]. However, most investigations conducted in the last decade have focused on the search of genetic causes due to increasing reports of familial clustering suggesting a low-penetrant autosomal dominant or polygenic inheritance [55]. Various promising CNVs have been reported located at 1q21.1 (*RBM8A*) [56–58], 16p11.2 (*TBX6*) [59, 60], 17q12 (*LHX1*, *HNF1B*) [56–62], as well as 22q11 [56, 57, 63, 64] associated with DiGeorge syndrome. Although intensively studied, the outcomes of candidate gene analyses have generally been sparse [65]. Positive findings from molecular genetic analyses include mutations in *LHX1* [41, 66], *TBX6* [60, 67], *RBM8A* [67], and *WNT9B* [68, 69]. Finally, mutations in *WNT4* have been reported in females with Müllerian aplasia and hyperandrogenism [26, 70, 71], although it is thought to be an entity that differs from MRKH syndrome. However, these genetic findings only apply to a small number of patients and a more general understanding of the etiology of MRKH syndrome is still needed.

Other syndromes, with known genetic etiology, occasionally sharing features with both VACTERL association and MRKH syndrome should also be considered in the assessment of these patients. These syndromes mainly include Townes–Brocks (*SALL1*) [72], CHARGE (*CHD7*) [73], Fraser (*FRAS1*) [74], and DiGeorge syndromes (del22q11) [63, 64].

As mentioned above, several possible etiologies (both non-genetic and genetic) have to be considered in cases of VACTERL and MRKH co-occurrence. Furthermore, the close interspatial relationship between the hindgut, urogenital sinus, Müllerian ducts, and developing kidneys could suggest an inaugural malformation and subsequently disturbed development of other organs (malformation sequence). With the current knowledge of genetics in VACTERL association and MRKH syndrome only being applicable for a few patients, there is currently no clinical genetic testing available for the patients with co-occurrence. However, in cases of familial occurrence it is relevant to provide genetic counseling nonetheless. The future elucidation of cause(s) is essential to ensure a correct interpretation of these multiple organ syndromes/associations and ultimately to assist a more precise genetic counseling and adequate treatment of these patients.

Conclusion

The co-occurrence of the VACTERL association and MRKH syndrome is extremely rare and we have only detected seven reported cases but added two from our local surgical center. This group of patients has unusual phenotypic characteristics. The long-term outcome after

treatment of defects is not well reported. A single unifying cause is not known and the etiology probably includes both genetic and non-genetic causes. We stress the importance of future studies to optimized treatment, follow-up, and etiology.

Abbreviations

AA: Anal atresia; ACOG: American College of Obstetricians and Gynecologists; ASARP: Anterior sagittal anorectoplasty; CF: Component feature; CNV: Copy number variation; CT: Computed tomography; DES: Diethylstilbestrol; MR: Magnetic resonance; MRKH: Mayer-Rokitansky-Küster-Hauser; MURCS: Müllerian duct aplasia, renal aplasia, and cervicothoracic somite dysplasia; OMIM: Online Mendelian Inheritance in Man; PSARP: Posterior sagittal anorectoplasty; TEF: Tracheoesophageal fistula; US: Ultrasound; VACTERL: Vertebral defect, anal atresia, cardiac defect, tracheoesophageal fistula/esophageal atresia, renal defect, and limb defect

Acknowledgements

We are thankful to colleague radiologist Jon Asmussen who provided technical help in the selection of informative radiological images.

Funding

None.

Availability of data and materials

The datasets supporting the conclusions of this article are included within the article.

Authors' contributions

All authors made a substantial contribution to concept and design. Acquisition and analyzing data were performed by TBM. MBP and NQ revised the article critically for important intellectual content. All authors gave final approval of the version to be published and agreed to be accountable for all aspects of the work.

Competing interests

The authors declare that they have no competing interests.

Consent for publication

Written informed consent was obtained from the patient/the patient's legal guardians for publication of these case reports and any accompanying images. A copy of the written consent is available for review by the Editor-in-Chief of this journal.

Ethics approval and consent to participate

A decision from The National Committee on Health Research Ethics stated that no ethical approval was needed to conduct this study. The study was approved by the Danish Data Protection Agency. Written informed consent to participate was obtained from patients.

Author details

¹Department of Surgery, Odense University Hospital, Sdr. Boulevard 29, Odense C 5000, Denmark. ²University of Southern Denmark, Campusvej 55, Odense M 5230, Denmark. ³Department of Clinical Genetics, Aalborg University Hospital, Ladegårdsgade 5, Aalborg 9000, Denmark. ⁴Department of Clinical Medicine, Aalborg University, Sdr. Skovvej 15, Aalborg 9000, Denmark.

Received: 5 September 2016 Accepted: 1 November 2016

Published online: 21 December 2016

References

- Solomon BD. VACTERL/VATER association. *Orphanet J Rare Dis*. 2011. doi:10.1186/1750-1172-6-56.
- Heller-Boersma JG, Schmidt UH, Edmonds DK. Psychological distress in women with uterovaginal agenesis (Mayer-Rokitansky-Küster-Hauser syndrome, MRKH). *Psychosomatics*. 2009;50(3):277–81.
- Botto LD, Khoury MJ, Mastroiacovo P, Castilla EE, Moore CA, Skjaerven R, et al. The spectrum of congenital anomalies of the VATER association: an international study. *Am J Med Genet*. 1997;71(1):8–15.
- Czeizel A, Ludanyi I. An aetiological study of the VACTERL-association. *Eur J Pediatr*. 1985;144(4):331–7.
- Khoury MJ, Cordero JF, Greenberg F, James LM, Erickson JD. A population study of the VACTERL association: evidence for its etiologic heterogeneity. *Pediatrics*. 1983;71(5):815–20.
- Reuter H, Ludwig M. VATER/VACTERL association: Evidence for the role of genetic factors. *Mol Syndromol*. 2013;4:16–9.
- Källén K, Mastroiacovo P, Castilla EE, Robert E, Källén B. VATER non-random association of congenital malformations: study based on data from four malformation registers. *Am J Med Genet*. 2001;101(1):26–32.
- Rittler M, Paz JE, Castilla EE. VACTERL association, epidemiologic definition and delineation. *Am J Med Genet*. 1996;63(4):529–36.
- Weaver DD, Mapstone CL, Yu PL. The VATER association. Analysis of 46 patients. *Am J Dis Child*. 1986;140(3):225–9.
- Solomon BD, Pineda-Alvarez DE, Raam MS, Bous SM, Keaton AA, Vélez JI, et al. Analysis of component findings in 79 patients diagnosed with VACTERL association. *Am J Med Genet A*. 2010;152A(9):2236–44.
- Wattanasirichaigoon D, Prasad C, Schneider G, Evans JA, Korf BR. Rib defects in patterns of multiple malformations: a retrospective review and phenotypic analysis of 47 cases. *Am J Med Genet A*. 2003;122a(1):63–9.
- Lawhon SM, MacEwen GD, Bunnell WP. Orthopaedic aspects of the VATER association. *J Bone Joint Surg Am*. 1986;68(3):424–9.
- Raam MS, Pineda-Alvarez DE, Hadley DW, Solomon BD. Long-term outcomes of adults with features of VACTERL association. *Eur J Med Genet*. 2011;54(1):34–41.
- Solomon BD, Raam MS, Pineda-Alvarez DE. Analysis of genitourinary anomalies in patients with VACTERL (Vertebral anomalies, Anal atresia, Cardiac malformations, Tracheo-Esophageal fistula, Renal anomalies, Limb abnormalities) association. *Congenit Anom*. 2011;51(2):87–91.
- Evans JA, Vitez M, Czeizel A. Patterns of acrorenal malformation associations. *Am J Med Genet*. 1992;44(4):413–9.
- Tongsong T, Wanapirak C, Piyamongol W, Sudasana J. Prenatal sonographic diagnosis of VATER association. *J Clin Ultrasound*. 1999;27(7):378–84.
- Murphy-Kaulbeck L, Dodds L, Joseph KS, Van den Hof K. Single umbilical artery risk factors and pregnancy outcomes. *Obstet Gynecol*. 2010;116:843–50.
- Londra L, Chuong FS, Kolp L. Mayer-Rokitansky-Küster-Hauser syndrome: a review. *Int J Womens Health*. 2015;7:865–70.
- Herlin M, Bjorn AM, Rasmussen M, Trolle B, Petersen MB. Prevalence and patient characteristics of Mayer-Rokitansky-Küster-Hauser syndrome: a nationwide registry-based study. *Hum Reprod*. 2016;31:2384–90.
- Aittomäki K, Eroila H, Kajanoja P. A population-based study of the incidence of Müllerian aplasia in Finland. *Fertil Steril*. 2001;76(3):624–5.
- Timmreck LS, Reindollar RH. Contemporary issues in primary amenorrhea. *Obstet Gynecol Clin N Am*. 2003;30(2):287–302.
- Oppelt P, Renner SP, Kellermann A, Brucker S, Hauser GA, Ludwig KS, et al. Clinical aspects of Mayer-Rokitansky-Küster-Hauser syndrome: Recommendations for clinical diagnosis and staging. *Hum Reprod*. 2006;21(3):792–7.
- Suzuki A, Urushitani H, Sato T, Kobayashi T, Watanabe H, Ohta Y, et al. Gene expression change in the Müllerian duct of the mouse fetus exposed to diethylstilbestrol *in utero*. *Exp Biol Med*. 2007;232(4):503–14.
- Hoffmann W, Grospietsch G, Kuhn W. Thalidomide and female genital malformations. *Lancet*. 1976;2(7989):794.
- Herlin M, Højland AT, Petersen MB. Familial occurrence of Mayer-Rokitansky-Küster-Hauser syndrome: a case report and review of the literature. *Am J Med Genet A*. 2014;164A(9):2276–86.
- Biason-Lauber A, Konrad D, Navratil F, Schoenle EJ. A *WNT4* mutation associated with Müllerian-duct regression and virilization in a 46,XX woman. *N Engl J Med*. 2004;351(8):792–8.
- American College of Obstetricians and Gynecologists. Committee opinion no. 562: Müllerian agenesis: diagnosis, management, and treatment. *Obstet Gynecol*. 2013;121(5):1134–7.
- Gagnier J, Kienle G, Altman DG, Moher D, Sox H, Riley DS, and the CARE group. The CARE guidelines: consensus-based clinical case report guideline development. *J Clin Epidemiol*. 2013;67(1):46–51.
- Totonelli G, Catania VD, Morini F, Fusaro F, Mosiello G, Iacobelli BD, et al. VACTERL association in anorectal malformations: effect on the outcome. *Pediatr Surg Int*. 2015;31:805–8.
- Rall K, Eisenbeis S, Henninger V, Henes M, Wallwiener D, Bonin M, et al. Typical and Atypical Associated Findings in a Group of 346 Patients with Mayer-Rokitansky-Küster-Hauser Syndrome. *J Pediatr Adolesc Gynecol*. 2015;28(5):362–8.

31. Pena A, Bischoff A. Rectovestibular fistula. In: Pena A, Bischoff A, editors. *Surgical treatment of colorectal problems in children*. Switzerland: Springer; 2015. p. 205–24.
32. Committee on Adolescent Health Care. Müllerian agenesis: diagnosis, management and treatment. Committee Opinion No. 562. American College of Obstetricians and Gynecologists. *Obstet Gynecol*. 2013;121:1134–7.
33. Roberts CP, Haber MJ, Rock JA. Vaginal creation for müllerian agenesis. *Am J Obstet Gynecol*. 2001;185(6):1349–52.
34. Edmonds DK, Rose GL, Lipton MG, Raek J. Mayer-Rokitansky-Küster-Hauser syndrome: a review of 245 consecutive cases managed by a multidisciplinary approach with vaginal dilators. *Fertil Steril*. 2012;97(3):686–90.
35. Laufer MR. Congenital absence of the vagina: in search of the perfect solution. When, and by what technique, should a vagina be created? *Curr Opin Obstet Gynecol*. 2002;14(5):441–4.
36. Stevenson RE, Hunter AG. Considering the Embryopathogenesis of VACTERL Association. *Mol Syndromol*. 2013;4(1–2):7–15.
37. Solomon BD, Pineda-Alvarez DE, Raam MS, Cummings DA. Evidence for inheritance in patients with VACTERL association. *Hum Genet*. 2010;127(6):731–3.
38. Bartels E, Jenetzky E, Solomon BD, Ludwig M, Schmiedeke E, Grasshoff-Derr S, et al. Inheritance of the VATER/VACTERL association. *Pediatr Surg Int*. 2012;28(7):681–5.
39. Hilger A, Schramm C, Draaken M, Mughal SS, Dworschak G, Bartels E, et al. Familial occurrence of the VATER/VACTERL association. *Pediatr Surg Int*. 2012;28(7):725–9.
40. Ngan ES, Kim KH, Hui CC. Sonic Hedgehog Signaling and VACTERL Association. *Mol Syndromol*. 2013;4(1–2):32–45.
41. Garcia-Barcelo MM, Wong KK, Lui VC, Yuan ZW, So MT, Ngan ES, et al. Identification of a *HOXD13* mutation in a VACTERL patient. *Am J Med Genet A*. 2008;146a(24):3181–5.
42. Stankiewicz P, Sen P, Bhatt SS, Storer M, Xia Z, Bejjani BA, et al. Genomic and genic deletions of the FOX gene cluster on 16q24.1 and inactivating mutations of *FOXF1* cause alveolar capillary dysplasia and other malformations. *Am J Hum Genet*. 2009;84(6):780–91.
43. Hilger AC, Halbritter J, Pennimpede T, van der Ven A, Sarma G, Braun DA, et al. Targeted Resequencing of 29 Candidate Genes and Mouse Expression Studies Implicate *ZIC3* and *FOXF1* in Human VATER/VACTERL Association. *Hum Mutat*. 2015;36(12):1150–4.
44. Ware SM, Peng J, Zhu L, Fernbach S, Colicos S, Casey B, et al. Identification and functional analysis of *ZIC3* mutations in heterotaxy and related congenital heart defects. *Am J Hum Genet*. 2004;74(1):93–105.
45. Wessels MW, Kuchinka B, Heydanus R, Smit BJ, Dooijes D, de Krijger RR, et al. Polyalanine expansion in the *ZIC3* gene leading to X-linked heterotaxy with VACTERL association: a new polyalanine disorder? *J Med Genet*. 2010;47(5):351–5.
46. Brosens E, Eussen H, van Bever Y, van der Helm RM, Ijsselstijn H, Zaveri HP, et al. VACTERL Association Etiology: The Impact of *de novo* and Rare Copy Number Variations. *Mol Syndromol*. 2013;4(1–2):20–6.
47. Siebel S, Solomon BD. Mitochondrial Factors and VACTERL Association-Related Congenital Malformations. *Mol Syndromol*. 2013;4(1–2):63–73.
48. Beasley SW, Diez Pardo J, Qi BQ, Tovar JA, Xia HM. The contribution of the adriamycin-induced rat model of the VATER association to our understanding of congenital abnormalities and their embryogenesis. *Pediatr Surg Int*. 2000;16(7):465–72.
49. Alter BP, Rosenberg PS. VACTERL-H Association and Fanconi Anemia. *Mol Syndromol*. 2013;4(1–2):87–93.
50. Lischke JH, Curtis CH, Lamb EJ. Discordance of vaginal agenesis in monozygotic twins. *Obstet Gynecol*. 1973;41(6):920–4.
51. Regenstein AC, Berkeley AS. Discordance of müllerian agenesis in monozygotic twins. A case report. *J Reprod Med*. 1991;36(5):396–7.
52. Duru UA, Laufer MR. Discordance in Mayer-von Rokitansky-Kuster-Hauser Syndrome noted in monozygotic twins. *J Pediatr Adolesc Gynecol*. 2009;22(4):73–5.
53. Milsom SR, Ogilvie CM, Jefferies C, Cree L. Discordant Mayer-Rokitansky-Kuster-Hauser (MRKH) syndrome in identical twins – a case report and implications for reproduction in MRKH women. *Gynecol Endocrinol*. 2015;31(9):684–7.
54. Hannas BR, Howdeshell KL, Furr J, Gray Jr LE. *In utero* phthalate effects in the female rat: a model for MRKH syndrome. *Toxicol Lett*. 2013;223(3):315–21.
55. Herlin M, Hojland AT, Petersen MB. Familial occurrence of Mayer-Rokitansky-Kuster-Hauser syndrome: a case report and review of the literature. *Am J Medical Genet A*. 2014;164a(9):2276–86.
56. Cheroki C, Krepischi-Santos AC, Szuhai K, Brenner V, Kim CA, Otto PA, et al. Genomic imbalances associated with müllerian aplasia. *J Med Genet*. 2008;45(4):228–32.
57. Ledig S, Schippert C, Strick R, Beckmann MW, Oppelt PG, Wieacker P. Recurrent aberrations identified by array-CGH in patients with Mayer-Rokitansky-Kuster-Hauser syndrome. *Fertil Steril*. 2011;95(5):1589–94.
58. McGowan R, Tydeman G, Shapiro D, Craig T, Morrison N, Logan S, et al. DNA copy number variations are important in the complex genetic architecture of müllerian disorders. *Fertil Steril*. 2015;103(4):1021–30.
59. Nik-Zainal S, Strick R, Storer M, Huang N, Rad R, Willatt L, et al. High incidence of recurrent copy number variants in patients with isolated and syndromic Müllerian aplasia. *J Med Genet*. 2011;48(3):197–204.
60. Sandbacka M, Laivuori H, Freitas E, Halttunen M, Jokimaa V, Morin-Papunen L, et al. *TBX6*, *LHX1* and copy number variations in the complex genetics of Müllerian aplasia. *Orphanet J Rare Dis*. 2013;8:125.
61. Lindner TH, Njolstad PR, Horikawa Y, Bostad L, Bell GI, Sovik O. A novel syndrome of diabetes mellitus, renal dysfunction and genital malformation associated with a partial deletion of the pseudo-POU domain of hepatocyte nuclear factor-1beta. *Hum Mol Genet*. 1999;8(11):2001–8.
62. Bernardini L, Gimelli S, Gervasini C, Carella M, Baban A, Frontino G, et al. Recurrent microdeletion at 17q12 as a cause of Mayer-Rokitansky-Kuster-Hauser (MRKH) syndrome: two case reports. *Orphanet J Rare Dis*. 2009;4:25.
63. Sundaram UT, McDonald-McGinn DM, Huff D, Emanuel BS, Zackai EH, Driscoll DA, et al. Primary amenorrhea and absent uterus in the 22q11.2 deletion syndrome. *Am J Med Genet A*. 2007;143a(17):2016–8.
64. Morcel K, Watrin T, Pasquier L, Rochard L, Le Caignec C, Dubourg C, et al. Utero-vaginal aplasia (Mayer-Rokitansky-Kuster-Hauser syndrome) associated with deletions in known DiGeorge or DiGeorge-like loci. *Orphanet J Rare Dis*. 2011;6:9.
65. Morcel K, Camborieux L, Guerrier D. Mayer-Rokitansky-Kuster-Hauser (MRKH) syndrome. *Orphanet J Rare Dis*. 2007;2:13.
66. Ledig S, Brucker S, Barresi G, Schomburg J, Rall K, Wieacker P. Frame shift mutation of *LHX1* is associated with Mayer-Rokitansky-Kuster-Hauser (MRKH) syndrome. *Hum Reprod*. 2012;27(9):2872–5.
67. Tewes AC, Rall KK, Romer T, Huckle J, Kapczuk K, Brucker S, et al. Variations in *RBM8A* and *TBX6* are associated with disorders of the müllerian ducts. *Fertil Steril*. 2015;103(5):1313–8.
68. Waschk DE, Tewes AC, Romer T, Huckle J, Kapczuk K, Schippert C, et al. Mutations in *WNT9B* are associated with Mayer-Rokitansky-Kuster-Hauser syndrome. *Clin Genet*. 2016;89(5):590–6. doi:10.1111/cge.12701.
69. Wang M, Li Y, Ma W, Li H, He F, Pu D, et al. Analysis of *WNT9B* mutations in Chinese women with Mayer-Rokitansky-Kuster-Hauser syndrome. *Reprod Biomed Online*. 2014;28(1):80–5.
70. Philibert P, Bignon-Laubert A, Rouzier R, Pienkowski C, Paris F, Konrad D, et al. Identification and functional analysis of a new *WNT4* gene mutation among 28 adolescent girls with primary amenorrhea and müllerian duct abnormalities: a French collaborative study. *J Clin Endocrinol Metab*. 2008;93(3):895–900.
71. Philibert P, Bignon-Laubert A, Gueorguieva I, Stuckens C, Pienkowski C, Lebon-Labich B, et al. Molecular analysis of *WNT4* gene in four adolescent girls with müllerian duct abnormality and hyperandrogenism (atypical Mayer-Rokitansky-Kuster-Hauser syndrome). *Fertil Steril*. 2011;95(8):2683–6.
72. Botzenhart EM, Green A, Ilyina H, König R, Lowry RB, Lo IF, et al. *SALL1* mutation analysis in Townes-Brocks syndrome: twelve novel mutations and expansion of the phenotype. *Hum Mutat*. 2005;26(3):282.
73. Ragan DC, Casale AJ, Rink RC, Cain MP, Weaver DD. Genitourinary anomalies in the CHARGE association. *J Urol*. 1999;161(2):622–5.
74. Ramsing M, Rehder H, Holzgreve W, Meinecke P, Lenz W. Fraser syndrome (cryptophthalmos with syndactyly) in the fetus and newborn. *Clin Genet*. 1990;37(2):84–96.
75. Günşar C, Genç A, Sencan A, Dağlar Z, Alparslan O, Mir E. MURCS association and rectovestibular fistula: case report of a patient treated with one-stage posterior sagittal anorectoplasty and sigmoid loop vaginoplasty. *J Pediatr Surg*. 2003;38(2):262–4.
76. King SL, Ladda RL, Shochat SJ. Monozygotic twins concordant for tracheo-esophageal fistula and discordant for the VATER association. *Acta Paediatr Scand*. 1977;66(6):783–5.
77. Komura M, Kanamori Y, Sugiyama M, Tomonaga T, Suzuki K, Hashizume K, et al. A female infant who had both complete VACTERL association and MURCS association: report of a case. *Surg Today*. 2007;37(10):878–80.

78. Linke F, Kraemer W, Ansorge M, Brzezinska, Berger S. Right esophageal lung in a preterm child with VACTERL association and Mayer-Rokitansky-Kuster-Hauser syndrome. *Pediatr Surg Int.* 2005;21(4):285–8.
79. Teo XL, Narasimhan KL, Chua JH. Mullerian agenesis in the presence of anorectal malformations in female newborns: a diagnostic challenge. *Singapore Med J.* 2015;56(5):82–4.
80. Wester T, Tovar JA, Rintala RJ. Vaginal agenesis or distal vaginal atresia associated with anorectal malformations. *J Pediatr Surg.* 2012;47(3):571–6.

Submit your next manuscript to BioMed Central and we will help you at every step:

- We accept pre-submission inquiries
- Our selector tool helps you to find the most relevant journal
- We provide round the clock customer support
- Convenient online submission
- Thorough peer review
- Inclusion in PubMed and all major indexing services
- Maximum visibility for your research

Submit your manuscript at
www.biomedcentral.com/submit

