



The interface between periacetabular osteotomy, hip arthroscopy and total hip arthroplasty in the young adult hip

Jakobsen, Stig Storgaard; Overgaard, Soren; Soballe, Kjeld; Ovesen, Ole; Mygind-Klavsen, Bjarne; Dippmann, Christian Andreas; Jensen, Michael Ulrich; Stuerup, Jens; Retpen, Jens

Published in:
EFORT OPEN REVIEWS

DOI (link to publication from Publisher):
[10.1302/2058-5241.3.170042](https://doi.org/10.1302/2058-5241.3.170042)

Creative Commons License
CC BY-NC 4.0

Publication date:
2018

Document Version
Publisher's PDF, also known as Version of record

[Link to publication from Aalborg University](#)

Citation for published version (APA):
Jakobsen, S. S., Overgaard, S., Soballe, K., Ovesen, O., Mygind-Klavsen, B., Dippmann, C. A., Jensen, M. U., Stuerup, J., & Retpen, J. (2018). The interface between periacetabular osteotomy, hip arthroscopy and total hip arthroplasty in the young adult hip. *EFORT OPEN REVIEWS*, 3(7), 408-417. <https://doi.org/10.1302/2058-5241.3.170042>

General rights

Copyright and moral rights for the publications made accessible in the public portal are retained by the authors and/or other copyright owners and it is a condition of accessing publications that users recognise and abide by the legal requirements associated with these rights.

- Users may download and print one copy of any publication from the public portal for the purpose of private study or research.
- You may not further distribute the material or use it for any profit-making activity or commercial gain
- You may freely distribute the URL identifying the publication in the public portal -

Take down policy

If you believe that this document breaches copyright please contact us at vbn@aub.aau.dk providing details, and we will remove access to the work immediately and investigate your claim.



The interface between periacetabular osteotomy, hip arthroscopy and total hip arthroplasty in the young adult hip

Stig Storgaard Jakobsen¹
Søren Overgaard²
Kjeld Søballe¹
Ole Ovesen²
Bjarne Mygind-Klavsen¹
Christian Andreas Dippmann³
Michael Ulrich Jensen⁴
Jens Stürup⁵
Jens Retpen⁶

- Hip pain is highly prevalent in both the younger and the elderly population. In older patients, pain arising from osteoarthritis (OA) is most frequent, whereas in younger patients, non-degenerative diseases are more often the cause of pain. The pain may be caused by hip dysplasia and femoroacetabular impingement (FAI).
- Abnormal mechanics of the hip are hypothesized by some authors to cause up to 80% of OA in the hip. Therefore, correction of these abnormalities is of obvious importance when treating young patients with hip pain.
- Hip dysplasia can be diagnosed by measuring a CE angle $< 25^\circ$ on a plain standing radiograph of the pelvis.
- Dysplastic or retroverted acetabulum with significant symptoms should receive a periacetabular osteotomy (PAO).
- FAI with significant symptoms should be treated by adequate resection and, if necessary, labrum surgery.
- If risk factors for poor outcome of joint-preserving surgery are present (age > 45 to 50 years, presence of OA, joint space < 3 mm or reduced range of motion), the patient should be offered a total hip arthroplasty (THA) instead of PAO.
- THA can be performed following PAO with outcomes similar to a primary THA.
- Hip arthroscopy is indicated in FAI (cam and pincer) and/or for labral tears.

Keywords: PAO; hip arthroscopy; developmental dysplasia of the hip; femoroacetabular impingement; secondary osteoarthritis of the hip

Cite this article: *EFORT Open Rev* 2018;3:408-417.
DOI: 10.1302/2058-5241.3.170042

Background

The interest in treating hip pathologies, such as developmental dysplasia of the hip (DDH), femoroacetabular impingement (FAI) and labral tears in patients without radiographic signs of osteoarthritis (OA), has rapidly increased. Wiberg et al and Ganz et al showed a link between DDH and FAI and the development of OA.^{1,2} Ganz et al further hypothesized that 70% to 90% of all hip OA is caused by abnormal mechanics. When present, these abnormalities require surgical treatment for young patients when trying to relieve pain and restore function, and when attempting to reduce risk of secondary OA in the hip.

DDH is believed to be an osseous abnormality resulting in a pathological painful labral complex and musculotendinous abnormality, eventually leading to secondary hip arthritis.^{2,3} Acetabular retroversion is described as a posteriorly oriented acetabular opening with reference to the sagittal plane,⁴ and can be seen as an isolated entity but may also be seen in combination with DDH, labral lesions and cam deformity. Symptoms are caused by impingement between the prominent anterolateral edge of the acetabulum and the anterior surface of the femoral head-neck junction in flexion and internal rotation.

This group of young patients with debilitating hip pain has led to the development and refinement of both open and arthroscopic procedures to address intra-articular hip

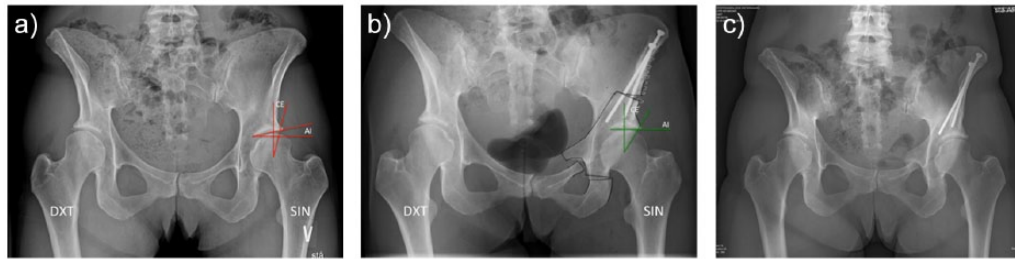


Fig. 1 a) Pre-operative and post-operative radiographs of a female patient. The pre-operative CE-angle was 17° on the left side and 12° on the right side. The pre-operative acetabular index angle was 19° on the left side and 11° on the right side. b) Post-operatively, the CE-angle is 30° and the AI-angle is 0° . The goal of correction is an AI-angle close to 0° . An AI-angle $< 0^\circ$ will cause impingement. c) One year post-operatively the osteotomies are healed.

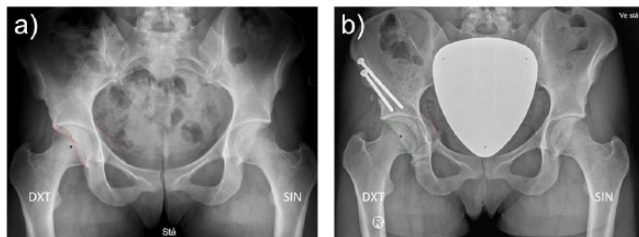


Fig. 2 a) Standing anterior-posterior pelvic radiograph with bilateral cross-over sign, posterior wall sign and prominence of the ischial spine. b) One year post-operative standing anterior-posterior radiograph. The osteotomies are healed and the cross-over sign and posterior wall sign have disappeared.

pathologies. In particular, hip arthroscopy has become increasingly popular in the last decade. But while some advocate hip arthroscopy as the standard treatment for intra-articular pathologies in non-arthritic hips,⁵ others point out that this trend is not supported by evidence.⁶

DDH is normally treated with pelvic osteotomies that can be categorized based on the surgical technique: re-orientation; reshaping; and salvage/augmentation. When the triradiate cartilage has healed, periacetabular osteotomies (PAO) with re-orientating of the periacetabular fragment and preservation of the posterior column (Ninomiya and Tagawa, and Ganz et al) are now used in Europe, North America and Asia.^{7,8}

The durability of total hip arthroplasty (THA) has increased significantly and has been followed by an extension of the indications. However, joint-preserving surgery presents advantages such as a low risk of dislocation and infection, and THA can be employed as a salvage procedure. This narrative review focuses on the interface between joint-preserving surgery and THA, with practical advice and an algorithm for treatment.

Diagnosis of the painful hip

A history of pain and associated symptoms and triggering injuries, movements and activities are important to diagnose hip disease. The clinical examination including the

flexion–adduction–internal rotation test (FADDIR) and flexion–abduction–external rotation test (FABER) are sensible but not very specific in differentiating between pathologies.^{9,10} Although intra-articular injections with glucocorticoids have not shown long-lasting effect in patients with clinical signs of FAI, diagnostic intra-articular injection with local anaesthetic can be a valuable tool in the clinical decision-making process.^{11,12} Intra-articular injections in dysplastic hips have, however, only a very limited therapeutic value.¹³

Diagnosing symptomatic patients can often be done by a clinical history and a few radiographs of the hip and pelvis (Figs 1 and 2), but an abundance of hip projections exists together with many other modalities (x-ray CT, MRI, ultrasonography (US)).

In young adults with sharp pain in the groin and clinical signs of hip joint pathology, a standing radiograph of the pelvis together with a false profile is mandatory. In false profile x-ray the patient is standing and the x-ray is centred on the affected hip, with the pelvis rotated 25° posterior and the foot on the affected hip parallel with the x-rays.

A diagnosis can be made by measuring the Wiberg CE angle, Tönnis angle, posterior wall sign (PWS), cross-over sign (COS) and prominence of the ischial spine (PRISS) on a plain standing radiograph of the pelvis (Figs 1 and 2).¹⁴ These signs, unfortunately, are not very robust since they are dependent on the pelvic tilt and rotation.^{15,16} All the signs may be present on a supine pelvis radiograph, but can disappear on the standing radiograph. MRI and CT scans are normally unnecessary. A CT scan, although performed supine, may be helpful in quantitating the retroversion. Consequently, a major challenge remains to find the right patient for the right treatment.^{17,18}

Developmental dysplasia of the hip: periacetabular osteotomy (PAO)

Clinical presentation

The typical patient is aged 20 to 45 years and 80% of patients are female.¹⁹ Symptoms arise when the acetabular

Table 1. Indication for reverse PAO surgery in acetabular retroversion with FAI

Indications	Relative and absolute contraindications
Persistent pain	Non-symptomatic
Age: 15 to 45 years	Reduced ROM
Positive impingement test	Presence of OA (Tönnis grade > 1)
	Joint space width < 3 mm
Good ROM	Absence of PWS*
Presence of COS, PWS (PRISS)	Age < 15 years†

*In these cases the posterior wall is not deficient and a PAO could lead to posterior impingement and therefore we recommend an arthroscopic rim trimming.

†In these cases, we wait and monitor the patient.
ROM, range of motion; OA, osteoarthritis.

rim with a pathological labral complex is overloaded due to abnormal biomechanics in the hip joint. Symptoms are often a sharp activity-related pain located deep in the groin and can be provoked by hip flexion and internal rotation. The pain is also typical in the C-sign region and will often result in referred pain to the anterior part of the femur. The C-sign is when the patient cups their hands in a C-shape right above the greater trochanter to describe a deep interior hip pain.

Indications for PAO

Indication for a PAO is persistent pain in a dysplastic congruent non-arthritic hip (Table 1).

Surgical technique

During surgery, the acetabulum is re-oriented with adduction of the fragment in order to improve the coverage of the lateral and anterior part of the femoral head; the aim is to achieve congruity, to stabilize the hip joint, to medialize the hip joint centre and to reduce contact pressures (Fig. 1).^{8,20-22} This will relieve pain, improve function and is likely to prevent further overload of the hip joint, thereby delaying or preventing the development of OA.²³ The PAO has several technical advantages compared with other existing techniques.²⁴ The posterior column remains intact, leaving the pelvis stable, allowing partial weight-bearing immediately post-operatively, requiring minimal internal fixation and the dimensions of the true pelvis are maintained.²⁴

Complications

Complications can be divided into *moderate* and *severe* neurovascular or technical complications (i.e. an injury to great vessels or nerves, arterial thrombosis, unintended extension of the osteotomy into the joint or through the posterior column, or deep infection) and *minor* complications (i.e. lateral femoral cutaneous nerve dysaesthesia, delayed union and heterotopic ossification). Moderate and severe neurovascular complications are most frequently reported to occur in approximately

0% to 5%.^{8,25-33} The learning curve related to the occurrence of complications affects the outcome in some studies.^{8,29,34} Stress fracture of the ischium has recently been reported to occur in 18%³⁵ and obesity has recently been shown to increase the risk of a serious complication by 11 times.³⁶

Results

Studies report high survival rates of the hip joint following PAO. Assessed by Kaplan-Meier analyses with conversion to THA as the endpoint, the five-year and ten-year survival rates were 90% and 84%, respectively, and a long-term study revealed a survival rate of 60% after 20 years.³⁷⁻³⁹ Another more recent study from Lerch et al proved a good clinical result without development of secondary arthritis 30 years post-operatively for one-third of the patients.⁴⁰ Studies have identified risk factors predicting failure after PAO.^{21,32,37-39,41} Risk factors increasing the risk of secondary OA followed by a THA are age (> 45 years old), pre-operative Tönnis grade > 1, incongruent hip joint and joint space width < 3 mm.¹⁹ A recent study has indicated that the risk of OA is significantly reduced following PAO.²³

Conclusions

PAO is an effective treatment for symptomatic hip dysplasia. The risk of complication is relatively low if experienced surgeons perform the operation. It is important to be aware of the predictors for failure after PAO. By identifying these factors, candidates who will benefit from PAO can be selected. However, patients at risk of early failure after PAO (age > 45 to 50 years, limited range of motion (ROM; rotation < 15°), non-congruent joint, signs of OA (Tönnis grade > 1)) can instead be offered a primary THA – even if arthritis is not yet present. Hip arthroscopy should not be performed in patients with dysplasia (CE angle < 25°) since the underlying osseous deformity present in dysplasia should be corrected first by performing a three-dimensional (3D) correction of the deformity (PAO).

Acetabular retroversion with FAI treated with reverse PAO

Clinical presentation

The typical patient is aged 15 to 35 years. In the relatively sparse literature, there is no clear association with gender. Female proportion varies from 35%¹⁵ to 100%.^{4,42} Symptoms are typical activity-related groin pain, but may also be related to the sitting position. At clinical examination, the impingement test is positive and internal rotation may be reduced. In pronounced cases, or cases combined with CAM deformity, forced abduction can be seen in terminal flexion. Diagnosis is made from a standing radiograph of the pelvis based on the presence of COS, PWS and PRISS (Fig. 2).⁴³

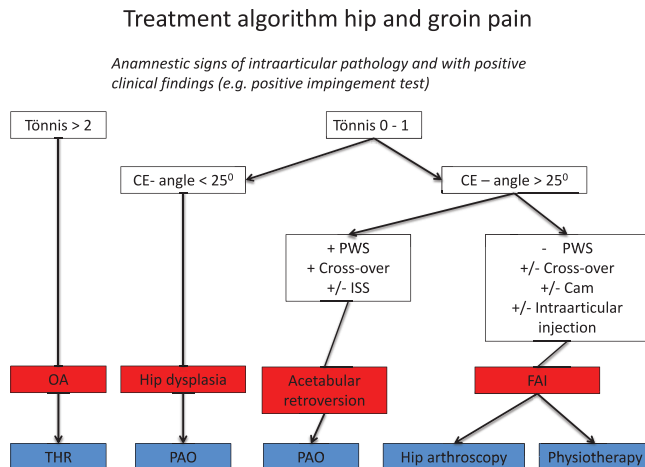


Fig. 3 Treatment algorithm for hip and groin pain.

Indications for reverse PAO

The indication for a reverse PAO is persistent pain in a congruent non-arthritic hip (Table I).

Surgical technique

The re-orientation is a combined internal rotation and flexion extension of the periacetabular fragment by removing a wedge of iliac bone. The judgement of a sufficient correction is based on the disappearance of COS and PWS on the image intensifier. In cases combined with DDH, an adduction of the fragment also has to be carried out.

Results

So far, only 71 hips with acetabular retroversion treated with a PAO have been reported in the literature.^{4,15,44} In the study by Reynolds et al, no follow-up data are presented.⁴ Siebenrock et al reported a significant improvement in clinical outcome and ROM in a study with long-term follow-up on 29 hips.¹⁵ The cumulative ten-year survivorship, with conversion to a THA as the primary endpoint, was 100%. Four patients (14%), however, had other major re-operations due to persistent impingement. In the study by Parry et al, with an average follow-up of five years, four patients had a major re-operation, including one THA. This study also reported a significant clinical improvement.⁴⁴ Schmigelow et al found a significant improvement in clinical outcome in terms of Harris Hip Score, EQ5D and pain on VRS (Visual Rating Scale) at one-to ten-year follow-up. Two major re-operations (one THA, one re-PAO) were performed.⁴² A retrospective study proved that anteverting PAO was superior to hip surgical hip dislocation with rim trimming after ten-year follow-up (79.1% vs 23.0%, $p = 0.0002$).⁴⁵

Conclusions

In conclusion, results after a 3D correction of the deformity by a reverse PAO seem promising. The exact amount of correction is still a matter of debate. Further studies aimed at improving patient selection and intra-operative methods to obtain optimal correction and identify risk factors are still warranted.

Cheilectomy, rim trimming, labral reinsertion/FAI – hip arthroscopy

Clinical presentation

The typical patient has activity-related pain located deep in the groin, which can often be provoked by hip flexion, internal rotation and adduction. The pain is also typical in the C-sign region and will often result in referred pain to the anterior part of the thigh.

Indication and contraindication

The best way of identifying suitable patients for hip arthroscopy is to exclude all patients who do not benefit from hip arthroscopy (Fig. 3).

A lateral joint space width ≤ 3 mm and Tönnis grade > 1 indicate OA, which has been shown to be a predictor of suboptimal outcome following hip arthroscopy.⁴⁶ Although recent literature has shown pain relief and improved function, the rate of re-operation and conversion to total hip replacement (THR) is rather high.⁴⁷ Therefore, hip arthroscopy is not recommended in patients with radiographic signs of OA (Tönnis > 1 and joint space width < 3 mm).

Although the indications for hip arthroscopy in recent years have extended to extra-articular pathologies such as, for example, subspinal impingement, psoas tendinopathy or ischio-femoral impingement, the primary indication remains the treatment of FAI syndrome including intra-articular pathologies such as labral injury, chondral lesions, synovitis, foreign bodies and a clinically relevant cam morphology, here defined by an alpha-angle $> 60^\circ$.⁴⁸ As labral injuries and cam morphologies have a relatively high incidence in the asymptomatic population, addressing hip and groin pain by hip arthroscopy should not be based solely on radiographic imaging.⁴⁹ The association of patient history, physical examination and radiographic imaging is crucial for the diagnosis of FAI syndrome as stated recently by the Warwick Agreement.⁵⁰

The advantages of arthroscopic surgery might seem obvious, such as minimally invasive, potentially faster rehabilitation and potentially reduced soft-tissue injury when compared with open surgery. The limitations of arthroscopic surgery should be considered in more challenging pathomorphologies such as slipped capital femoral epiphysis, Legg-Calvé-Perthes disease and acetabular

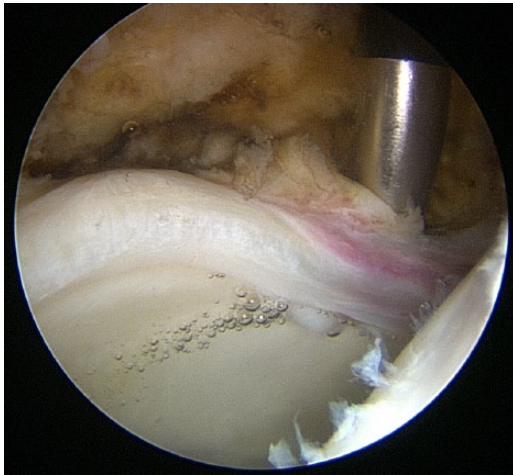


Fig. 4 A typical cam-type labral lesion located supero-anterior in the hip joint. The labrum shows signs of synovitis and is partially detached from the acetabular socket. Often adjacent delamination of the cartilage, described as *wave sign*, can be seen, too.

dysplasia (CE-angle $< 25^\circ$) and/or high Tönnis angle (AI-angle $> 10^\circ$).⁵¹ Some FAI-related pathomorphologies, such as significant cam morphologies with posterior or posterolateral extension, coxa profunda and protrusio acetabuli, should be considered for treatment with open surgical approach since these pathologies are too technically demanding to treat sufficiently with arthroscopy. In terms of outcome following surgical treatment of FAI, both arthroscopy and open surgical hip dislocation have demonstrated excellent and comparable results at medium-term follow-up.⁵²

Surgical procedure

As it is still unknown which pathology in particular generates the intra-articular pain, usually all intra-articular pathologies are addressed during one single procedure. Generally, hip arthroscopy includes treatment of the labral pathology, but existing cartilage injuries will also require the reshaping of the head-neck junction when necessary. These procedures are most commonly performed under general anaesthesia with the patient in the supine position. Under traction, the hip joint is distracted and the central compartment is entered. The cartilage and the acetabular labrum are examined and treated depending on the degree of injury (Fig. 4).

Cam-related injuries are usually located in the anterior-superior part of the acetabulum, whereas pincer-related injuries can be seen circumferentially in the chondrolabral junction. The aim is to re-establish a stable situation without loose cartilage or an unstable acetabular labrum prone to further damage by compression or impingement. It is recommended to suture the labrum to the

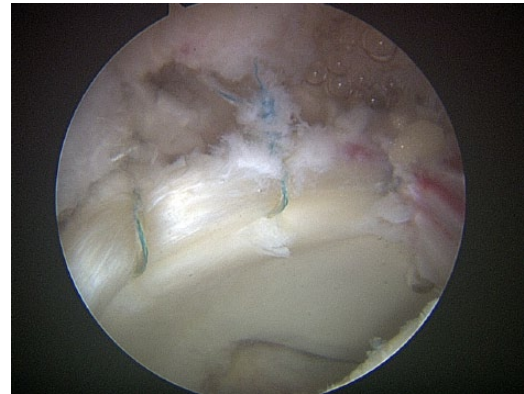

Fig. 5 After addressing all intra-articular pathologies, such as potential subspinal impingement, ligamentum teres pathologies, cartilage lesions, etc., a moderate acetabular rim trimming is performed, followed by a re-attachment of the acetabular labrum lesion with suture anchors. By stabilizing the chondro-labral junction joint congruence the labral suction seal is re-established.

acetabular rim as this has demonstrated superior outcome over debridement or resection alone.⁴⁷ In order to re-insert the labrum, suture anchors can be used with or without prior acetabular rim-trimming (Fig. 5).

When the chondrolabral junction is addressed, traction is released and the peripheral compartment examined dynamically in different degrees of hip flexion and rotation. Using an image intensifier, the cam can then be removed arthroscopically (Fig. 6). In special cases, such as in patients with borderline dysplasia (CE angle of 20° to 25° and AI-angle $< 7^\circ$) or other type of hip instability (e.g. Ehlers-Danlos syndrome, previous PAO surgery), the overall opinion is to perform a capsular plication procedure to prevent further instability after hip arthroscopy, which was associated with a better clinical outcome in a mildly dysplastic cohort.⁵³

Complications

Apart from general surgical complications such as infection and deep vein thrombosis, complications related to hip arthroscopy are mainly recognized as iatrogenic (e.g. cartilage and labral injuries), traction-related (e.g. extra-articular nerve affection, neuropraxia) and nerve injury-related to portal placement.^{54,55} A rare but potentially dangerous complication with abdominal fluid extravasation can be observed in 0.04% of patients.⁵⁶ Within the first weeks after surgery, up to 46% of all patients report temporary nerve affection described as numbness or reduced sensibility either directly around the arthroscopic portals or indirectly around the area to which traction has been applied. The overall complication rate is reported to be in the range of 4% to 7.5%, while major complications, such as avascular necrosis of the femoral head, femoral neck fracture or hip

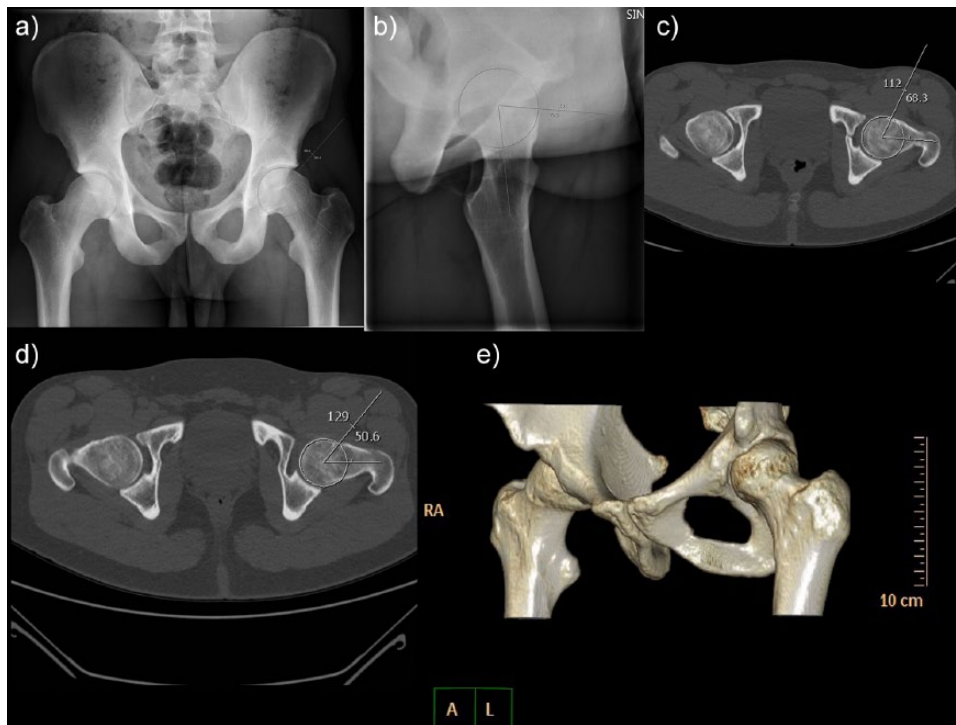


Fig. 6 Cam-related FAI in a 22-year-old male patient in his left hip. a) Pre-operative anteroposterior pelvis radiograph indicates an alpha-angle of 89° . b) Pre-operative lateral view with alpha-angle 79° . c) Pre-operative lateral view (CT) with alpha-angle 68° . d) Post-operative lateral view (CT) with alpha-angle 50° and e) post-operative 3D CT scan illustrating the performed resection at the head-neck junction.

instability with anterior dislocation, are rare conditions with a rate of approximately 0.45% to 0.58%.^{47,54,55,57}

Results

Recent studies show symptomatic improvement with better hip outcome scores, high patient satisfaction and a low complication rate. Clinically relevant improvement can usually be seen within three months after surgery.^{49,58,59} Data from the Danish Hip Arthroscopy Registry (DHAR) have demonstrated significant improvements in all subscales of The Copenhagen Hip and Groin Outcome Score (HAGOS), EQ-5D, HSAS (Hip Sports Activity Scale) and NRS (Numeric Rating Scale) at both one- and two-year follow-up in a FAI cohort consisting of 2000 hip arthroscopic procedures.⁶⁰ Nonetheless, it has to be mentioned that the existing studies are mainly level IV cohort studies without control groups, which is why further studies are needed. The re-operation rate has been described to be in the range of 4% to 6.3%.⁵⁴ The most common reason is the conversion to THR in around 2% to 3%, which is closely related to the pre-operative cartilage status.^{46,61}

Conclusions

Radiographic signs of labral injuries, cam or pincer morphologies are frequent findings in the asymptomatic

population and should therefore not be over-interpreted. The decision-making process must be based on correct radiographic imaging and clinical examination. Intra-articular injection with local anaesthesia can be a helpful tool in identifying patients suitable for hip arthroscopy. In case of proper patient selection, significant improvement after hip arthroscopy for FAI can be expected within three months after surgery.

Discussion

Selection of patients is essential for surgical success. Meeting young hip patients in clinical practice, the surgeon will face the dilemma of choosing between hip arthroplasty surgery or hip joint-preserving surgery. In order to offer the best treatment, the hip surgeon needs to make evidence-based decisions.

Risk factors: osteoarthritis, age, bone quality, obesity

At the present time, no randomized controlled trials comparing PAO with THA have been published, and only a few papers compare these treatment options. With a short-term follow-up of six years, Gray et al⁶² reported no differences in patient-reported outcomes between PAO and THA with similar demographic details (age < 40 years). Complication

Table 2. Indication for PAO surgery for developmental dysplasia of the hip defined by a CE-angle < 25°

Indications	Relative and absolute contraindications
Persistent pain	Non-symptomatic
Good joint congruity and ROM	Reduced ROM (rotation < 15°, flexion < 100°)
None or mild OA (Tönnis 0, 1)	Presence of OA (Tönnis grade > 1) Joint space width < 3 mm
Age: 13 to 45 years	Age > 45 years

ROM, range of motion; OA, osteoarthritis

rates were low and similar in each cohort ($p = 0.68$). Investigating clinical outcome and quality of life in patients aged > 40 years with a mean follow-up of four years, Garbus et al⁶³ demonstrated better quality of life in the THA group compared with the PAO group. Millis et al⁶⁴ retrospectively evaluated PAO for acetabular dysplasia in patients aged > 40 years. The results suggest that PAO will give satisfactory function and pain scores in patients aged > 40 years having dysplastic hips as long as there was only mild or no OA. Of great importance is that the risk of THA at five years after PAO was 12% in hips with pre-operative Tönnis Grade 0 or 1 and 27% for Tönnis Grade 2. For hip arthroscopy, the same consensus exists and it is well established that pre-operative OA is a predictor of a poor result.⁴⁶ When comparing patients aged < 30 years and > 50 years, equal improvement was observed in both groups regarding patient-reported outcome measures (PROMs) and pain reduction, although for the older group conversion to a THA within the first two years was observed in 17%.⁶⁵ The influence of pre-operative OA may be the best described and most important parameter predicting outcome of PAO and hip arthroscopy. Recent papers by Millis et al,⁶⁴ Dahl et al⁶⁶ and Hartig-Andreasen agree that OA more than Tönnis Grade 1 is an important single predictor for poor clinical outcome and conversion to THA after PAO.¹⁹ All papers demonstrate that PAO will give excellent functional outcome and reduction of pain in patients with mild (Tönnis Grade 1) or no OA (Tönnis Grade 0).

Two recent studies investigate whether obesity is a risk factor for major complications following PAO.^{36,67} The studies demonstrate that body mass index (BMI) > 30 kg/m² is associated with a 22% major complication rate whereas patients with BMI < 30 kg/m² have a 3% risk of major complications. Hence, the odds of an obese patient developing a major complication were 11 times higher. Obesity did not compromise adequate radiographic correction of acetabular dysplasia.

Another important issue has been explored by Malviya et al,³⁵ who analysed the incidence of stress fracture after PAO under the care of two high-volume surgeons (359 patients included, mean age 31.1 years (15 to 56), with a mean follow-up of 26 months). Eighteen percent of the

patients developed a stress fracture of the inferior pubic ramus, which was noted radiologically at a mean of 9.1 weeks after surgery. All studies addressing age demonstrate that age *per se* is a relative contraindication for PAO, whereas pre-operative OA (Tönnis > 1) and decreased bone quality are more important predictors of a poor result after PAO.

Concomitant femoral osteotomy

In adults and adolescence, often the decision to add a proximal femoral osteotomy is made to improve joint congruency and/or ROM, or to improve the weight-bearing area in a hip joint with secondary arthritis.^{68,69} Several studies, however, point out that these procedures carry a poor prognosis giving poor results, and therefore we consider bad joint congruency, decreased ROM and arthritis as contraindications for PAO surgery (Tables 1 and 2).

Hip arthroscopy: FAI versus dysplasia

Hip arthroscopy in patients with mild to moderate acetabular dysplasia, defined by a CE-angle of 19° to 25°, recently demonstrated short-term improvements in post-operative outcome comparable with those with an CE-angle > 25° in a study by Nawabi et al.⁷⁰ In a similar study, Larsen et al⁵³ concluded that isolated arthroscopic procedures in patients with dysplasia (average CE-angle 20.8°) leads to improvements in patient outcome, though it was inferior when compared with a FAI cohort. Hence, an improved functional outcome but a high risk of repeated surgery and subsequent THA can be expected. Hip arthroscopy in this group of patients should therefore be considered cautiously.⁷¹ The prospect of undergoing a less invasive surgical treatment increases the demand from patients with conditions with a relative contraindication for hip arthroscopy, such as hip dysplasia, acetabular retroversion and arthritis. If these conditions, although they are relative contraindications for hip arthroscopy, are combined with a cam deformity, the surgeon might consider isolated treatment of the cam deformity arthroscopically if the patient still experiences pain and discomfort after PAO. If these patients are considered for treatment arthroscopically following PAO, it is recommended to inform the patient thoroughly as some studies indicate that hip arthroscopy in this group of patients leads to inferior outcome compared with non-dysplastic FAI patients.⁵³

THA as a salvage procedure

It can be argued that a previous PAO poses technical difficulties and may increase the incidence of complications after THA. Parvizi et al⁷² evaluated 41 patients who had THA after PAO with a follow-up averaging 6.9 years. In this series, 50% of the cups were retroverted but there were no dislocations. Two THAs were revised due to

aseptic loosening. A multicentre retrospective review⁷³ compared a matched cohort of patients who underwent THAs for DDH without previous PAO with a similar group receiving THA after PAO. This study did not detect any differences in the clinical outcome, number of complications or revision rates between the two groups. Cup positioning is important and Hartig-Andreasen et al present excellent four- to ten-year follow-up PROMs with a mean cup anteversion of 22° (7° to 43°) and mean cup abduction angle of 45° (28° to 65°).⁷⁴

Conclusions

Several excellent treatments now exist for the painful non-arthritic hip in younger patients. Dysplasia (CE < 25°) or retroverted hips should receive a PAO, whereas patients with FAI and/or labral tears should receive a hip arthroscopy.

Future research should focus on the socio-economic consequences of joint-preserving surgery and THA surgery. Furthermore, there is no uniform definition of outcome. It is important to discuss whether the duration of the period from joint-preserving surgery to THA is the best parameter for describing the success of hip joint-preserving surgery.

AUTHOR INFORMATION

¹Department of Orthopaedic Surgery, Aarhus University Hospital, Denmark.

²Orthopaedic Research Unit, Department of Orthopaedic Surgery and Traumatology, Odense University Hospital, Denmark.

³Section for Sports Traumatology M51, Department of Orthopaedic Surgery, Bispebjerg Hospital, Denmark.

⁴Department of Orthopaedics, Aalborg University Hospital, Denmark.

⁵Department of Orthopaedics, National University Hospital, Denmark.

⁶Department of Orthopaedic Surgery, Copenhagen University Hospital, Gentofte, Denmark.

Correspondence should be sent to: S. Jakobsen, Department of Orthopaedic Surgery, Aarhus University Hospital, DK-8200, Aarhus N, Denmark.
Email: Stig.Jakobsen@ki.au.dk

ICMJE CONFLICT OF INTEREST STATEMENT

S. Overgaard declares board membership of Eli Lilly and Mundipharma International; grants from Biomet Denmark, Biomet Inc, Depuy and Zimmer, activities outside the submitted work.

FUNDING STATEMENT

No benefits in any form have been received or will be received from a commercial party related directly or indirectly to the subject of this article.

LICENCE

© 2018 The author(s)

This article is distributed under the terms of the Creative Commons Attribution-Non Commercial 4.0 International (CC BY-NC 4.0) licence (<https://creativecommons.org/licenses/by-nc/4.0/>) which permits non-commercial use, reproduction and distribution of the work without further permission provided the original work is attributed.

licenses/by-nc/4.0/) which permits non-commercial use, reproduction and distribution of the work without further permission provided the original work is attributed.

REFERENCES

- Ganz R, Parvizi J, Beck M, et al.** Femoroacetabular impingement: a cause for osteoarthritis of the hip. *Clin Orthop Relat Res* 2003;417:112-120.
- Wiberg G.** Studies on dysplastic acetabula and congenital subluxation of the hip joint with special reference to the complication of osteoarthritis. *Acta Chir Scand* 1939;83(suppl 58):5-135.
- Hartig-Andreasen C, Søballe K, Troelsen A.** The role of the acetabular labrum in hip dysplasia. A literature overview. *Acta Orthop* 2013;84(1):60-64.
- Reynolds D, Lucas J, Klaue K.** Retroversion of the acetabulum. A cause of hip pain. *J Bone Joint Surg [Br]* 1999;81-B(2):281-288.
- Poh SY, Hube R, Dienst M.** Arthroscopic treatment of femoroacetabular pincer impingement. *Oper Orthop Traumatol* 2015;27(6):536-552.
- Reiman MP, Thorborg K.** Femoroacetabular impingement surgery: are we moving too fast and too far beyond the evidence? *Br J Sports Med* 2015;49(12):782-784.
- Ninomiya S, Tagawa H.** Rotational acetabular osteotomy for the dysplastic hip. *J Bone Joint Surg [Am]* 1984;66-A(3):430-436.
- Ganz R, Klaue K, Vinh TS, Mast JW.** A new periacetabular osteotomy for the treatment of hip dysplasias. Technique and preliminary results. *Clin Orthop Relat Res* 1988;232:26-36.
- Tijssen M, van Cingel RE, de Visser E, Holmich P, Nijhuis-van der Sanden MW.** Hip joint pathology: relationship between patient history, physical tests, and arthroscopy findings in clinical practice. *Scand J Med Sci Sports* 2017;27(3):342-350.
- Troelsen A, Mechlenburg I, Gelineck J, et al.** What is the role of clinical tests and ultrasound in acetabular labral tear diagnostics? *Acta Orthop* 2009;80(3):314-318.
- Kivlan BR, Martin RL, Sekiya JK.** Response to diagnostic injection in patients with femoroacetabular impingement, labral tears, chondral lesions, and extra-articular pathology. *Arthroscopy* 2011;27(5):619-627.
- Chandrasekaran S, Lodhia P, Suarez-Ahedo C, et al.** Symposium: evidence for the use of intra-articular cortisone or hyaluronic acid injection in the hip. *J Hip Preserv Surg* 2015;3(1):5-15.
- Spruit M, Van Goethem CJ, Kooijman MA, Pavlov PW.** Diagnostic infiltration of the hip joint with bupivacain in adult acetabular dysplasia. *Acta Orthop Belg* 1997;63(4):274-277.
- Troelsen A, Jacobsen S, Rømer L, Søballe K.** Weightbearing anteroposterior pelvic radiographs are recommended in DDH assessment. *Clin Orthop Relat Res* 2008;466(4):813-819.
- Siebenrock KA, Schaller C, Tannast M, Keel M, Büchler L.** Anteverting periacetabular osteotomy for symptomatic acetabular retroversion: results at ten years. *J Bone Joint Surg [Am]* 2014;96-A(21):1785-1792.
- Tannast M, Murphy SB, Langlotz F, Anderson SE, Siebenrock KA.** Estimation of pelvic tilt on anteroposterior X-rays—a comparison of six parameters. *Skeletal Radiol* 2006;35(3):149-155.
- Nho SJ, Leunig M, Larson CM, Bedi A, Kelly BT, eds.** *Hip Arthroscopy and Hip Joint Preservation Surgery*; vol 1. New York, NY: Springer-Verlag New York Inc., 2015.
- Nho SJ, Leunig M, Larson CM, Bedi A, Kelly BT, eds.** *Hip Arthroscopy and Hip Joint Preservation Surgery*; vol 2. New York, NY: Springer-Verlag New York Inc., 2015.

19. **Hartig-Andreasen C, Troelsen A, Thillemann TM, Søballe K.** What factors predict failure 4 to 12 years after periacetabular osteotomy? *Clin Orthop Relat Res* 2012;470(11):2978-2987.
20. **Hipp JA, Sugano N, Millis MB, Murphy SB.** Planning acetabular redirection osteotomies based on joint contact pressures. *Clin Orthop Relat Res* 1999;364:134-143.
21. **Kralj M, Mavcic B, Antolic V, Igljic A, Kralj-Igljic V.** The Bernese periacetabular osteotomy: clinical, radiographic and mechanical 7-15-year follow-up of 26 hips. *Acta Orthop* 2005;76(6):833-840.
22. **Trousdale RT, Cabanela ME.** Lessons learned after more than 250 periacetabular osteotomies. *Acta Orthop Scand* 2003;74(2):119-126.
23. **Mechnlenburg I, Nyengaard JR, Gelineck J, De Raedt S, Søballe K.** Cyst volume in the acetabulum and femoral head decreases after periacetabular osteotomy. *Hip Int* 2012;22(3):313-318.
24. **Troelsen A, Elmengaard B, Søballe K.** A new minimally invasive transartorial approach for periacetabular osteotomy. *J Bone Joint Surg [Am]* 2008;90-A(3):493-498.
25. **Trousdale RT, Ekernkamp A, Ganz R, Wallrichs SL.** Periacetabular and intertrochanteric osteotomy for the treatment of osteoarthritis in dysplastic hips. *J Bone Joint Surg [Am]* 1995;77-A(1):73-85.
26. **Matta JM, Stover MD, Siebenrock K.** Periacetabular osteotomy through the Smith-Petersen approach. *Clin Orthop Relat Res* 1999;363:21-32.
27. **Trumble SJ, Mayo KA, Mast JW.** The periacetabular osteotomy. Minimum 2 year followup in more than 100 hips. *Clin Orthop Relat Res* 1999;363:54-63.
28. **Clohisy JC, Barrett SE, Gordon JE, Delgado ED, Schoenecker PL.** Periacetabular osteotomy for the treatment of severe acetabular dysplasia. *J Bone Joint Surg [Am]* 2005;87-A(2):254-259.
29. **Peters CL, Erickson JA, Hines JL.** Early results of the Bernese periacetabular osteotomy: the learning curve at an academic medical center. *J Bone Joint Surg [Am]* 2006;88-A(9):1920-1926.
30. **Garras DN, Crowder TT, Olson SA.** Medium-term results of the Bernese periacetabular osteotomy in the treatment of symptomatic developmental dysplasia of the hip. *J Bone Joint Surg [Br]* 2007;89-A(6):721-724.
31. **Pogliacomini F, Stark A, Wallensten R.** Periacetabular osteotomy. Good pain relief in symptomatic hip dysplasia, 32 patients followed for 4 years. *Acta Orthop* 2005;76(1):67-74.
32. **Murphy S, Deshmukh R.** Periacetabular osteotomy: preoperative radiographic predictors of outcome. *Clin Orthop Relat Res* 2002;405:168-174.
33. **Valenzuela RG, Cabanela ME, Trousdale RT.** Sexual activity, pregnancy, and childbirth after periacetabular osteotomy. *Clin Orthop Relat Res* 2004;418:146-152.
34. **Davey JP, Santore RF.** Complications of periacetabular osteotomy. *Clin Orthop Relat Res* 1999;363:33-37.
35. **Malviya A, Dandachli W, Beech Z, Bankes MJ, Witt JD.** The incidence of stress fracture following peri-acetabular osteotomy: an under-reported complication. *Bone Joint J* 2015;97-B(1):24-28.
36. **Novais EN, Potter GD, Clohisy JC, et al.** Obesity is a major risk factor for the development of complications after peri-acetabular osteotomy. *Bone Joint J* 2015;97-B(1):29-34.
37. **Steppacher SD, Tannast M, Ganz R, Siebenrock KA.** Mean 20-year followup of Bernese periacetabular osteotomy. *Clin Orthop Relat Res* 2008;466(7):1633-1644.
38. **Matheny T, Kim YJ, Zurakowski D, Matero C, Millis M.** Intermediate to long-term results following the Bernese periacetabular osteotomy and predictors of clinical outcome. *J Bone Joint Surg [Am]* 2009;91-A(9):2113-2123.
39. **Troelsen A, Elmengaard B, Søballe K.** Medium-term outcome of periacetabular osteotomy and predictors of conversion to total hip replacement. *J Bone Joint Surg [Am]* 2009;91-A(9):2169-2179.
40. **Lerch TD, Steppacher SD, Liechti EF, Tannast M, Siebenrock KA.** One-third of hips after periacetabular osteotomy survive 30 years with good clinical results, no progression of arthritis, or conversion to THA. *Clin Orthop Relat Res* 2017;475(4):1154-1168.
41. **Okano K, Enomoto H, Osaki M, Shindo H.** Joint congruency as an indication for rotational acetabular osteotomy. *Clin Orthop Relat Res* 2009;467(4):894-900.
42. **Schmigelow V, Viberg B, Ovesen O, Overgaard S.** The effect of PAO on the clinical outcome in patients with retroverted acetabulum – a prospective cohort study [abstract]. *EFORT Congress*, 2015.
43. **Jamali AA, Mladenov K, Meyer DC, et al.** Anteroposterior pelvic radiographs to assess acetabular retroversion: high validity of the “cross-over-sign”. *J Orthop Res* 2007;25(6):758-765.
44. **Parry JA, Swann RP, Erickson JA, et al.** Midterm outcomes of reverse (anteverting) periacetabular osteotomy in patients with hip impingement secondary to acetabular retroversion. *Am J Sports Med* 2016;44(3):672-676.
45. **Zurmühle CA, Anwander H, Albers CE, et al.** Periacetabular osteotomy provides higher survivorship than rim trimming for acetabular retroversion. *Clin Orthop Relat Res* 2017;475(4):1138-1150.
46. **Domb BG, Gui C, Lodhia P.** How much arthritis is too much for hip arthroscopy: a systematic review. *Arthroscopy* 2015;31(3):520-529.
47. **Malviya A, Raza A, Jameson S, et al.** Complications and survival analyses of hip arthroscopies performed in the national health service in England: a review of 6,395 cases. *Arthroscopy* 2015;31(5):836-842.
48. **Agricola R, Waarsing JH, Thomas GE, et al.** Cam impingement: defining the presence of a cam deformity by the alpha angle: data from the CHECK cohort and Chingford cohort. *Osteoarthritis Cartilage* 2014;22(2):218-225.
49. **Frank JM, Harris JD, Erickson BJ, et al.** Prevalence of femoroacetabular impingement imaging findings in asymptomatic volunteers: a systematic review. *Arthroscopy* 2015;31(6):1199-1204.
50. **Griffin DR, Dickenson EJ, O'Donnell J, et al.** Infographic. The Warwick Agreement on femoroacetabular impingement syndrome. *Br J Sports Med* 2016; 50(19):1179.
51. **Zaltz I, Kelly BT, Larson CM, Leunig M, Bedi A.** Surgical treatment of femoroacetabular impingement: what are the limits of hip arthroscopy? *Arthroscopy* 2014;30(1):99-110.
52. **Nwachukwu BU, Rebolledo BJ, McCormick F, et al.** Arthroscopic versus open treatment of femoroacetabular impingement: a systematic review of medium- to long-term outcomes. *Am J Sports Med* 2016;44(4):1062-1068.
53. **Larson CM, Ross JR, Stone RM, et al.** Arthroscopic management of dysplastic hip deformities: predictors of success and failures with comparison to an arthroscopic FAI cohort. *Am J Sports Med* 2016;44(2):447-453.
54. **Harris JD, McCormick FM, Abrams GD, et al.** Complications and reoperations during and after hip arthroscopy: a systematic review of 92 studies and more than 6,000 patients. *Arthroscopy* 2013;29(3):589-595.
55. **Weber AE, Harris JD, Nho SJ.** Complications in hip arthroscopy: a systematic review and strategies for prevention. *Sports Med Arthrosc Rev* 2015;23(4):187-193.

- 56. Nakano N, Lisenda L, Jones TL, Loveday DT, Khanduja V.** Complications following arthroscopic surgery of the hip: a systematic review of 36 761 cases. *Bone Joint J* 2017;99-B(12):1577-1583.
- 57. Gupta A, Redmond JM, Hammarstedt JE, Schwindel L, Domb BG.** Safety measures in hip arthroscopy and their efficacy in minimizing complications: a systematic review of the evidence. *Arthroscopy* 2014;30(10):1342-1348.
- 58. Philippon MJ, Briggs KK, Yen YM, Kuppersmith DA.** Outcomes following hip arthroscopy for femoroacetabular impingement with associated chondrolabral dysfunction: minimum two-year follow-up. *J Bone Joint Surg [Br]* 2009;91-B(1):16-23.
- 59. Dippmann C, Thorborg K, Kraemer O, et al.** Hip arthroscopy with labral repair for femoroacetabular impingement: short-term outcomes. *Knee Surg Sports Traumatol Arthrosc* 2014;22(4):744-749.
- 60. Mygind-Klavsen B, Nielsen TG, Maagaard N, et al.** Danish Hip Arthroscopy Registry: an epidemiologic and perioperative description of the first 2000 procedures. *J Hip Preserv Surg* 2016;3(2):138-145.
- 61. McCormick F, Nwachukwu BU, Alpaugh K, Martin SD.** Predictors of hip arthroscopy outcomes for labral tears at minimum 2-year follow-up: the influence of age and arthritis. *Arthroscopy* 2012;28(10):1359-1364.
- 62. Gray BL, Stambough JB, Baca GR, Schoenecker PL, Clohisy JC.** Comparison of contemporary periacetabular osteotomy for hip dysplasia with total hip arthroplasty for hip osteoarthritis. *Bone Joint J* 2015;97-B(10):1322-1327.
- 63. Garbuz DS, Awwad MA, Duncan CP.** Periacetabular osteotomy and total hip arthroplasty in patients older than 40 years. *J Arthroplasty* 2008;23(7):960-963.
- 64. Millis MB, Kain M, Sierra R, et al.** Periacetabular osteotomy for acetabular dysplasia in patients older than 40 years: a preliminary study. *Clin Orthop Relat Res* 2009;467(9):2228-2234.
- 65. Domb BG, Linder D, Finley Z, et al.** Outcomes of hip arthroscopy in patients aged 50 years or older compared with a matched-pair control of patients aged 30 years or younger. *Arthroscopy* 2015;31(2):231-238.
- 66. Dahl LB, Densø K, Bang-Christiansen K, Petersen MM, Stürup J.** Clinical and radiological outcome after periacetabular osteotomy: a cross-sectional study of 127 hips operated on from 1999-2008. *Hip Int* 2014;24(4):369-380.
- 67. Novais EN, Potter GD, Sierra RJ, et al.** Surgical treatment of adolescent acetabular dysplasia with a periacetabular osteotomy: does obesity increase the risk of complications? *J Pediatr Orthop* 2015;35(6):561-564.
- 68. Ito H, Matsuno T, Minami A.** Intertrochanteric varus osteotomy for osteoarthritis in patients with hip dysplasia: 6 to 28 years followup. *Clin Orthop Relat Res* 2005;433:124-128.
- 69. Gala L, Clohisy JC, Beaulé PE.** Hip dysplasia in the young adult. *J Bone Joint Surg [Am]* 2016;98(1):63-73.
- 70. Nawabi DH, Degen RM, Fields KG, et al.** Outcomes after arthroscopic treatment of femoroacetabular impingement for patients with borderline hip dysplasia. *Am J Sports Med* 2016;44(4):1017-1023.
- 71. Yeung M, Kowalczyk M, Simunovic N, Ayeni OR.** Hip arthroscopy in the setting of hip dysplasia: A systematic review. *Bone Joint Res* 2016;5(6):225-231.
- 72. Parvizi J, Burmeister H, Ganz R.** Previous Bernese periacetabular osteotomy does not compromise the results of total hip arthroplasty. *Clin Orthop Relat Res* 2004;423:118-122.
- 73. Amanatullah DF, Stryker L, Schoenecker P, et al.** Similar clinical outcomes for THAs with and without prior periacetabular osteotomy. *Clin Orthop Relat Res* 2015;473(2):685-691.
- 74. Hartig-Andreasen C, Stilling M, Søballe K, Thillemann TM, Troelsen A.** Is cup positioning challenged in hips previously treated with periacetabular osteotomy? *J Arthroplasty* 2014;29(4):763-768.