

Hypertrophied appendix epiploica strangulated in inguinal canal presenting as acute abdomen

A case report

Luong, Thien Vinh; El-Hussuna, Alaa

Published in:
International Journal of Surgery Open

DOI (link to publication from Publisher):
[10.1016/j.ijso.2018.08.004](https://doi.org/10.1016/j.ijso.2018.08.004)

Creative Commons License
CC BY-NC-ND 4.0

Publication date:
2018

Document Version
Publisher's PDF, also known as Version of record

[Link to publication from Aalborg University](#)

Citation for published version (APA):
Luong, T. V., & El-Hussuna, A. (2018). Hypertrophied appendix epiploica strangulated in inguinal canal presenting as acute abdomen: A case report. *International Journal of Surgery Open*, 14, 27-29.
<https://doi.org/10.1016/j.ijso.2018.08.004>

General rights

Copyright and moral rights for the publications made accessible in the public portal are retained by the authors and/or other copyright owners and it is a condition of accessing publications that users recognise and abide by the legal requirements associated with these rights.

- Users may download and print one copy of any publication from the public portal for the purpose of private study or research.
- You may not further distribute the material or use it for any profit-making activity or commercial gain
- You may freely distribute the URL identifying the publication in the public portal -

Take down policy

If you believe that this document breaches copyright please contact us at vbn@aub.aau.dk providing details, and we will remove access to the work immediately and investigate your claim.



Case Report

Hypertrophied appendix epiploica strangulated in inguinal canal presenting as acute abdomen: A case report

Thien Vinh Luong^{a,*}, Alaa El-Hussuna^b^a Emergency Department, Randers Hospital, Skovlyvej 15, 8930 Randers NØ, Denmark^b Department of Surgery, Aalborg University Hospital, Hobrovej 22, 9000 Aalborg, Denmark

ARTICLE INFO

Article history:

Received 10 July 2018

Received in revised form

24 August 2018

Accepted 25 August 2018

Available online 13 September 2018

Keywords:

Epiploic appendices

Inguinal hernia

Irreducible inguinal hernia

Strangulation

Acute abdomen

Case report

ABSTRACT

Introduction: Different illnesses can affect the Epiploic Appendices (EA) of the Colon. Strangulation of the EA has previously been described inside a hernia sack associated with bowel herniation, but it is rarely presented as the only entity. This is the first case where a hypertrophied EA presented as acute abdomen mimicking a strangulated inguinal hernia.

Presentation of the case: We present a case of a 71-year-old male who was admitted to the emergency department with acute pain around the left inguinal area. A firm mass measuring 5 × 6 cm had appeared sneezing, and had persisted for 24 hours with no nausea or vomiting. The patient had normal bowel motion on the same day. The hernia was not reducible. Because of suspicion of bowel strangulation inside the hernia sack, acute surgical intervention was performed. A hypertrophied EA was found in the hernia sack and treated with open herniotomy. The postoperative period was uneventful and the patient was discharged in good health four days following the operation.

Discussion: Epiploic appendagitis caused by inflammation or strangulation can mimic other causes of acute abdomen but often presents a less severe clinical picture. The patient suffered from a strangulated hernia containing a hypertrophic EA. To our knowledge, this is the first case report of a hypertrophied EA inside an inguinal hernia requiring immediate operation.

Conclusion: Hypertrophied EA can mimic a strangulated hernia. High index of suspicion is needed to diagnose this rare condition. Surgical intervention can both confirm the diagnosis and treat the condition.

© 2018 The Authors. Published by Elsevier Ltd on behalf of Surgical Associates Ltd. This is an open access article under the CC BY-NC-ND license (<http://creativecommons.org/licenses/by-nc-nd/4.0/>).

1. Introduction

Three anatomic features exist on the serosal surface of the large bowel in humans, which makes it easy to distinguish it from other parts of the bowel in the abdomen. The taeniae coli are longitudinal muscle fibers and can be seen running along the colon. They contract lengthwise and create the haustra coli. These can be seen as sacculations of the colonic wall between the taeniae and transverse folds known as plicae semilunares coli, which give the colon a segmented appearance. The third feature is called epiploic appendices (EA). These small adipose pouches protrude from the serosal surface of the colon. They consist of peritoneum filled with fat and are situated along the colon, mainly in the transverse and sigmoid part, but are absent in the rectum. Upon visual inspection, they are

lobulated masses of pericolic fat ranging in size from 2 to 5 cm in length and 1–2 cm wide [1]. Many different etiologies can cause illness in the EA. They can be affected by spontaneous torsion and hemorrhagic infarct, which causes an acute necrosis of the tissue. Benign processes such as calcification due to aseptic fat necrosis, as well as primary or secondary inflammation - called epiploic appendagitis - produces a slower onset of symptoms. Hypertrophy of the tissue caused by lipomas or metastases have also been described [1,2]. Finally, they can be subjected to incarceration and seldom to strangulation in hernias, the latter of which we will present and describe in this case report.

The clinical presentation of a strangulated hernia with bowel content includes a visible protruded mass, which can't be manipulated back into the abdomen, severe abdominal pain, nausea, vomiting, anorexia, and fever. However, in diseases involving EA, the symptoms are more subdued. Epiploic appendagitis can be caused by torsion leading to acute infarction and inflammation mimicking a variety of illnesses such as acute appendicitis,

* Corresponding author.

E-mail address: thiluo@rm.dk (T. Vinh Luong).

diverticulitis, and others. The condition is self-limited; therefore, a correct diagnosis need to be obtained before intervention [3]. This work has been reported in line with the SCARE criteria [4].

2. Case presentation

A 71-year-old male patient was urgently admitted to the emergency department and presented with pain and redness in the lower abdomen, left inguinal region, and scrotum. Moreover, there was a firm mass protruding from the inguinal area. The symptoms appeared abruptly after the patient blew his nose and had persisted for approximately 24 hours before admission. There had been no improvement in the patient's condition during this time. An effort by the General Practitioner to reduce the mass was not attempted because of the size of the hernia. The patient had one defecation on the first day and did not have any trouble with food and water intake nor had he experienced any episodes of nausea or vomiting. The patient had undergone elective surgery two years ago for a reducible right inguinal hernia. Otherwise, the patient was healthy and took no medications at the time of admission.

No fever was observed and all his vital signs were normal. An increased CRP up to 157.6 and LDH to 108 up to were detected. The white cell count, hemoglobin level, amylase level, and liver and renal function were all in the normal range. Upon examination, the patient's abdomen was soft, but slightly distended. There was direct tenderness in the lower abdomen and around the hernia, as well as swelling and redness of the skin around the groin and scrotum. A slight rebound tenderness was observed, but no indirect tenderness was detected, indicating absence of peritoneal reaction. Normal bowel sounds were heard. The hernia was estimated to be 5 × 6 cm in size. We were unable to manipulate it back into the abdomen under a cover of morphine and diazepam. These findings led us to the suspicion that the patient had a hernia with bowel strangulation. Therefore, no diagnostic imaging was performed. The patient was promptly admitted to emergency theater.

Operation under general anesthesia was performed via incision parallel to the left inguinal ligament. The size of the EA made several differential diagnoses possible (Fig. 1). Upon exploring the mass after incision, a rubber-solid smooth mass originating from the abdomen was palpated (Fig. 2). Sigmoid colon could be pulled and inspected through the incision. The diagnosis was confirmed

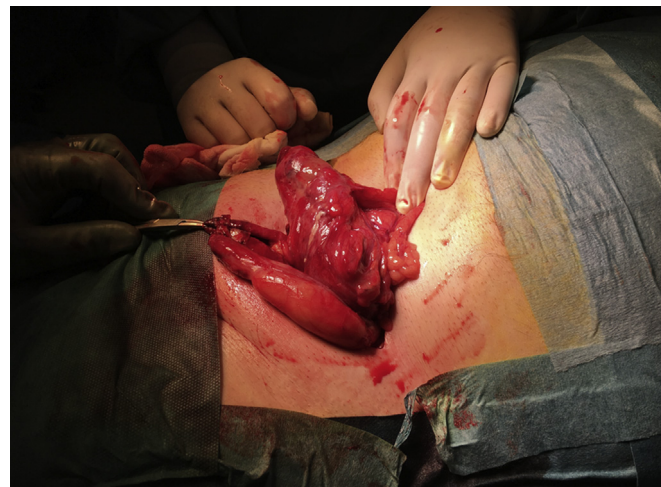

Fig. 2. The hernia sack was opened and access to the intra-peritoneal cavity was established. The colon was then retracted and the diagnosis of a hypertrophied EA was confirmed followed by an uncomplicated resection of the EA.

by diagnostic laparoscopy that showed a healthy colon. The mass was excised and herniotomy ad modum Lichtenstein was performed. Histopathological examination revealed a reactively affected mesothelial adipose tissue due to infiltration by various immune cells including neutrophils granulocytes, lymphocytes, and macrophages. No evidence of malignancy was detected. The Postoperative course was uneventful and the patient was discharged 4 days after operation in good health.

3. Discussion

Inguinal hernias are a common surgical problem in the general population. Males are more prone to develop inguinal hernias, due to the descent of the testes during fetal development, possibly creating a fascial defect in the abdominal wall. This condition affects men nine times more often than women. In addition, an age-specific bimodal distribution has been observed with a peak-prevalence in the age group of 0–5 years and 75–80 years [5]. The contents inside the hernial sacks vary: they can consist of certain parts of the colon, vermiform appendix, urinary bladder, ovaries, lipomas, and other tissues [6]. However, epiploic appendages of the colon are one of the rarest type of hernial content, having only been described by a few [1,3,6–8]. Two similar cases have previously been reported [3,7]. However, in both cases the patients had a history with an inguinal mass for more than 6 months and were known to have recurrent episodes of strangulation. The clinical diagnosis was made using ultrasound imaging and through observation, and therefore did not present themselves as acute abdomen upon arrival to the hospital. Both EA were resected and did not show heavy signs of hypertrophy as in our case. Generally, the pain has been described to be in the lower quadrants of the abdomen, most often on the left side due to the anatomical placement of the sigmoid colon. This has also been confirmed by imaging modalities, suggesting that the most common side of EA within an inguinal hernia is on the left side [9,10]. The symptoms associated with illnesses affecting the EA can mimic other pathologies leading to acute abdomen. They are less likely to lead to operation due to a less severe presentation of symptoms such as abdominal pain, nausea, vomiting, and fever. EA within a hernia is also a less serious condition compared to a hernia containing to bowel contents. However, the hernia can still present itself with an acute appearance depending on its size and degree of irreducibility.

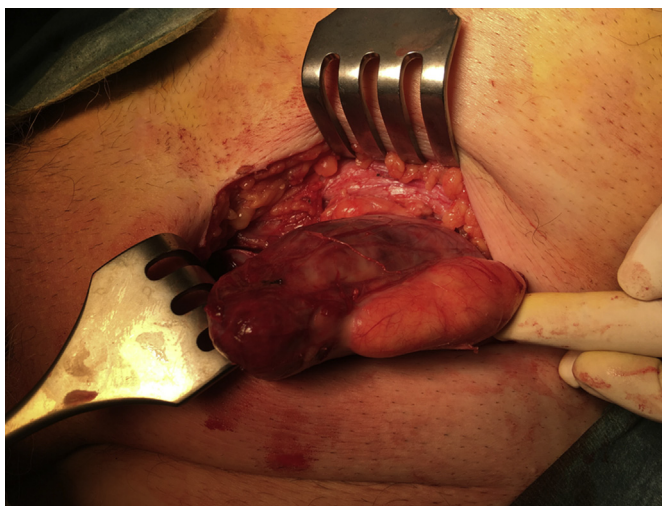


Fig. 1. The intra-operative findings seen after transvers incision parallel to the inguinal ligament. The consistency of the mass made the diagnosis difficult. Both testicles were palpable in the scrotum.

Inside an incarcerated hernia, EA can be a small, irreducible mass without causing any obstruction or inflammation, resulting in spontaneous recovery [11]. On the other hand, a sizable strangulated hernia with epiploic content will result in a compromised blood supply, leading to inflammation and necrosis, which require acute surgery.

Hypertrophied EA has earlier been described to be related to colonic lipomatosis in two cases involving young patients [2,12]. Both presented with diffuse abdominal symptoms that were not associated with a hernia, possibly due to their young age. A correlation between hypertrophy of the EA and certain factors such as obesity, genetics or age has not yet been established. The rare condition has not previously been linked to any case of acute abdomen, signifying that it rarely leads to a pathological condition with acute symptoms. Presumably, this could suggest that more people are affected by this condition without showing any signs of illness.

Other studies have suggested the necessity of preoperative diagnosis using imaging techniques, such as Ultrasound and CT scan, to prevent unnecessary operations [11,13,14]. In these cases, there were either no strangulation or the diagnosis of a strangulated EA within a hernia was an accidental finding at the time of radiological diagnostics. In our case, a suspicion of a strangulated bowel segment in an inguinal hernia sack led to a prompt admission to the emergency theater. To avoid any delay in the management, diagnostic imaging was not done.

4. Conclusion

EA can herniate through the abdominal wall and present itself as an acute irreducible inguinal hernia. We present the first case of a hypertrophied EA inside a strangulated inguinal hernia leading to acute surgical intervention. High index of suspicion is needed to identify this rare condition, and initiation of diagnostic imaging could help to identify it. However, diagnostic imaging should not delay surgery, as surgery can both confirm the diagnosis and treat the rare condition.

Ethical approval

As this is a case report, no ethical approval was necessary.

Funding

This research did not receive any specific grant from funding agencies in the public, commercial, or not-for-profit sectors.

Author contribution

Both authors contributed to conception of the project, data collection, writing the manuscript and proof readings.

Conflict of interest statement

None.

Guarantor

Dr. Alaa El-Hussuna, Consultant Surgeon.
Dr. Thien Vinh Luong, Research Substitute.

Research registration number

No registration is required.

Patient consent

Obtained.

Consent

Written informed consent was obtained from the patient for publication of this case report and accompanying images. A copy of the written consent is available for review by the Editor-in-Chief of this journal on request.

References

- [1] Ghahremani GG, White EM, Hoff FL, Gore RM, Miller JW, Christ ML. Appendices epiploicae of the colon: radiologic and pathologic features. *Radiographics* 1992;12(1):59–77.
- [2] Swain VA, Young WF, Pringle EM. Hypertrophy of the appendices epiploicae and lipomatous polyposis of the colon. *Gut* 1969;10(7):587–9.
- [3] Kulacoglu H, Tumer H, Aktimur R, Kusdemir A. Epiploic appendicitis in inguinal hernia sac presenting an inguinal mass. *Hernia* 2005;9(3):288–90.
- [4] Agha RA, Fowler AJ, Saeta A, Barai I, Rajmohan S, Orgill DP. The SCARE Statement: consensus-based surgical case report guidelines. *Int J Surg* 2016;34:180–6.
- [5] Burcharth J, Pedersen M, Bisgaard T, Pedersen C, Rosenberg J. Nationwide prevalence of groin hernia repair. *PLoS One* 2013;8(1):e54367.
- [6] Ballas K, Kontoulis TH, Skouras CH, Triantafyllou A, Symeonidis N, Pavlidis TH, et al. Unusual findings in inguinal hernia surgery: report of 6 rare cases. *Hippokratia* 2009;13(3):169–71.
- [7] Shiryajev YN, Glebova AV, Chalenko MV. Strangulation and necrosis of an epiploic appendage of the sigmoid colon in a right inguinal hernia. *Case Rep Surg* 2013;2013:890234.
- [8] Abdulzhavadov IM. Volvulus of the epiploic appendices of the sigmoid in strangulated inguinal hernia. *Klin Med (Mosk)* 1989;67(1):126–7.
- [9] Ozkurt H, Karatag O, Karaarslan E, Basak M. Clinical and CT findings of epiploic appendagitis within an inguinal hernia. *Diagn Interv Radiol* 2007;13(1):23–5.
- [10] Sirvanci M, Tekelioglu MH, Duran C, Yardimci H, Onat L, Ozer K. Primary epiploic appendagitis: CT manifestations. *Clin Imag* 2000;24(6):357–61.
- [11] Singh AK, Gervais D, Rhea J, Mueller P, Noveline RA. Acute epiploic appendagitis in hernia sac: CT appearance. *Emerg Radiol* 2005;11(4):226–7.
- [12] Catania G, Petralia GA, Migliore M, Cardì F. Diffuse colonic lipomatosis with giant hypertrophy of the epiploic appendices and diverticulosis of the colon. Report of a case and review of the literature. *Dis Colon Rectum* 1995;38(7):769–75.
- [13] Capaccio E, Di Vito L, Derchi LE. Epiploic appendage torsed within a spigelian hernia: US and CT findings. *J Clin Ultrasound* 2012;40(5):310–3.
- [14] Yau KK, Siu WT, Chan KL. Strangulated appendix epiploica in paraumbilical hernia: preoperative diagnosis and laparoscopic treatment. *Surg Laparosc Endosc Percutaneous Tech* 2006;16(1):49–51.