



Foetal sex determination at the second trimester anomaly scan in Denmark

Størup, Gitte; Sørensen, Anne Nødgaard; Dalsgaard, Annemarie; Grønkjær, Mette

Published in:
Danish Medical Journal

Creative Commons License
CC BY-NC 4.0

Publication date:
2019

Document Version
Publisher's PDF, also known as Version of record

[Link to publication from Aalborg University](#)

Citation for published version (APA):
Størup, G., Sørensen, A. N., Dalsgaard, A., & Grønkjær, M. (2019). Foetal sex determination at the second trimester anomaly scan in Denmark. *Danish Medical Journal*, 66(12), Article A5580.
https://ugeskriftet.dk/files/scientific_article_files/2019-11/a5580_0.pdf

General rights

Copyright and moral rights for the publications made accessible in the public portal are retained by the authors and/or other copyright owners and it is a condition of accessing publications that users recognise and abide by the legal requirements associated with these rights.

- Users may download and print one copy of any publication from the public portal for the purpose of private study or research.
- You may not further distribute the material or use it for any profit-making activity or commercial gain
- You may freely distribute the URL identifying the publication in the public portal -

Take down policy

If you believe that this document breaches copyright please contact us at vbn@aub.aau.dk providing details, and we will remove access to the work immediately and investigate your claim.

Foetal sex determination at the second trimester anomaly scan in Denmark

Gitte Størup¹, Anne Nødgaard Sørensen^{1, 2}, Annemarie Dalsgaard³ & Mette GrønkJær^{2, 4}

ABSTRACT

INTRODUCTION: For decades, ultrasound has enabled determination of foetal sex. Foetal sex is medically indicated in sex-linked diseases, syndromes and multiple pregnancy, but genital malformations are rare. However, guidelines on standard views seem sparse and foetal sex determination is not considered mandatory. The aim of this study was to provide an initial overview on the practice of foetal sex determination in Denmark and the accuracy of the examinations at the second-trimester anomaly scan at a regional and a university hospital.

METHODS: Phone interviews from all 23 Danish foetal medicine departments concerning information, examination, registration, quality criteria and assessment of accuracy. The accuracy of foetal sex determination was assessed in 5,786 singleton pregnancies with live births at two departments by comparison of data from the second-trimester anomaly scan (week 18 + 0 – 21 + 6) with the national Danish birth register.

RESULTS: Second-trimester foetal sex determination was not mandatory but conducted without guideline. Various approaches to information and documentation were used. Foetal sex was assessed in 86.7% of cases and the accuracy was 99.2% with no significant difference between the regional and the university hospital of the study. Sex determination was more inaccurate in females (18/2,118) than in males (18/2,271), $p < 0.0001$.

CONCLUSIONS: Foetal sex determination by ultrasound is common practice in Denmark. No guideline existed and incorrect sex was determined in 8/1,000 fetuses, most often females. Foetal sex determination should be standardised extensively to avoid false diagnoses.

FUNDING: none.

TRIAL REGISTRATION: This study was approved by the Danish Data Protection Agency (record number: 2012-41-0050).

Foetal sex determination by ultrasound has been studied for years and results on how and when to assess the foetal gender are well-described [1-5]. Direct visualisation with sagittal, transverse and tangential projections in the second and third trimester and the sagittal sign in late first and early second trimester can determine both male and female genitals [1-6].

Determining the foetal gender is medically indicated in cases of sex-linked diseases, syndromes, mal-

formations or multiple pregnancy [7, 8]. In the second-trimester anomaly scan, however, foetal sex determination is not mandatory, and guidelines are sparse and inadequate with no technical requirements for standard views or documentation of gender findings [9-13]. It seems that there is more focus on why not to disclose the foetal sex in an ethical perspective than on how to determine the foetal sex professionally. Thus, detection of ambiguous or malformed external genitals may be incomplete. Pajkrt et al reported a diagnostic approach to foetal genital anomalies, but the assessment did not address the prevalence of genital malformations and the accuracy of sex determination [14]. A Swedish study of 16,775 fetuses examined in weeks 18 and 32 showed a prevalence of minor structural genital malformations at 3.8/1,000 and major malformations at 0.7/1,000 [15].

Foetal sex is often predominantly reported on parental request. Several studies show that approximately 57-75% of expecting parents request foetal sex determination at the second-trimester scan [2, 6, 16]. But on basis of the large Swedish SWEPP study, Larsson et al showed that as much as 95.8% of pregnant women have discussed foetal sex determination with their partner prior to the ultrasound examination [16]. Other studies have shown that incorrectly determined or undesired foetal sex may influence the mother in terms of obstetrical complications, psychological and marital problems [17]. The schism between the professional diagnosis of genital malformations and the parental expectations of foetal sex disclosure raises a need to differentiate the abilities and registration of the ultrasound examinations.

At 92% uptake, Danish healthcare offers a first-trimester screening for chromosomal abnormalities and major defects and a second-trimester anomaly scan in all pregnancies. All ultrasound examinations are registered in the Astraia database (Astraia software gmbh, Munich, Germany), and foetal sex at birth is reported to the Danish National Birth register. However, national data on foetal sex determination are not included, and accuracy is not assessed. Thus, the aim of this study was not to describe detection of genital malformations, but to provide an initial overview on the practice of foetal sex determination by the second-tri-

ORIGINAL ARTICLE

- 1) Department of Obstetrics and Gynaecology, Aalborg University Hospital
- 2) Department of Clinical Medicine, Aalborg University
- 3) University College Northern Jutland, Hjørring
- 4) Clinical Nursing Research Unit, Aalborg University Hospital, Denmark

Dan Med J
2019;66(12):A5580

mester anomaly scan in Denmark and the accuracy of the foetal sex determinations undertaken at two Danish foetal medicine departments.

METHODS

Practice of foetal sex determination

Data on the practice of foetal sex determination were collected through structured phone interviews of one random sonographer from each of the 23 Danish foetal medicine departments in the course of March 2012. The questions concerned the experiences of foetal sex determination offered in each unit: time of examination in pregnancy, staff performing the examination, the information given on the subject (oral, written, website), registration, image documentation, quality criteria and accuracy assessment. Responses with a quantitative content were registered in Excel and calculated as absolute numbers.

Accuracy of foetal sex determination

Quality assessment of foetal sex determination was studied through retrospective quantitative comparison of foetal sex determined and registered in the Astraia database at the second-trimester anomaly scan with reported foetal sex from the birth register at two foetal medicine departments in Denmark: one regional hospital (n = 1,164) and one university hospital (n = 4,622). The sample included foetal sex from all singleton pregnancies (n = 5,786) with live births in 2011 and data on foetal sex determination from the anomaly scan undertaken at gestational week 18 + 0 – 21 + 6. Live births with a possible chorionic villus sampling (CVS) or amniocentesis (AC) undertaken during preg-

nancy were included in the study, as information on genetic testing was not available in the dataset. Non-invasive prenatal testing (NIPT) was not introduced on a larger scale in Denmark until 2015; and it was most often performed without foetal sex determination due to inaccuracy of the test in this regard. In addition, data on foetal malformations were not available in the dataset. Sonographers and foetal medicine doctors at both hospitals conducted the ultrasound examinations. Both departments used Voluson E8 Expert and Voluson 730 Expert ultrasound devices (GE Healthcare, Chicago, USA) with predominantly 2D and 3D/4D abdominal transducers. Data were registered in Excel and transferred and analysed in SPSS statistics version 21.0 (IBM Copenhagen, Denmark). Fisher’s exact test was used and p < 0.05 were considered statistically significant.

Trial registration: This study was approved by the Danish Data Protection Agency (record number: 2012-41-0050).

RESULTS

Practice of foetal sex determination

The phone interviews (Table 1) showed that all 23 departments conducted foetal sex determination at the second trimester anomaly scan. The scans were considered not mandatory, as there was no national guideline on foetal sex determination. All sonographers indicated that they only disclosed the foetal sex on parental request. Danish departments provided information about foetal sex determination to the pregnant couples predominantly orally (Table 1). Oral information was not standardised as to include the possibilities and limitations of the gender examination. The majority of the pregnant couples requested disclosure of the foetal sex. All sonographers expressed that their greatest focus was on conducting the anomaly scan according to second trimester national guidelines.

Overall, 70% of the departments registered the foetal sex from ultrasound in the second trimester in the Astraia database (Table 1). Ultrasound images as documentation of the foetal gender finding were obtained in 39% of departments. Quality requirements concerning standard views to determine foetal sex were present in 9% of the departments. For the remaining departments, technical details on ultrasound projections for correct foetal sex assessment were not written but trained by new staff during their apprenticeship. No departments conducted any postnatal quality assessment of the foetal sex determination.

Accuracy of foetal sex determination

Table 2 shows how foetal sex at each scan was categorised in the Astraia database. Foetuses with sex deter-

TABLE 1 / Structured phone interviews of random sonographers concerning the practice of foetal sex determination at 23 foetal medicine departments in Denmark.

	Departments, n (%)			total
	yes	no	not known	
<i>Foetal sex examination</i>				
Offered wk 20	23 (100)	0	0	23
Offered wk 12	0	20	3	23
<i>Examiner</i>				
Doctor	18 (78)	3	2	23
Sonographer	23 (100)	0	0	23
<i>Information</i>				
Oral	20 (87)	0	3	23
Written	7 (30)	12	4	23
Website	3 (13)	16	4	23
<i>Registration</i>				
Patient record/journal	3 (13)	20	0	23
Astraia database	16 (70)	4	3	23
Image documentation	9 (39)	12	2	23
Outcome registration	8 (35)	14	1	23
Quality criteria	2 (9)	21	0	23
Quality assessment	0	23	0	23

mination were categorised as either; “normal female”, “normal male” or “genital normal – sex not requested”. Foetuses with no sex determinations were categorised as either; “not examined”, “sex not possible to determine” or “empty box/not filled”. In total, foetal sex was determined in 86.7% of all second-trimester anomaly scans. The difference in obtained foetal sex determination between hospitals was highly significant, $p = 0.0002$ (Table 2). The reasons why foetuses did not have their sex determined in terms of inconclusive/ambiguous or malformed genitals were not possible to extract from the present data.

As shown in Table 3, the overall accuracy of foetal sex determination was 99.2%, and there was no significant difference between the rate recorded at the two hospitals. Furthermore, as demonstrated in Table 4, the accuracy of sex determination was significantly lower in females than in males.

A total of six sonographers and four foetal medicine doctors at the regional hospital and 20 sonographers and 14 foetal medicine doctors at the university hospital conducted the second-trimester anomaly scans described in this study. The level of experience of the members of staff was not registered.

DISCUSSION

This study has the strength of providing a national overview of the manner in which foetal sex determination was practiced in all Danish foetal medicine departments at the second-trimester anomaly scan. International knowledge on the practice of foetal sex determination is limited because previous studies have focused mainly on foetal sex determination on medical indication or on selected populations.

Foetal sex determination was performed in all Danish foetal medicine departments at the second-trimester anomaly scan. This finding is in line with a previous publication by Jylhä et al [18] showing that, in Finland, the majority of antenatal screening units (84%) undertook foetal sex determination at the second-trimester scan. However, as in Denmark, foetal sex determination was not mandatory, and guidelines were absent.

Evaluation in Denmark and Finland of the foetal genitalia was not systematic and this might imply a lack of professional security in determining the foetal sex and excluding genital malformations. The level of quality assessment in the present study and existing studies underpins the need for international guidelines on foetal sex determination. The sonographers and doctors can improve their professional abilities only through an initial focus on the basic requirements of sagittal, transverse and tangential views.

In Denmark and in Finland, foetal sex was disclosed only on parental request, and sonographers underlined

TABLE 2 / Comparison of foetal sex not determined by ultrasound examination in week 18 + 0 – 21 + 6, at a regional hospital and a university hospital.

	Ultrasound examination, n (%)		
	regional hospital (N _{reg} = 1,164)	university hospital (N _{uni} = 4,622)	total (N _{tot} = 5,786)
Foetal sex determined			
Genitals normal, male	463 (39.8)	1,808 (39.1)	2,271 (39.2)
Genitals normal, female	449 (38.5)	1,669 (36.1)	2,118 (36.6)
Genitals normal, sex not requested	135 (11.6)	493 (10.7)	628 (10.9)
Subtotal	1,047 (89.9)	3,970 (85.9)	5,017 (86.7)
Foetal sex not determined			
Genitals, not examined	30 (2.6)	167 (3.6)	197 (3.4)
Examined, sex not possible to determine	70 (6.0)	118 (2.6)	188 (3.3)
Empty box/not filled	17 (1.5)	367 (7.9)	384 (6.6)
Subtotal	117 (10.1)***	652 (14.1)***	769 (13.3)

***) $p = 0.0002$ (Fisher's exact test).

TABLE 3 / Comparison of the overall accuracy of foetal sex determined by ultrasound examination in week 18 + 0 – 21 + 6, at a regional hospital and a university hospital, $p = 1.000$ (Fisher's exact test).

	Foetal sex at birth, n (%)	
	regional hospital	university hospital
Correct determination	905 (99.2)	3,448 (99.2)
Incorrect determination	7 (0.8)	29 (0.8)
Total	912	3,477

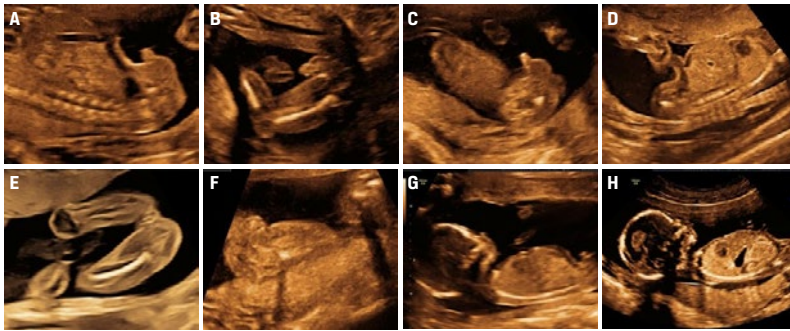
TABLE 4 / Accuracy in the prediction of female and male sex at week 18 + 0 – 21 + 6. Comparison of determination of foetal sex by ultrasound examination with sex at birth, $p < 0.0001$ (Fisher's exact test).

Foetal sex at birth	Determination by ultrasound examination, n (%)	
	female	male
Female	2,100 (99.2)	18 (0.8)
Male	18 (0.9)	2,253 (99.2)
Total	2,118 (100)	2,271 (100)

that foetal sex determination seemed important to the majority of the pregnant couples [2, 6, 16, 18]. The parental curiosity about the sex of their future child is universal, but it seems that most existing guidelines focus on ethical restrictions in the disclosure of the foetal sex, some even with disclaimers, instead of including recommendations on how to perform the ultrasound examination. Ethical issues and gender-specific preferences may play a role in parental choices according to ethnicity, parity and age. However, correct sex determination should be the first step towards a more detailed and strengthened examination of foetal genitals.

Foetal sex determination by ultrasound-required views. Direct visualisation of foetal genitals in second and third trimester (A-F) with sagittal view as mandatory supplemented by transverse and/or tangential view. Preferably all three views. A. Male foetus in week 20 in sagittal view. B. Transverse view. C. Tangential view. D. Female foetus in week 20 in sagittal view. E. Transverse view. F. Tangential view. G. Sagittal sign of foetal genitals in the late first and early second trimester (G-H). G. Male foetus in week 15 with genital tubercle in cranial angle $> 30^\circ$. H. Female foetus in week 15 with genital tubercle in caudal angle $< 30^\circ$.

Printed with the permission of John Wiley and Sons: Størup G. Fetal sex determination during ultrasonography: should we focus on how rather than why? *Acta Obstet Gynecol Scand* 2019;98:1483-4.



To our knowledge, the most recent study of second-trimester sex determination from 2009 included 2,780 unselected patients [6]. The strength of this study is the large number of included patients from an unselected population; and the results of 5,786 anomaly scans with 86.7% of cases accessed is comparable to previous studies including rates of foetal sex determination at an equivalent gestational week of 89.4-98.2% [2, 6]. Previous studies have shown that improper foetal position or high maternal BMI influence the possibility of obtaining sufficient images and thereby the accuracy of foetal sex determination [15, 16, 19]. However, such data were not available in this study. The significant difference between the regional and the university hospital in obtaining foetal sex determination may reflect differences in coding practice, as registration of sex determination was retrospective and covered a period without national recommendations or guidelines.

The 99.2% accuracy of foetal sex determination is comparable with previously published second-trimester scans, being in the range of 96.7-99.4% [2, 6]. The accuracy, however, still leaves 8/1,000 fetuses with an incorrectly assigned gender. Carefully extrapolating this finding to a Danish birth cohort from 2017 ($n = 61,397$), approximately 425 fetuses would have an incorrect sex assigned. These couples are accordingly at risk of unnecessary psychological stress and confusion [17]. If foetal sex determination is performed, it should be standardised and at a high level to avoid false diagnoses.

A limitation is that fetuses with genetic examination and thereby foetal sex determined were not excluded from this study. Accordingly, we may have over-

estimated the accuracy of sex determination in the study population. However, in the Danish population, the number of fetuses with genetic testing is below 5%, and it therefore seems likely that our conclusions are reliable.

Ambiguous or malformed genitals are of great importance in prenatal examination as shown by Pajkrt et al [14] and taking into consideration also the Swedish study presenting a prevalence of minor structural genital malformations at 3.8/1,000 and major malformations at 0.7/1,000 [15]. Unfortunately, data on genital malformations were not available in this dataset, and an evaluation of the detection of genital malformations therefore cannot be performed, which is a limitation of this study. In future research, it is highly recommended to focus on the detection of genital malformations as well as on the group of fetuses who did not have their sex determined. As shown by Stocker and Evens [1], determining the female sex was significantly more difficult than determining the male sex ($p < 0.001$). Subsequent studies have shown either no significant difference in female versus male sex determination or even superior results in females, but study populations vary according to gestational age at the scan and sample sizes ranging from 353 to 2,780 scans [2, 6]. Thus, the present Danish study contributes with new data on the significant difficulty associated with determining females in a large number of second-trimester anomaly scans.

CONCLUSIONS

This study demonstrated that the practice of foetal sex determination in Denmark was characterised by varying approaches and no quality assessment at the second-trimester anomaly scan. Incorrect sex was determined in eight out of 1,000 fetuses, primarily females. Consequently, better detection rates are needed. Examination of the foetal genitals should be considered mandatory at the second-trimester anomaly scan in line with the examination of other foetal organs. Although detection of malformed or ambiguous genitals was not an aim of this study, the topic is highly relevant, and guidelines are requested. Following this work, a national guideline on foetal sex determination was developed by the Danish Foetal Medicine Society [20] and accordingly listed by the Nordic Federation of Obstetrics and Gynaecology. Foetal sex determination including sagittal, transverse and tangential projections, is now recommended as an integral part of the Danish second-trimester anomaly scan.

CORRESPONDENCE: Gitte Størup. E-mail: birgitte.stoerup@rn.dk

ACCEPTED: 14 October 2019

CONFLICTS OF INTEREST: none. Disclosure forms provided by the authors are available with the full text of this article at Ugeskriftet.dk/dmj

LITERATURE

1. Stocker J, Evens L. Fetal sex determination by ultrasound. *Obstet Gynecol US* 1977;50:462-6.
2. Harrington K, Armstrong V, Freeman J et al. Fetal sexing by ultrasound in the second trimester: maternal preference and professional ability. *Ultrasound Obstet Gynecol* 1996;8:318-21.
3. Emerson DS, Felker RE, Brown DL. The sagittal sign. An early second trimester sonographic indicator of fetal gender. *J Ultrasound Med* 1989;8:293-7.
4. Efrat Z, Akinfenwa OO, Nicolaides KH. First-trimester determination of fetal gender by ultrasound. *Ultrasound Obstet Gynecol* 1999;13:305-7.
5. Odeh M, Granin V, Kais M et al. Sonographic fetal sex determination. *Obstet Gynecol Surv US* 2009;64:50-7.
6. Ralph K, Polson D. A woman's decision to know the sex of her child prior to birth. *Ultrasound* 2012;20:161-4.
7. Pajkrt E, Chitty LS. Prenatal gender determination and the diagnosis of genital anomalies. *BJU Int* 2004;93(suppl 3):12-9.
8. Chitayat D, Glanc P. Diagnostic approach in prenatally detected genital abnormalities. *Ultrasound Obstet Gynecol* 2010;35:637-46.
9. Salomon LJ, Alfirevic Z, Berghella V et al. Practice guidelines for performance of the routine mid-trimester fetal ultrasound scan. *Ultrasound Obstet Gynecol* 2011;37:116-26.
10. AIUM practice guideline for the performance of obstetric ultrasound examinations. *J Ultrasound Med* 2013;32:1083-101.
11. Cargill Y, Morin L. Content of a complete routine second trimester obstetrical ultrasound examination and report. *J Obstet Gynaecol Can* 2009;31:272-5.
12. Chitty LS, Neilson JP, Shirley IM et al. Ultrasound screening. Supplement to ultrasound screening for fetal abnormalities. London: Royal College of Obstetricians and Gynecologists, 2000.
13. Policies and statements. Guidelines for the mid trimester obstetric scan. Australasian Society for Ultrasound in Medicine, 2014. www.asum.com.au/files/public/SoP/D2-Guidelines-for-the-Mid-Trimester-Obstetric-Scan.pdf (20 Jun 2019).
14. Pajkrt E, Petersen OB, Chitty LS. Fetal genital anomalies: an aid to diagnosis. *Prenat Diagn* 2008;28:389-98.
15. Romosan G, Henriksson E, Rylander A et al. Diagnostic performance of routine ultrasound screening for fetal abnormalities in an unselected Swedish population in 2000-2005. *Ultrasound Obstet Gynecol* 2009;34:526-33.
16. Larsson M, Berglund M, Jarl E et al. Do pregnant women want to know the sex of the expected child at routine ultrasound and are they interested in sex selection? *Ups J Med Sci* 2017;122:254-9.
17. Chigbu CO, Odugu B, Okezie O. Implications of incorrect determination of fetal sex by ultrasound. *Int J Gynaecol Obstet* 2008;100:287-90.
18. Jylha ME, Kirkinen PP, Puura KL et al. Fetal sex determination: obstetricians' attitudes in antenatal screening units in Finland. *Scand J Pub Health* 2010;38:756-60.
19. Behrendt N, Foy P, Center J et al. Influence of maternal body mass index and gestational age on accuracy of first trimester gender assignment. *J Matern Fetal Neonatal Med* 2012;25:253-6.
20. Størup G, Andreassen R, Andresen L et al. Kønsbestemmelse af fostre ved ultralyd dfms.dk. 2015:1-25. www.dfms.dk/images/Guidelines/Koensbestemmelse_af_fostre_ved_ultralydsscanning_Final_version_23-1-2015_15-9-2015.pdf (20 Jun 2019).