

A case report of tardive subcutaneous emphysema in relation to iatrogenic pneumothorax

Ringvold, Christine Helene Opedal; Weinreich, Ulla Moller

Published in:
Sage Open Medical Case Reports

DOI (link to publication from Publisher):
[10.1177/2050313X19870970](https://doi.org/10.1177/2050313X19870970)

Creative Commons License
CC BY-NC 4.0

Publication date:
2019

Document Version
Publisher's PDF, also known as Version of record

[Link to publication from Aalborg University](#)

Citation for published version (APA):
Ringvold, C. H. O., & Weinreich, U. M. (2019). A case report of tardive subcutaneous emphysema in relation to iatrogenic pneumothorax. *Sage Open Medical Case Reports*, 7, Article 2050313X19870970.
<https://doi.org/10.1177/2050313X19870970>

General rights

Copyright and moral rights for the publications made accessible in the public portal are retained by the authors and/or other copyright owners and it is a condition of accessing publications that users recognise and abide by the legal requirements associated with these rights.

- Users may download and print one copy of any publication from the public portal for the purpose of private study or research.
- You may not further distribute the material or use it for any profit-making activity or commercial gain
- You may freely distribute the URL identifying the publication in the public portal -

Take down policy

If you believe that this document breaches copyright please contact us at vbn@aub.aau.dk providing details, and we will remove access to the work immediately and investigate your claim.

A case report of tardive subcutaneous emphysema in relation to iatrogenic pneumothorax

SAGE Open Medical Case Reports
Volume 7: 1–3
© The Author(s) 2019
Article reuse guidelines:
sagepub.com/journals-permissions
DOI: 10.1177/2050313X19870970
journals.sagepub.com/home/sco



Christine Helene Opedal Ringvold^{1,2} and Ulla Møller Weinreich^{2,3,4}

Abstract

Subcutaneous emphysema, the presence of air under the subcutaneous tissues, often arises in relation to pneumothorax, including iatrogenic pneumothorax. It can arise as a consequence of chest drain insertion and removal. This case report describes worsening of subcutaneous emphysema subsequent to chest drain removal, leading to tardive and life-threatening subcutaneous emphysema. There are few international guidelines describing chest drain removal and there are few reports describing tardive subcutaneous emphysema. These areas need further exploration using evidence-based research in order to develop a consensus on treatment options.

Keywords

Subcutaneous emphysema, pleural drainage

Date received: 29 October 2018; accepted: 23 July 2019

Introduction

Subcutaneous emphysema (SE) is caused by air entering the subcutaneous tissues. SE often arises as a result of pneumothorax, but it can also arise in relation to the transthoracic drainage of a pneumothorax, especially due to poor tube placement, anchorage, blockage, and with side-port migration into the subcutaneous tissue.¹ There are a number of reports describing the development of SE in relation to drain insertion,^{1–3} but few in relation to drain removal.⁴

The British Thoracic Society has guidelines describing chest drain insertion;⁵ however, many respiratory societies, including the American Thoracic Society, British Thoracic Society and the European Respiratory Society, do not have guidelines for chest drain removal. Guidelines for chest drain removal exist on UpToDate⁶ as well as for some local hospitals.⁷

The development of SE in relation to the transthoracic drainage of a pneumothorax can be immediate³ or rapid, arising within hours;⁸ however, this case report describes the tardive development of massive SE.

Case report

A 74-year-old woman, known with severe chronic obstructive pulmonary disease (COPD), was admitted in order to

carry out chest drainage of an iatrogenic pneumothorax, consequent to a computed tomography (CT)-guided biopsy of a tumor-suspect pulmonary lesion. The patient subsequently developed SE and was therefore treated with applying suction to the chest drain at 10 cm H₂O for a duration of 5 days.

Due to regression of SE, the absence of bubbling and oscillations in the water seal chamber as well as no signs of pneumothorax as shown on a chest x-ray (Figure 1), the chest drain was clamped and after a 3-h observation it was removed.

Five hours later, while coughing, the patient developed massive SE, involving the whole body as well as pneumomediastinum (Figure 2(a) and (b)), with dyspnea, pain, changes in the pitch of her voice and loss of vision. The patient was intubated and the lesion from the previous

¹Department of Psychiatry, Ringerike Hospital, Ringerike, Norway

²Department of Respiratory Diseases, Aalborg University Hospital, Aalborg, Denmark

³The Respiratory Research Unit, Aalborg University Hospital, Aalborg, Denmark

⁴The Clinical Institute, Aalborg University, Aalborg, Denmark

Corresponding Author:

Christine Helene Opedal Ringvold, Department of Psychiatry, Ringerike Hospital, 3511 Ringerike, Norway.
Email: christineringsvold@gmail.com



drain application was opened, resulting in immediate relief of the SE.

Discussion

Previously, only a few articles have described the tardive development of SE. Tardive SE has for instance been described in relation to abdominal surgical procedures where SE arose after the termination of induced pneumoperitoneum,^{9,10} up to days after the procedure. This is different to our case, as this relates to the abdominal cavity.

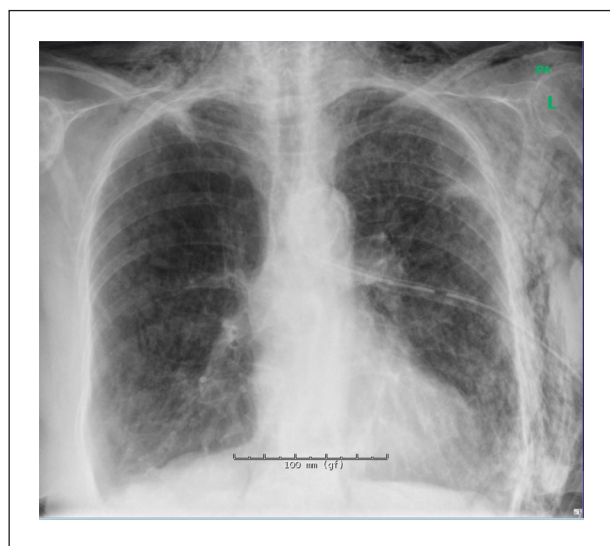

Figure 1. Chest x-ray taken prior to chest drain removal, showing no obvious signs of pneumothorax. SE can be seen, especially on the left side of the thorax and bilaterally in the nuchal area.

The prevalence of life-threatening or fatal SE is not known, but has previously been described.^{11–14}

As SE can be a consequence of chest drain insertion and removal, it is important that these procedures are carried out correctly. As the availability of guidelines for chest drain removal is limited, evidence-based guidelines should be sought for. This case report suggests that a consequence of not maintaining chest drainage until the complete absence of SE, both clinically and confirmed on a chest x-ray, might be the development of sudden and massive worsening of SE subsequent to chest drain removal. In this case report, the SE was in regression but had not completely resolved before removal of the drain.

According to available guidelines,^{6,7} the criteria for removing chest drain after a pneumothorax include taking a chest x-ray to demonstrate the lung being fully expanded, the absence of a visible air leak (cessation of bubbling and oscillation) and for no air to accumulate when suction is removed. Some clinicians clamp the chest drain, in order to identify intermittent air leaks that would not otherwise be detected; however, clamping is not universal practice as it is not always deemed as necessary. In the case of chest drainage due to a pulmonary effusion or empyema, the drain can usually be removed when daily fluid output is under 100–300 mL in the last 24 h. The threshold for removal should however be individualized depending on indication for the chest drain as well as on patient factors, such as body mass. There may be pockets of fluid remaining if the patient is clinically well, as long as antibiotic treatment is maintained as the fluid is likely to resolve without further drainage.

Conclusion

In this case report, a patient experienced an iatrogenic pneumothorax and SE subsequent to a pulmonary CT-guided

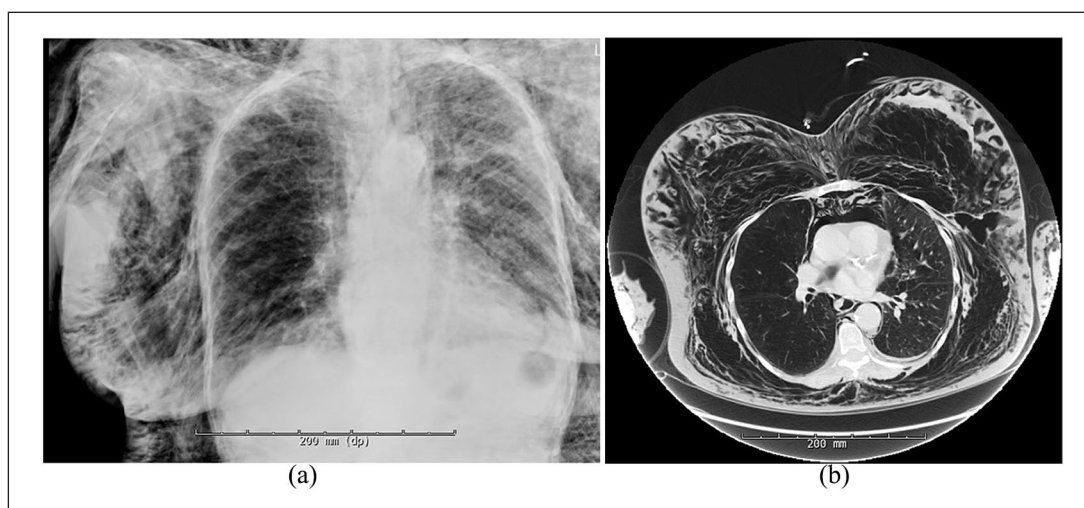


Figure 2. (a) Chest x-ray taken immediately prior to intubation, showing massive SE, and (b) a section of the CT-thorax scan taken immediately prior to intubation, demonstrating SE and pneumomediastinum. The CT scan also showed a pulmonary lesion apically and laterally in the superior pulmonary lobe.

biopsy. After a few days of chest drainage the SE had regressed and there were no longer signs of pneumothorax, and therefore the drain was removed. Several hours after removal, the SE worsened massively and suddenly, leading to life-threatening dyspnea and the need for intubation and a new chest drain. The patient's symptoms resolved, and she was later discharged.

This case report suggests that a consequence of not maintaining chest drainage until the complete absence of SE, both clinically and confirmed on a chest x-ray, might be the development of sudden and massive worsening of SE subsequent to chest drain removal. In this case report, the SE was in regression, especially clinically, but had not completely resolved before removal of the drain, as shown on a chest x-ray. A recommended precaution to avoid this complication may therefore be confirming the absence of SE on a chest radiograph before drain removal.

It is both rare for SE to develop as late and as extensively as described in this case report. More case reports on tardive and massive SE could aid in the exploration of ideal management options.

This case also illustrates the importance of availability of guidelines for chest drain removal, as they are currently limited.

Acknowledgements

We sincerely thank our patient for the permission to write this case report.

Declaration of conflicting interests

The author(s) declared no potential conflicts of interest with respect to the research, authorship, and/or publication of this article.

Ethical approval

Our institution does not require ethical approval for reporting individual cases or case series.

Funding

The author(s) received no financial support for the research, authorship, and/or publication of this article.

Informed consent

Written informed consent was obtained from the patient(s) for their anonymized information to be published in this article. The patient has given informed consent to have the case report described for publication.

ORCID iD

Christine Helene Opedal Ringvold  <https://orcid.org/0000-0001-5579-6841>

References

1. Jones P, Hewer R, Wolfenden H, et al. Subcutaneous emphysema associated with chest tube drainage. *Respirology* 2001; 6(2): 87–89.
2. Tran Q, Mizumoto R and Mehanna D. Management of extensive surgical emphysema with subcutaneous drain: a case report. *Int J Surg Case Rep* 2018; 44: 126–130.
3. Low L and Adams N. Managing iatrogenic subcutaneous emphysema on a background of COPD while treating persistent secondary pneumothorax. *BMJ Case Rep* 2010; 2010: bcr0920092283.
4. Williams D, Jaggar S and Morgan C. Upper airway obstruction as a result of massive subcutaneous emphysema following accidental removal of an intercostal drain. *Br J Anaesth* 2005; 94(3): 390–392.
5. Maskell N. British Thoracic Society pleural disease guidelines – 2010 update. *Thorax* 2010; 65(8): 667–669.
6. UpToDate, 2018, <https://www.uptodate.com/contents/place-ment-and-management-of-thoracostomy-tubes#!> (accessed 24 October 2018).
7. Pleural Drains in Adults—Agency for Clinical Innovation, 2018, <https://www.aci.health.nsw.gov.au/resources/respiratory/pleural-drains/pleural-drains-in-adults> (accessed 24 October 2018).
8. O'Reilly P, Chen H and Wiseman R. Management of extensive subcutaneous emphysema with a subcutaneous drain. *Respirol Case Rep* 2013; 1(2): 28–30.
9. Santana A, Crausman R and Dubin H. Late onset of subcutaneous emphysema and hypercarbia following laparoscopic cholecystectomy. *Chest* 1999; 115(5): 1468–1471.
10. Jones A, Pisano U, Elsobky S, et al. Grossly delayed massive subcutaneous emphysema following laparoscopic left hemicolectomy: a case report. *Int J Surg Case Rep* 2015; 6: 277–279.
11. Dumont S and Farag A. Life threatening subcutaneous emphysema. *Anaesthesia* 2008; 63(2): 212–213.
12. Tumram N, Bardale R, Dixit P, et al. Fatal subcutaneous emphysema by manja: a deadly string. *BMJ Case Rep* 2013; 2013: bcr2012007727.
13. Neuhäuser C, Kroll T, Wolf G, et al. Life-threatening subcutaneous emphysema after minor blow to the neck. *Anaesthesist* 2019; 68(2): 104–107.
14. Raut M, Dubey S, Shivnani G, et al. Massive subcutaneous emphysema after off-pump coronary bypass surgery. *Ann Card Anaesth* 2019; 22(1): 97–98.