

**Thrombocytopenia with acute ischemic stroke and bleeding in a patient newly vaccinated with an adenoviral vector-based COVID-19 vaccine**

Blauenfeldt, Rolf Ankerlund; Kristensen, Søren Risom; Ernstsén, Siw Leiknes; Kristensen, Claudia Christina Hilt; Simonsen, Claus Ziegler; Hvas, Anne Mette

*Published in:*  
Journal of Thrombosis and Haemostasis

*DOI (link to publication from Publisher):*  
[10.1111/jth.15347](https://doi.org/10.1111/jth.15347)

*Publication date:*  
2021

*Document Version*  
Accepted author manuscript, peer reviewed version

[Link to publication from Aalborg University](#)

*Citation for published version (APA):*  
Blauenfeldt, R. A., Kristensen, S. R., Ernstsén, S. L., Kristensen, C. C. H., Simonsen, C. Z., & Hvas, A. M. (2021). Thrombocytopenia with acute ischemic stroke and bleeding in a patient newly vaccinated with an adenoviral vector-based COVID-19 vaccine. *Journal of Thrombosis and Haemostasis*, 19(7), 1771-1775. <https://doi.org/10.1111/jth.15347>

**General rights**

Copyright and moral rights for the publications made accessible in the public portal are retained by the authors and/or other copyright owners and it is a condition of accessing publications that users recognise and abide by the legal requirements associated with these rights.

- Users may download and print one copy of any publication from the public portal for the purpose of private study or research.
- You may not further distribute the material or use it for any profit-making activity or commercial gain
- You may freely distribute the URL identifying the publication in the public portal -

**Take down policy**

If you believe that this document breaches copyright please contact us at [vbn@aub.aau.dk](mailto:vbn@aub.aau.dk) providing details, and we will remove access to the work immediately and investigate your claim.



DR ROLF ANKERLUND BLAUENFELDT (Orcid ID : 0000-0002-4846-9516)

PROF. SØREN RISOM KRISTENSEN (Orcid ID : 0000-0002-2649-506X)

Article type : Case Report

**Title:** Thrombocytopenia with acute ischemic stroke and bleeding in a patient newly vaccinated with an adenoviral vector-based COVID-19 vaccine

**Short title:** Thrombocytopenia and stroke after COVID-19 vaccine

**Authors:** Rolf Ankerlund Blauenfeldt MD\*†, Søren Risom Kristensen DMSc ‡§, Siw Leiknes Ernsten MD¶, Claudia Christina Hilt Kristensen MD\*§, Claus Ziegler Simonsen MD†\*\*, Anne-Mette Hvas MD†††.

\*Department of Neurology, Aalborg University Hospital, Aalborg, Denmark

†Department of Clinical Medicine, Aarhus University, Aarhus, Denmark

‡Department of Clinical Biochemistry, Aalborg University Hospital, Aalborg, Denmark

§Department of Clinical Medicine, Aalborg University, Aalborg, Denmark

¶Norwegian National Unit of platelet immunology, University Hospital of North Norway, Tromsø, Norway

\*\*Department of Neurology & Danish Stroke Center, Aarhus University Hospital, Aarhus, Denmark

††Department of Clinical Biochemistry, Aarhus University Hospital, Aarhus, Denmark

## Tables: 1

This article has been accepted for publication and undergone full peer review but has not been through the copyediting, typesetting, pagination and proofreading process, which may lead to differences between this version and the [Version of Record](#). Please cite this article as [doi: 10.1111/JTH.15347](https://doi.org/10.1111/JTH.15347)

This article is protected by copyright. All rights reserved

**Online supplement figures: 1**

**Word count main manuscript: 1239**

**Contact:**

Rolf Ankerlund Blauenfeldt

Department of Neurology,

Aalborg University Hospital,

DK-9000, Aalborg, Denmark

e-mail: rolfbrau@rm.dk

phone: 0045 61368874

**Essentials:**

We describe the first-ever case of presumed immune mediated thrombocytopenia, hemorrhage and ischemic stroke after vaccination with an adenoviral (ChAdOx1) vector based COVID-19 vaccine (AZD1222).

Thrombocytopenia with thrombosis and bleeding may be a novel immune mediated response to an adenoviral vector based COVID-19 vaccine, resembling heparin induced thrombocytopenia (HIT). The presence of platelet factor 4 antibodies was confirmed.

**Abstract:**

We describe the first Danish case of presumed inflammatory and thrombotic response to vaccination with an adenoviral (ChAdOx1) vector based COVID-19 vaccine (AZD1222). The case describes a 60-year old woman, who was admitted with intractable abdominal pain seven days after receiving the vaccine. Computer Tomography (CT) of the abdomen revealed bilateral adrenal hemorrhages. On the following day she developed a massive right sided ischemic stroke and Magnetic Resonance Imaging (MRI) angiography showed occlusion of the right internal

carotid artery. The ischemic area was deemed too large to offer reperfusion therapy. During admission, blood tests showed a remarkable drop in platelet counts from 118,000 to 5,000 per  $\mu\text{L}$  and a substantial increase in D-dimer. The patient died on the 6<sup>th</sup> day of hospitalization. Blood test revealed platelet factor 4 (PF-4) reactive antibodies, imitating what is seen in heparin-induced thrombocytopenia. This may be a novel immune mediated response to the vaccine.

**Keywords:**

Thrombocytopenia, Stroke, Vaccines, Platelet Factor, Hemorrhage

**Introduction**

The COVID-19 infection has caused increased morbidity and mortality world-wide. To meet this extraordinary challenge, new vaccines have been developed with a speed that have never been seen before in medical history[1–4]. The safe implementation of these vaccines is of major importance to avoid more deaths due to COVID-19 and for the restoration of normal social life. There have been media reports and a preliminary research report (*Greinacher A., et al, Research square. April 7, 2021*) of unusual thrombotic and/or hemorrhagic events following the ChAdOx1 nCoV-19 vaccine, and the possibility of specific immune mediated thrombocytopenia have been raised by Austrian and Norwegian researchers[5,6].

Here, we describe the first Danish case, where a 60-year old woman developed bilateral adrenal hemorrhages and a massive ischemic stroke, while laboratory results revealed a rapid decline in platelet counts and substantial increase in D-dimer. The patient was later found positive for platelet factor-4 (PF-4) antibodies.

**Case report**

Denmark began vaccinating against the COVID-19 infection with the mRNA-based vaccine BNT162b2 (Pfizer/Biontech) at the 27<sup>th</sup> of December 2020. This was later followed by the mRNA-1273 vaccine from Moderna. The AZD1222 (AstraZeneca) vaccine was approved by the European Medicines Agency and vaccination was commenced on 5<sup>th</sup> of February 2021 in Denmark.

The present case describes a 60-year old woman who had a past medical history significant of Hashimoto's thyroiditis and hypertension. She was on losartan 50 mg daily, simvastatin 40 mg and

levothyroxine 50/100 µg on alternating days. She received the first dose of vaccine (AZD1222) and had, according to relatives, a light headache the following days.

The patient was admitted on the 7<sup>th</sup> post-vaccination day with strong, persistent abdominal pain. Urine analysis was positive for blood. A Computer Tomography (CT) scan of the abdomen was performed, showing bilateral adrenal hemorrhages and a subcapsular renal hematoma.

On the second day of admission, she was last seen well in the afternoon and found one hour later with left-sided weakness and eye deviation to the right. A Magnetic Resonance Imaging (MRI) scan performed two hours after last seen well showed diffusion restriction and hence completed infarction in the entire area supplied by the right middle cerebral artery (*Online supplement Figure 1*). Due to the size of the infarct, it was deemed that reperfusion therapy could not be offered. A CT-scan of the aorta excluded dissection. Treatment by hydrocortisone 100 mg three times daily as substitution therapy and cefuroxime was initiated. Platelet inhibitor treatment was deferred due to the possibility of malignant media infarction with subsequent surgery.

On the 3<sup>rd</sup> hospital day, Glasgow Coma Scale dropped from 12 to 5. CT of the cerebrum showed a malignant media infarction with a midline shift of 12 mm (*Online supplement Figure 1*).

Blood tests as seen on *Table 1* showed a drop in platelet counts and the patient received 3 pools of platelet concentrates before hemicraniectomy. During the admission, she received a total of 7 pools of platelet concentrates. Hemicraniectomy was performed, but the patient did not regain consciousness. Post-operative dalteparin 5000 IU daily was started. On the 4<sup>th</sup> hospital day, the 1.-3. fingers of the left hand were discolored dark/blue. The skin of the left foot was mottled with decreased capillary response. Follow up CT scan of the cerebrum showed edema of the right hemisphere and no new ischemic or hemorrhagic lesions but an unresolved midline shift. The patient was transferred to palliative care, in agreement with the family, and died on the 6<sup>th</sup> hospital day.

## Discussion

A vaccine activates the immune system and unwanted side effects are often seen. Common side effects may include pain at the injection site, headache, muscle and joint pain and general feeling of being unwell. Rarely, autoimmune diseases may be elicited like Guillain-Barré syndrome[7].

Anaphylactic shock with vasodilation and hypotension is the most feared side effect and rapid identification and treatment can be life-saving.

The syndrome suffered by the patient in this case, has to our knowledge not previous been described in the medical literature as a potential post-vaccination reaction. It is a highly unique and a rarely seen reaction with a temporal relation to vaccination. Therefore, an association between vaccination and the clinical syndrome is suspected.

Several differential diagnoses were considered. Infectious and non-infectious endocarditis was unlikely, given normal blood cultures and a normal trans-thoracic echocardiography. Septicemia and in particular Waterhouse-Friedrichsen syndrome with adrenal hemorrhages caused by meningococcal disease was also unlikely, given normal blood culture and negative *neisseria meningitidis* antibody. Aortic dissection was ruled out by a CT of the aorta. Thrombotic thrombocytopenic purpura was ruled out by a normal blood smear and a normal ADAMTS-13 (a disintegrin and metalloproteinase with a thrombospondin type 1 motif, member 13). Catastrophic antiphospholipid syndrome was considered, but tests for lupus anticoagulant, and beta2-glycoprotein1 and cardiolipin antibodies were all negative. The picture could resemble disseminated intravascular coagulation, but the biochemical panel was not compatible with this since changes in activated partial thromboplastin time (APTT), fibrinogen and antithrombin were unremarkable.

The clinical picture mirrors what is seen in heparin-induced thrombocytopenia (HIT). However, the patient had not received heparin during her admission. She had received dalteparin, but this was administered on the 3<sup>rd</sup> hospital day and after the onset of stroke and thrombocytopenia.

Blood samples were sent to the Norwegian National Unit of platelet immunology, at the University Hospital of North-Norway, Tromsø, Norway. Here, anti-PF-4 IgG antibodies were detected with high optical density PF-4/polyvinylsulfonate complex enzyme-linked immunosorbent assay (ELISA). PF-4 antibodies may be found positive randomly [8], but suspicion of a causative link was heightened as serum from the patient also caused platelet aggregation of donor platelets in heparin-induced multiple electrode aggregometry (HIMEA).

Antibodies against PF-4 are typically seen in HIT. HIT is a complication of heparin treatment, where heparin binds to PF-4 which are present in platelet granules[9]. PF-4 is part of the immunological system and can bind to e.g. bacteria and by that contribute to removal of these.

During treatment with heparin the positively charged PF-4 can bind to the negatively charged heparin and this complex may in some patients induce formation of antibodies against PF-4/heparin complexes. The heparin/PF-4/antibody immune complex activates platelets by interacting with FcγRIIa on the platelet surface. This leads to release of procoagulant factors, extensive clot formation in both veins and arteries and at the same time platelet degradation[10,11].

HIT is a devastating syndrome often emerging 5-10 days after initiation of heparin therapy with a high morbidity and mortality. The PF-4 antibodies can persist for months, but the present patient had not been exposed to unfractionated heparin or low-molecular weight heparin previously.

During the past decade it has been described that some patients may develop autoimmune HIT without having received heparin, and thus, other factors are able to induce the formation of these antibodies leading to HIT[9]. Interestingly, HIT has recently been identified in a high proportion of hospitalized patients with severe COVID-19 exposed to heparins[12]. Early identification and shift of anticoagulant treatment from heparins to direct thrombin inhibitors is the mainstay of HIT treatment, but treatment with immunoglobulins (IVIg) may have a role as well[9].

## **Conclusion**

We present a case of thrombocytopenia, hemorrhage and ischemic stroke after vaccination with an adenoviral vector-based vaccine. The clinical picture resembles HIT and the presence of IgG PF-4 antibodies was confirmed. Awareness of this possible immune reaction is important for clinicians worldwide to ensure rapid identification, diagnostics and treatment. Larger investigations are warranted to confirm these findings and to improve understanding of the pathophysiology.

## **Disclosures**

Dr. Blauenfeldt reports grants from National Institute of Health, grants from TrygFonden and speaker's fee from Bayer, outside the submitted work; Dr. Simonsen reports grants from Novo Nordisk Foundation, grants from Health Research Foundation of Central Denmark Region, outside the submitted work; Dr. Hvas reports grants from CSL Behring, and speaker's fee: from CSL Behring, Boehringer-Ingelheim, Bayer, Astellas, outside the submitted work; Dr. Ernstsen, Dr. Hilt Kristensen and Dr. Kristensen have nothing to disclose.

## **Author contributions**



Authors AH, SRK, SE, CP and RB were involved in the clinical problem-solving process.

Literature review were performed by AH, SRK, SE and RB. Biochemical analysis was performed and interpreted by SE. First draft was made by CZ and RB. All authors have critically revised the manuscript and approved the final version.

## References

1. Polack FP, Thomas SJ, Kitchin N, Absalon J, Gurtman A, Lockhart S, Perez J, Pérez Marc G, Moreira E, Zerbini C, Bailey R, Swanson K, Roychoudhury S, Koury K, Li P, Kalina W, Cooper D, Renck R, Hammitt L, Türeci Ö, et al. Safety and Efficacy of the BNT162b2 mRNA Covid-19 Vaccine. *N Engl J Med* 2020;383:2603–2615.
2. Baden L, El Sahly H, Essink B, Kotloff K, Frey S, Novak R, Diemert D, Spector S, Rouphael N, Creech C, McGettigan J, Khetan S, Segall N, Solis J, Brosz A, Fierro C, Schwartz H, Neuzil K, Corey L, Gilbert P, et al. Efficacy and Safety of the mRNA-1273 SARS-CoV-2 Vaccine. *N Engl J Med* 2021;384:403–16.
3. Ramasamy M, Minassian A, Ewer K, Flaxman A, Folegatti P, Owens D, Voysey M, Aley P, Angus B, Babbage G, Belij-Rammerstorfer S, Berry L, Bibi S, Bittaye M, Cathie K, Chappell H, Charlton S, Cicconi P, Clutterbuck E, Colin-Jones R, et al. Safety and immunogenicity of ChAdOx1 nCoV-19 vaccine administered in a prime-boost regimen in young and old adults (COV002): a single-blind, randomised, controlled, phase 2/3 trial. *Lancet* 2020;396:1979–93.
4. Voysey M, Clemens S, Madhi S, Weckx L, Folegatti P, Aley P, Angus B, Baillie V, Barnabas S, Bhorat Q, Bibi S, Briner C, Cicconi P, Collins A, Colin-Jones R, Cutland C, Darton T, Dheda K, Duncan C, Emary K, et al. Safety and efficacy of the ChAdOx1 nCoV-19 vaccine (AZD1222) against SARS-CoV-2: an interim analysis of four randomised controlled trials in Brazil, South Africa, and the UK. *Lancet* 2021;397:99–111.
5. Sciencenorway.no. Norwegian doctors are investigating if blood clots could be linked to the AstraZeneca-vaccine. March 16, 2021; Available from: <https://sciencenorway.no/covid19-vaccines/norwegian-doctors-are-investigating-if-blood-clots-could-be-linked-to-the-astrazeneca-vaccine-heres-what-theyre-looking-for/1829070>
6. Informationsdienst Wissenschaft. Researchers from Greifswald Germany report

breakthrough in SARS-CoV2 vaccination related thrombotic complications. March 21, 2021; Available from: <https://idw-online.de/en/news765335>

7. Haber P, DeStefano F, Angulo F, Iskander J, Shadomy S, Weintraub E, Chen R. Guillain-Barré syndrome following influenza vaccination. *J Am Med Assoc* 2004;292:2478–81.
8. Warkentin TE, Sheppard J. Testing for Heparin-Induced Thrombocytopenia Antibodies. *Transfus Med Rev* 2006;20:259–72.
9. Greinacher A, Selleng K, Warkentin TE. Autoimmune heparin-induced thrombocytopenia. *J Thromb Haemost* 2017;15:2099–114.
10. Jaax ME, Greinacher A. Management of heparin-induced thrombocytopenia. *Expert Opin. Pharmacother.* 2012;13:987–1006.
11. Perdomo J, Leung H, Ahmadi Z, Yan F, Chong J, Passam F, Chong B. Neutrophil activation and NETosis are the major drivers of thrombosis in heparin-induced thrombocytopenia. *Nat Commun* 2019;10.
12. Daviet F, Guervilly C, Baldesi O, Bernard-Guervilly F, Pilarczyk E, Genin A, Lefebvre L, Forel J, Papazian L, Camoin-Jau L. Heparin-induced thrombocytopenia in severe COVID-19. *Circulation.* 2020;142:1875–7.

### Addendum

After writing this case report, two papers have been published. The condition has been coined vaccine-induced immune thrombotic thrombocytopenia (VITT) (Schultz NH., et al. and Greinacher A., et. al.) We note that the thromboses in the published papers were mainly venous thromboses. This case demonstrates that a primary arterial thrombosis also may be a complication.

Schultz NH, Sørvoll IH, Michelsen AE, Munthe LA, Lund-Johansen F, Ahlen MT, Wiedmann M, Aamodt A-H, Skattør TH, Tjønnfjord GE, Holme PÅ. Thrombosis and thrombocytopenia after ChAdOx1 nCoV-19 vaccination. *N Engl J Med* 2021. April 9; DOI: 10.1056/NEJMoa2104882

Greinacher A, Thiele T, Warkentin TE, Weisser K, Kyrle PA, Eichinger S. Thrombotic thrombocytopenia after ChAdOx1 nCoV-19 vaccination. *N Engl J Med* 2021. April 9; DOI: 10.1056/NEJMoa2104840

**Table 1 - Blood tests during the admission of a 60-year old woman with ischemic stroke and immune mediated thrombocytopenia following vaccination.**

	Day 1	Day 2 <sup>a</sup>	Day 3	Day 6	Reference range
C-reactive protein (mg/L)	2.6	188	235	67	<8.0
Pro-calcitonin (µg/L)			0.33	0.17	<0.5
White-cell count (per µL)	11,100	8,500	6,700	5,800	3,500-10,000
Neutrophil count (per µL)	9,500	6,220	4,940	3,960	2,000-7,000
Lymphocyte count (per µL)	860	1,560	1,130	900	1,300-3,500
Monocyte count (per µL)	630	600	470	680	200-700
Eosinophil count (per µL)	10	110	100	0	<500
Hemoglobin (g/dL)	14.0	13.7	13.5	8.4	11.8 – 15.3
Haptoglobin (mg/dL)			160		50-210
Sodium (mmol/L)	138	133	135	159	137-145
Potassium (mmol/L)	3.1	3.5	3.7	4	3.5-4.6
Lactic acid (mg/dL)	18.02	5.40	5.40	6.31	4.5-22.5
Creatinine (mg/dL)	0.77	1.14	1.0	1.04	0.51-1.02
INR	1.0	1.1	1.2	1.1	<1.2
APTT (s)		28	32	27	22-38
Platelet count (per µL)	118,000	50,000	24,000	5,000	165,000-400,000
D-dimer (ng FEU/mL)		41,800	97,800	106,200	< 500
Factor V leiden mutation			Heterozygous		
Antithrombin (IU/mL)		0.70	0.67	0.9	0.80-1.20
Fibrinogen (mg/dL)		374	269	231	170- 374
Tromboelastrometry (ROTEM)					
EXTEM CT (sec) <sup>b</sup>			84		<74
EXTEM A10 (mm) <sup>b</sup>			46		>48
FIBTEM A10 (mm) <sup>b</sup>			14		>8
INTEM CT (sec) <sup>b</sup>			144		<121
Protein C activity (IU/mL)			0.70		0.70-1.40
Protein S, free antigen			0.68		0.55-1.20
Antiphospholipid antibodies <sup>c</sup>			Negative		
Blood smear description			No definite schistocytes		

Immunoglobulins IgA/IgM/IgG				Normal	
Complement C3c/C4				Normal	
Cryoglobulins				Not present	
Antineutrophilic antibodies			0		<1
ADAMTS13				Normal	
Platelet antibodies <sup>d</sup>				Not present	

Abbreviations: INR: international normalized ratio, APTT: activated partial thromboplastin time, FEU: fibrinogen-equivalent units. IU: international units. ROTEM: rotational thromboelastometry, ADAMTS13: a disintegrin and metalloproteinase with a thrombospondin type 1 motif, member 13

To convert values for hemoglobin to millimoles per liter multiply by 0.6202, lactic acid to millimoles per liter multiply by 0.1110, creatinine to micromoles per liter multiply by 88.4, fibrinogen to micromoles per liter multiply by 0.0294

<sup>a</sup> The blood sample on day 2 was sampled 1-2 hours after stroke onset, and additional tests (d-Dimer, fibrinogen, antithrombin) 7 hours after the first sample. Platelet count 8 hours before stroke onset was 55,000 per  $\mu\text{L}$

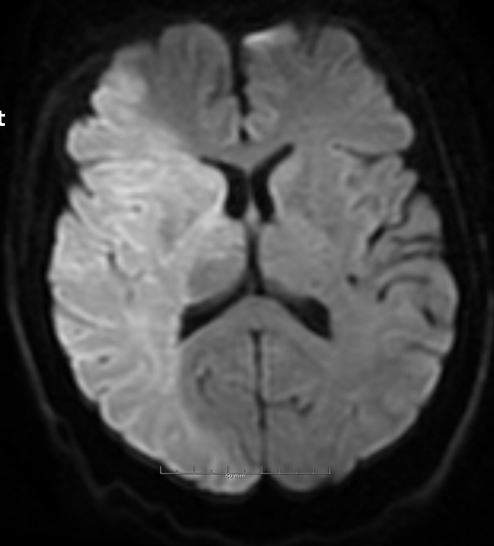
<sup>b</sup> EXTEM CT: Extrinsic pathway (tissue factor) clotting time. EXTEM A10: Amplitude of formed clot 10 minutes after formation. FIBTEM A10: Fibrin dependent clot formation, amplitude of the formed clot at 10 minutes. INTEM CT: Intrinsic pathway clotting time.

<sup>c</sup> Lupus anticoagulant, and Beta-2-glycoprotein 1 and cardiolipin antibodies

<sup>d</sup> Antibodies against GP-IIb/IIIa, GP-Ia/IIa, GP-Ib/IX and GP-IV

Day 2

Right



Day 3

Right

