

Multimodal imaging of the distal interphalangeal-joint synovio-entheseal complex in psoriatic arthritis (MIDAS)

a cross-sectional study on the diagnostic accuracy of different imaging modalities comparing psoriatic arthritis to psoriasis and osteoarthritis

Guldborg-Møller, Jørgen; Mogensen, Mette; Ellegaard, Karen; Zavareh, Ali; Wakefield, Richard J; Tan, Ai Lyn; Boesen, Mikael; Dehmeshki, Jamshid; Kubassova, Olga; Dreyer, Lene; Henriksen, Marius; Kristensen, Lars Erik

Published in:
RMD Open

DOI (link to publication from Publisher):
[10.1136/rmdopen-2021-002109](https://doi.org/10.1136/rmdopen-2021-002109)

Creative Commons License
CC BY-NC 4.0

Publication date:
2022

Document Version
Publisher's PDF, also known as Version of record

[Link to publication from Aalborg University](#)

Citation for published version (APA):

Guldborg-Møller, J., Mogensen, M., Ellegaard, K., Zavareh, A., Wakefield, R. J., Tan, A. L., Boesen, M., Dehmeshki, J., Kubassova, O., Dreyer, L., Henriksen, M., & Kristensen, L. E. (2022). Multimodal imaging of the distal interphalangeal-joint synovio-entheseal complex in psoriatic arthritis (MIDAS): a cross-sectional study on the diagnostic accuracy of different imaging modalities comparing psoriatic arthritis to psoriasis and osteoarthritis. *RMD Open*, 8(1), Article e002109. <https://doi.org/10.1136/rmdopen-2021-002109>

General rights

Copyright and moral rights for the publications made accessible in the public portal are retained by the authors and/or other copyright owners and it is a condition of accessing publications that users recognise and abide by the legal requirements associated with these rights.

- Users may download and print one copy of any publication from the public portal for the purpose of private study or research.
- You may not further distribute the material or use it for any profit-making activity or commercial gain
- You may freely distribute the URL identifying the publication in the public portal -



Take down policy

If you believe that this document breaches copyright please contact us at vbn@aub.aau.dk providing details, and we will remove access to the work immediately and investigate your claim.

Downloaded from vbn.aau.dk on: June 24, 2025

ORIGINAL RESEARCH

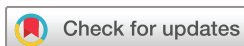Multimodal imaging of the distal interphalangeal-joint synovio-entheseal complex in psoriatic arthritis (MIDAS): a cross-sectional study on the diagnostic accuracy of different imaging modalities comparing psoriatic arthritis to psoriasis and osteoarthritis

Jørgen Guldberg-Møller ^{1,2}, Mette Mogensen,³ Karen Ellegaard,¹ Ali Zavareh,⁴ Richard J Wakefield,⁵ Ai Lyn Tan ⁵, Mikael Boesen,⁶ Jamshid Dehmeshki,⁷ Olga Kubassova,⁷ Lene Dreyer,^{1,8} Marius Henriksen,¹ Lars Erik Kristensen¹

To cite: Guldberg-Møller J, Mogensen M, Ellegaard K, *et al.* Multimodal imaging of the distal interphalangeal-joint synovio-entheseal complex in psoriatic arthritis (MIDAS): a cross-sectional study on the diagnostic accuracy of different imaging modalities comparing psoriatic arthritis to psoriasis and osteoarthritis. *RMD Open* 2022;**8**:e002109. doi:10.1136/rmdopen-2021-002109

► Additional supplemental material is published online only. To view, please visit the journal online (<http://dx.doi.org/10.1136/rmdopen-2021-002109>).

Received 15 November 2021
Accepted 7 March 2022



© Author(s) (or their employer(s)) 2022. Re-use permitted under CC BY-NC. No commercial re-use. See rights and permissions. Published by BMJ.

For numbered affiliations see end of article.

Correspondence to

Dr Jørgen Guldberg-Møller; joergen.guldberg-moeller@regionh.dk

ABSTRACT

Objective Can ultrasound (US), MRI and X-ray applied to the distal interphalangeal (DIP)-joint and synovio-entheseal complex (SEC) discriminate between patients with psoriatic arthritis (PsA), skin psoriasis (PsO) and hand osteoarthritis (OA)?

Methods In this prospective, cross-sectional study, patients with DIP-joint PsA and nail involvement (n=50), PsO with nail involvement (n=12); and OA (n=13); were consecutively recruited. Risk ratios (RR) were calculated for US, MRI and X-ray findings of the DIP-joint and SEC between diagnoses.

Results New bone formation (NBF) in US and MRI was a hallmark of OA, reducing the risk of having PsA (RR 0.52 (95% CI 0.43 to 0.63) and 0.64 (95% CI 0.56 to 0.74). The OA group was different from PsA and PsO on all MRI and X-ray outcomes reflected in a lower RR of having PsA; RR ranging from 0.20 (95% CI 0.13 to 0.31) for MRI bone marrow oedema (BMO) to 0.85 (95% CI 0.80 to 0.90) in X-ray enthesitis. No outcome in US, MRI or X-ray was significantly associated with a higher risk of PsA versus PsO, although there was a trend to a higher degree of US erosions and NBF in PsA. 82% of PsA and 67% of PsO was treated with disease modifying antirheumatic drugs which commonly reflects the clinical setting.

Conclusion High grade of US, MRI and X-ray NBF reduce the RR of having PsA compared with OA. In PsA versus PsO patients, there was a trend for US to demonstrate more structural changes in PsA although this did not reach significance.

INTRODUCTION

Psoriatic arthritis (PsA) is seen in 5%–40% of patients with psoriasis (PsO)¹ with a typical delay of 7 years,^{2,3} and the incidence has been

Key messages

What is already known about this subject?

- Psoriatic arthritis (PsA) is seen in 5%–40% of patients with psoriasis (PsO). No gold-standard diagnostic test for PsA exists. The diagnosis relies on different patterns of symptom involvement, which can mimic other arthritides such as osteoarthritis (OA).

What does this study add?

- The differentiation between PsA, PsO and hand OA using ultrasound (US), MRI and X-ray is possible based on the grade of structural disease involvement using semiquantitative OMERACT US scores, MRI PsAMRIS score and X-ray score.

How might this impact on clinical practice or further developments?

- A high grade of US, MRI and X-ray new bone formation (NBF) and MRI bone marrow oedema reduce the risk ratio of having PsA compared with OA.
- In demarcating PsA from PsO patients, it is of importance if they present with a high degree of US erosions and NBF or MRI synovitis, tenosynovitis, erosion score or bone marrow oedema.

rising in the last two decades.⁴ The transition from inflammatory skin disease to a heterogeneous and widespread joint disease^{5–7} represents a shared diagnostic challenge in dermatology and rheumatology. As no gold-standard diagnostic test for PsA exists, establishing the diagnosis relies on different patterns of clinical, radiological and serological markers

expressed in the classification criteria for psoriatic arthritis (CASPAR).⁸ Also, some typical features of PsA can mimic other arthritides such as rheumatoid arthritis (RA)⁹ and hand osteoarthritis (OA), which can cause a significant delay of the diagnosis with a potential impact on therapy for patients and costs to society.^{10–11} RA rarely affects the distal interphalangeal (DIP)-joint,¹² but both bone proliferation and inflammation processes in the DIP-joint are shared entities in PsA and OA.^{13–14}

Nail dystrophy is a prognostic marker of DIP-joint arthritis,¹⁵ with a prevalence between 41%–93% in PsA and 15%–50% in PsO.^{16–18} This suggests that nail dystrophy can serve as an early diagnostic entity to identify the transition from PsO to PsA. A proposed anatomical relationship between the nail and DIP-joint through the extensor tendon and joint capsule suggests that psoriatic nail manifestations are extensions of enthesopathy in the neighbouring structures, referred to as the synovio-enthesal complex (SEC).^{14–19–20}

Comparisons of different objective disease markers between PsO, PsA and OA may allow an improved understanding of the transition from PsO to PsA and distinguish it from OA. A range of imaging modalities have been applied to explore the nail, DIP joints and SEC in PsA.

MRI studies support the SEC-theory as DIP joint disease in PsA is associated with enthesal inflammation, suggesting that the entheses are the epicentre for inflammatory changes in PsA DIP-joint disease.¹⁴

Ultrasound (US) has demonstrated an association between extensor tendon enthesopathy and clinical nail involvement.²¹ Nail pitting and onycholysis in PsO have been associated with a higher risk of subsequent transition to DIP-joint arthritis and PsA.^{15–22}

Although X-ray has been less sensitive than US and MRI in evaluating chronic changes in arthritis,^{23–24} such as erosions and new bone formation (NBF), it is frequently used in the initial diagnostic workup in a patient suspected of inflammatory arthritis. Diagnostic patterns of destructive or proliferative changes in X-ray thus play a vital role in the initial differentiation of arthritides.

While these different imaging modalities have been applied in separate studies to explore the nail and SEC, they have never been applied in combination in the same anatomical region in related disease entities. By doing so, distinct patterns of joint, nailfold and enthesal involvement may be revealed to more accurately distinguish subtle differences between PsA, PsO and Hand OA to diagnose PsA earlier.

This study investigates if US, MRI and X-ray applied to the DIP-joint and SEC can be used to discriminate between patients with PsA, PsO and OA.

METHODS

This prospective study included cross-sectional data on consecutively enrolled patients with PsA, PsO with nail involvement and both erosive and non-erosive hand

OA. Only DIP-joints 2–5 of the dominant hand were assessed. The study followed the Standards for Reporting Diagnostic accuracy studies (STARD) guidelines²³ and a prespecified protocol (see online supplemental file 1).

Between 1 December 2017 and 1 June 2020, patients with PsA according to the CASPAR criteria⁸ and a Nail Psoriasis Severity Index (NAPSI) score ≥ 5 were enrolled from three rheumatology outpatient clinics located in the Capital Region of Denmark and the Zealand Region in Denmark. Patients with OA and PsO were recruited from the OA, rheumatology and dermatology outpatient clinics at Bispebjerg and Frederiksberg Hospital. The PsO patients were diagnosed by a dermatologist and the OA patients by a rheumatologist according to the ACR criteria for hand OA.²⁴ For eligibility criteria (see online supplemental file 2).

Patient-reported outcome measures

The physical function was addressed by the Health Assessment Questionnaire Disability Index (HAQ-DI).²⁵ The average joint-related pain, general fatigue and global assessment of disease impact within the last week were assessed by Visual Analogue Scales 0–100 mm (VAS) with anchors: 0=no pain/fatigue/impact and 100=worst imaginable pain/fatigue/impact.

Clinical examination

A trained rheumatologist (JG-M) with 9 years of clinical experience conducted: 66/68 swollen/tender joint count, a Psoriatic Area Severity Index score, a full NAPSI score (score 0–8 on each nail), and Spondyloarthritis Research Consortium of Canada Enthesitis Index (score 0–16, based on nine bilateral sites; the inferior patella and tibial tuberosity are considered one site).²⁶ The clinician was blinded to other examinations.

US assessment

US assessment was performed by an experienced (15 years) and certified sonographer (KE) blinded to the clinical results.

US assessments were performed in the longitudinal plane for DIP-joint 2–5 using a General Electric Logiq E9 (Milwaukee, Wisconsin, USA) and a linear array matrix transducer (9–15 MHz frequency). The choice of the probe was based on the consensus of international experts in US in an unpublished web-survey (online supplemental file 3).

The dorsal and volar aspects of second to fifth DIP-joint was semiquantitatively scored 0–3 for the presence of Grey-scale SH Colour Doppler, NBF and erosions according to the OMERACT standards.²⁷ Flexor and extensor tendon, nail matrix, nail bed and nail thickness were measured in mm. in the longitudinal plane. The ratio of coloured/grey pixels in a predefined ROI was calculated (QAnalysis GE software V.R6 2.0) and reported as Max-ratio and Min-ratio.²⁸ All US images analysis was done blinded to diagnosis by JG-M. See online supplemental file 4 for full US protocol.

Magnetic resonance imaging

The distal phalanges and DIP-joint from the 2nd to 5th fingers were examined in a 3T Siemens Verio MRI scanner using a semi-flex 16 channel body coil. A modified PsAMRIS-score²⁹ was used in this study encompassing the DIP-joint: D-PsAMRIS range 0–35.

Dynamic contrast-enhanced (DCE)-MRI images were analysed using DYNAMIKA software (Image analysis group, London UK). A 3-dimensional ROI was drawn around the distal phalanges and DIP-joint from 2nd to 5th fingers. The computed output data in the various ROIs comprise the mean of the initial rate of enhancement (IRE), maximum enhancement (ME), number of enhancing voxels (NVoxels) and composite scores: IRE*NVoxels and ME*NVoxels.

The MRI analyses were performed by a radiologist (MB) with 15 years of experience blinded to diagnosis

and imaging findings. For complete MRI protocol and DCE-MRI analysis method, see online supplemental file 5).

X-ray

Plain posterior-anterior radiographs of the 2nd to 5th DIP-joint was evaluated for enthesal bone-change and erosions and scored 0–3 (0: no changes and 3: large changes). The images were evaluated by a trained radiologist (AZ) with 5 years of experience blinded to diagnosis and other imaging findings. For protocol, see online supplemental file 6.

Statistics

The number of PsA patients was predefined and based on power calculations in the protocol (online supplemental file 1) to 50 participants, and OA and PsO to at

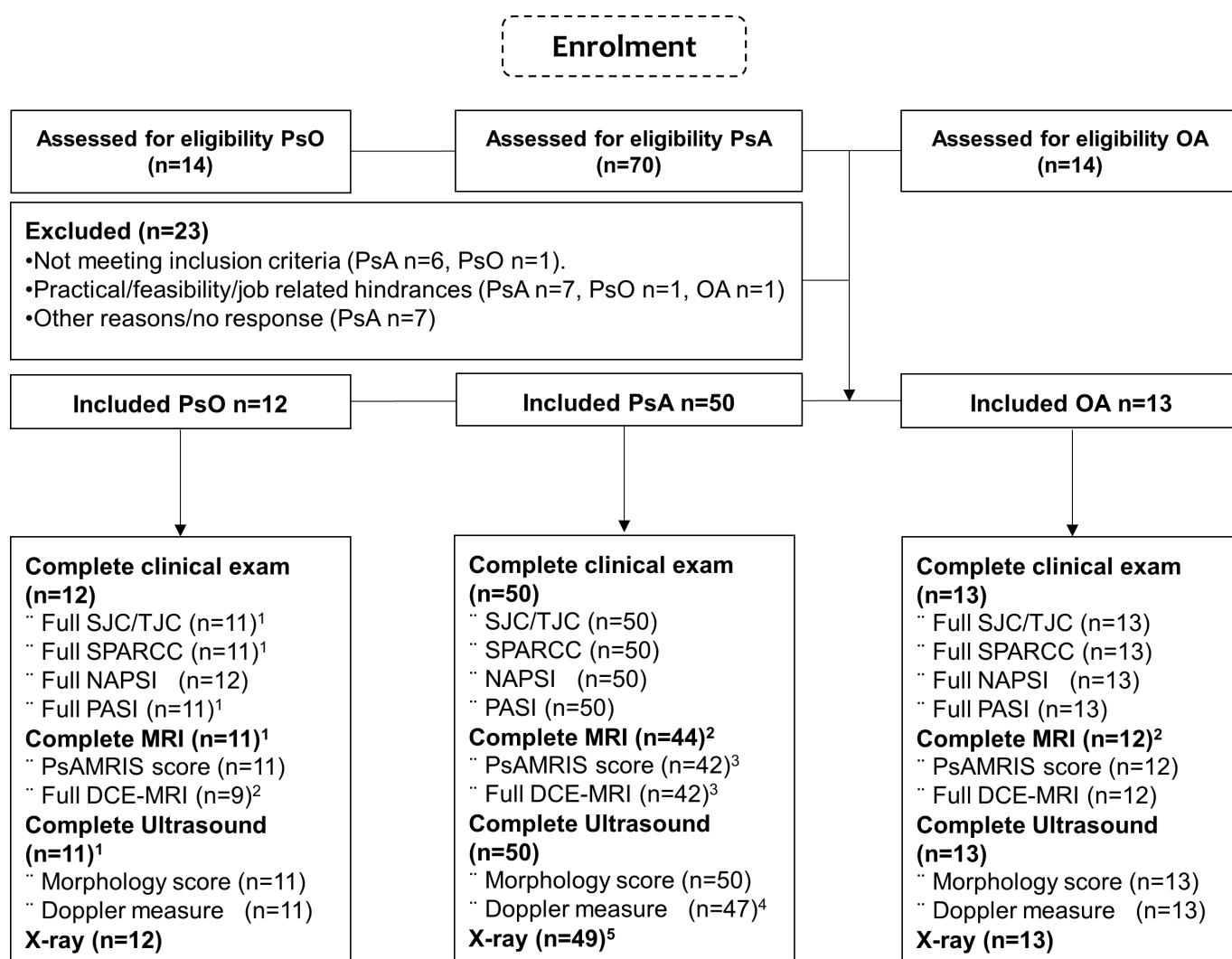


Figure 1 Flow chart of study participants. ¹Reasons for declining further participation: no response after first examination day (PSA n=1, PsO n=1). ²No MRI: Obesity/ claustrophobic (PSA n=3, OA n=1), MRI without gadolinium contrast (PSA n=3, PsO n=2). ³Finger out of scanning plane (PSA n=2). ⁴Image not acquired: due to deformity (PSA n=1), missing per US-protocol (PSA n=1). No Dopplerclip: poor quality (PSA n=1). ⁵Image of non-target hand (n=1). DCE, dynamic contrast-enhanced; NAPS I, Nail Psoriasis Severity Index; OA, osteoarthritis; PASI, Psoriatic Area Severity Index; PSA, psoriatic arthritis; PsO, skin psoriasis; SPARCC, Spondyloarthritis Research Consortium of Canada; SJC/TJC, swollen joint count/tender joint count. Flow chart template modified from <http://www.equator-network.org/reporting-guidelines/stard/>

Table 1 Demographics and characteristics of PSA, PSO and OA patients

	Baseline variables	PsA n=50 (48%)	PsO n=12 (11%)	Hand OA n=13 (12%)
Socio-Demography / treatment	Females, n (%)	21 (42)	5 (41)	13 (100)
	Age, years, mean (SD)	54.4 (12.0)	55.3 (18.0)	69.5 (8.9)
	Disease duration months	60 (19;120)	25 (12;96)	78 (12;99)
	Height, cm, mean (SD)	172.8 (10.0)	173.3 (10.0)	160.2 (6.7)
	weight, kg, mean (SD)	85.7 (16.8)	82.6 (16.3)	62.7 (10.7)
	BMI m/kg ² , mean (SD)	28.8 (6.6)	27.5 (5.3)	24.3 (2.5)
	Treated with csDMARDS, n (%)	30 (60)	3 (25)	1 (7)*
	Treated with bDMARDS, n (%)	4 (8)	5 (42)	0
	Treated with both bDMARDS and csDMARDS, n (%)	7 (14)	0	0
	No treatment, n (%)	9 (18)	4 (33)	12 (93)
PROM	HAQ-DI (0–3)	0.44 (0.13;0.88)	0.00 (0.00;0.13)	0.63 (0.25;0.88)
	VAS Fatigue (0–100), mean (SD)	47.6 (27.8)	27.3 (22.9)	24.8 (22.1)
	VAS Pain (0–100), mean (SD)	36.2 (26.3)	9.5 (10.8)	42.2 (21.2)
	VAS Global (0–100), mean (SD)	44.5 (28.0)	14.6 (17.5)	40.7 (22.9)
Clinical measures	Swollen joint count (0–66)	3.5 (1.0;5.0)	1.0 (0;3.0)	2.0 (1.0;4.0)
	Tender joint count (0–68)	6.5 (1.0;14.0)	0.0 (0.0;2.0)	9.0 (5.0;11.0)
	PASI (0–72)	1.9 (0.8;4.0)	1.8 (0.0;6.1)	0.0 (0.0;0.0)
	SPARCC (0–16)	2.0 (1.0;5.0)	1.0 (0.0;2.0)	2.0 (0.0;2.0)
	NAPSI-score total finger 2 (0–8)	3.0 (2.0;4.0)	3.5 (2.0;5.0)	0.0 (0.0;0.0)
	NAPSI-score total finger 3 (0–8)	3.0 (2.0;4.0)	4.0 (2.3;4.8)	0.0 (0.0;0.0)
	NAPSI-score total finger 4 (0–8)	2.0 (1.0;4.0)	3.5 (2.0;5.8)	0.0 (0.0;0.0)
	NAPSI-score total finger 5 (0–8)	2.0 (1.0;4.0)	2.0 (1.0;3.0)	0.0 (0.0;0.0)

Data are presented as median (25th–75th percentiles) unless otherwise stated.

*One patient referred as PsA did not fulfil the CASPAR criteria at the screening visit and was thus rediagnosed as hand OA and had DMARD terminated upon inclusion.

bDMARD, biological DMARD; BMI, body mass index; csDMARD, conventional synthetic DMARD; DMARD, disease modifying antirheumatic drug; HAQ-DI, Health Assessment Questionnaire Disability Index; NAPSI, Nail Psoriasis Severity Index; OA, osteoarthritis; PASI, Psoriatic Area Severity Index; PROM, patient-reported outcome measures; PsA, psoriatic arthritis; PSO, psoriasis; SPARCC, Spondyloarthritis Research Consortium of Canada; VAS, Visual Analogue Scale.

least 10 and less than 20 subjects to detect changes at a meaningful clinical frequency.

The primary analyses focused on assessing differences between diagnoses (the reference standard) in US, MRI and X-ray assessments (index tests) of the SEC. We analysed all data, that is, four fingers, from each participant. The quantitative and semiquantitative US, MRI and X-ray outcomes were analysed using mixed linear models with diagnosis as a fixed factor (three levels: PsA, PsO and OA) and participant as a random factor. The binominal outcomes were compared using Pearson χ^2 . OR and risk ratio assessment were calculated using crosstabs, and differences ORs between groups were calculated by Mantel-Haenszel Common OR Estimate. The diagnostic properties of the index tests: US, MRI and X-ray, was calculated using logistic regression analyses on the three groups pooled with diagnosis (PsA vs PsO and PsA vs OA) as a dependent variable and the quantitative US, MRI and X-ray outcomes as independent variables. The cut-off points to reliably diagnose PsA is determined

using a receiver operating characteristic curve analysis estimating the area under the curve. No imputation of missing data was performed.

Intraobserver reliability for the US scores was assessed on 100 randomly chosen DIP-joints scored twice by the same rater (JG-M) separated by 10 days. The intrarater reliability was quantified using the intraclass correlation coefficient (ICC)^{30 31} and weighted Kappa. The intrarater reliability was good (lowest ICC: 0.64 and lowest Kappa: 0.73; see online supplemental file 7).

The analyses were conducted using IBM SPSS Statistics V.25.

RESULTS

Out of 98 screened subjects, we included 50 patients with PsA, 12 with PsO and 13 with OA (figure 1). The demographics of the three groups are shown in table 1. Patients with PsA and PsO were younger than OA patients and had a higher body mass index.

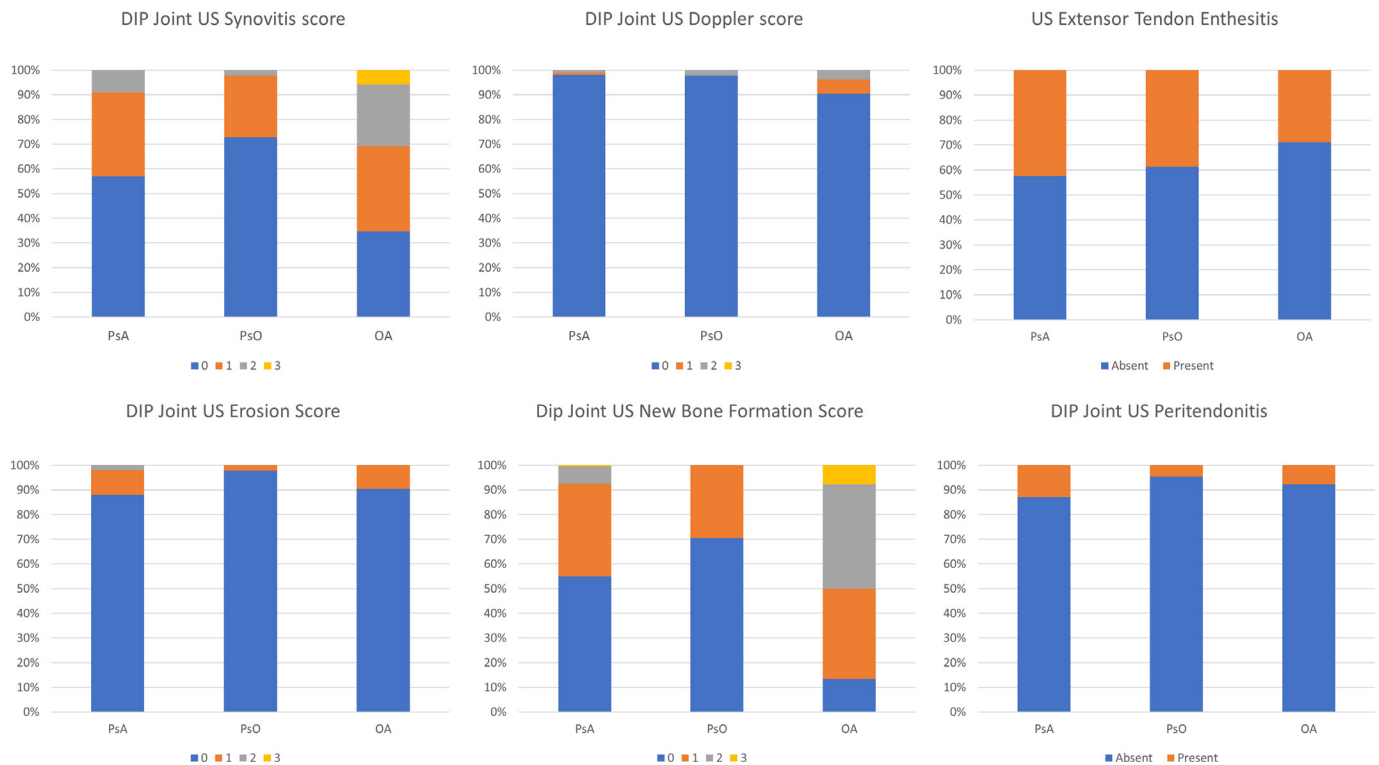


Figure 2 Percentual distributions of US findings of the distal interphalangeal joints among patients with PSA, PSO and hand OA according to the grade of involvement 0–3 or as absent or present. DIP, distal interphalangeal; OA, osteoarthritis; PSA, psoriatic arthritis; PSO, skin psoriasis, US, ultrasound.

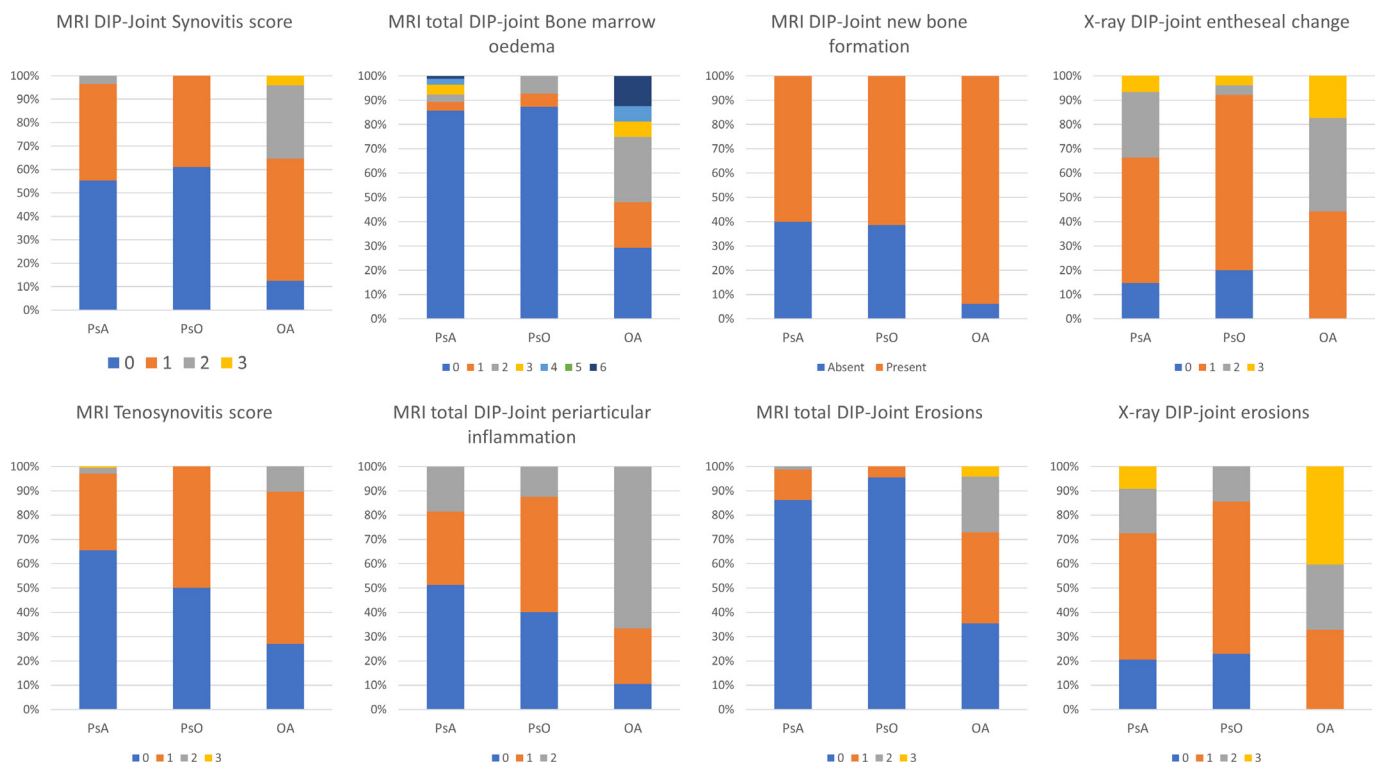


Figure 3 Percentual distributions of MRI and X-ray findings of the distal interphalangeal joint among patients with PSA, PSO and hand OA according to the grade of involvement or absent or present. DIP, distal interphalangeal; OA, osteoarthritis; PSA, psoriatic arthritis; PSO, skin psoriasis.

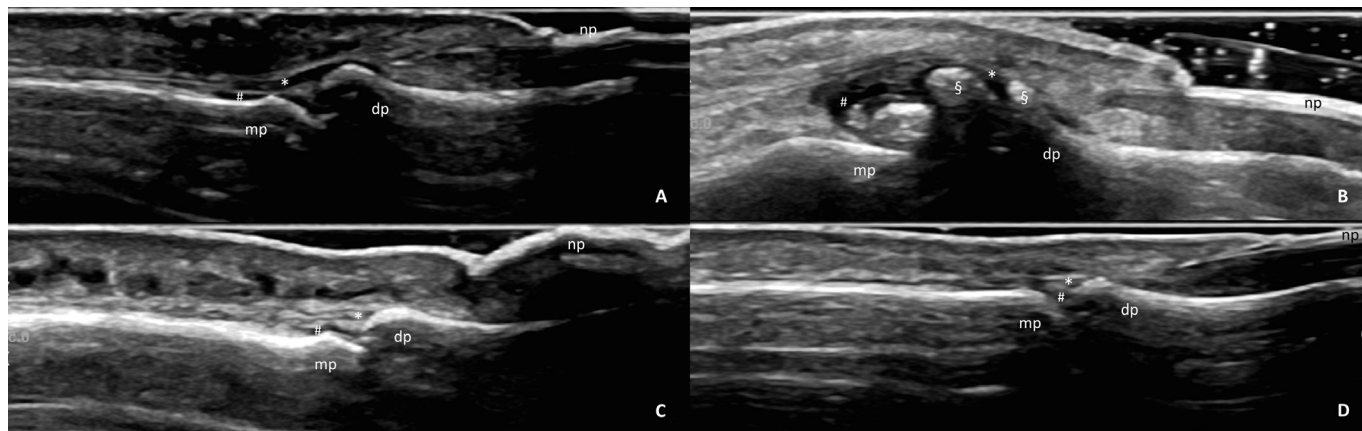


Figure 4 Ultrasonographic image of the synovio-entheseal-complex. Dorsal longitudinal scan. (A) Patients with psoriatic arthritis with loss of normal fibrillar architecture at extensor tendon insertion (*) at DP and effusion at the distal interphalangeal joint (#). (B) Patient with osteoarthritis with severe new bone formation (§), effusion and synovial hypertrophy of the distal interphalangeal joint (#). (C) Patients with skin psoriasis with severe thickening and loss of trilaminar structure of the NP. (D) Healthy control demonstrating normal fibrillar architecture of the extensor tendon (*) and a healthy NP with trilaminar structure as two hyperechoic lines surrounding an anechoic line. DP, distal phalanx; MP, medial phalanx; NP, nail plate.

The distribution of US outcomes of the three groups is shown in [figure 2](#). The PsA group showed the highest prevalence of extensor tendon enthesitis (42.5%), peritendonitis (13%) and DIP joint erosions (11%). The OA group had the highest prevalence of DIP joint SH (65.4%), US Doppler (9.6%) and NBF (86.5%).

The OA group presented the highest prevalence of all the outcomes in MRI PsAMRIS of the three groups and had no grade 0 outcomes in X-ray enthesal bone-change or erosions, as seen in [figure 3](#). The PsA and PsO groups were similar in MRI PsAMRIS- and X-ray outcomes, but the PsA group presented more severe disease grades in both MRI DIP-joint synovitis score, MRI bone marrow oedema and a higher prevalence of MRI DIP-joint erosion. Differences in US findings of the SEC are highlighted in [figure 4](#).

The differences of US, MRI and X-ray are shown in [table 2](#). US NBF in OA was statistically significantly different from PsA with a mean difference of 0.91 points (95% CI 0.67 to 1.16) on the 0–3 scale. OA was also statistically significantly different from PsA with a higher degree of US SH (mean difference: 0.50 points (95% CI 0.21 to 0.79)) on the 0–3 scale. No significant differences were seen between groups for US extensor tendon enthesitis and peritendonitis.

Apart from DCE-MRI flow measures, the OA group was significantly different from PsA and PsO on all MRI PsAMRIS outcomes and X-ray outcomes ([table 2](#)). These differences resulted in a much lower risk of having PsA than OA when these outcomes were present at a high grade in MRI PsAMRIS and X-ray, as shown in [table 3](#). In US, only the presence of Doppler signals and the severity of NBF were associated with a reduced risk of PsA, risk ratio 0.21 (95% CI 0.06 to 0.75) and 0.52 (95% CI 0.43 to 0.63) respectively. No imaging-based variable was a positive predictor for PsA versus OA ([table 3](#)).

PsA and PsO were differentiated by the presence of erosions and NBF with a mean difference of 0.12 points (95% CI –0.01 to 0.24, $p=0.07$) and mean 0.24 points (95% CI –0.03 to 0.50, $p=0.08$), respectively, on 0–3 scales. A more pronounced difference in the presence of enthesal change between PsA and PsO was found in X-ray 0.42 points (95% CI 0.06 to 0.79, $p=0.024$). No outcome in US, MRI or X-ray was associated with a higher risk of having PsA vs PsO ([table 3](#)).

No measures of flow in US Doppler quantification or DCE-MRI could differentiate between PsA, PsO or OA. Numeric measures of the flexor/extensor entheses, nail bed/matrix or nail did not reveal any significant outcome patterns in the three groups, which was reflected in an overall low sensitivity to PsA diagnosis shown in online supplemental file 8). The best discriminatory factor between PsA vs PsO was DCE-MRI Flow ME*nVOXEL 0.59 (95% CI 0.47 to 0.68) and PsA vs OA DCE-MRI Flow IRE*nVOXEL 0.65 (95% CI 0.56 to 0.74).

DISCUSSION

In this comprehensive cross-sectional study, we demonstrated significant patterns of US, MRI and X-ray findings dependent on the underlying diagnosis. Using US, the PsA group demonstrated a trend for a higher % prevalence of extensor tendon enthesitis, erosions and peritendonitis ([figure 2](#)), which did not reach statistical significance. Apart from X-ray detected enthesal change, it was not possible to differentiate between the PsA group and PsO group using MRI or X-ray, thus strengthening the link of nail disease to enthesitis and synovitis as a continuum with a yet unknown threshold.³² Nevertheless, differences in PsA and PsO patients was identified looking at structural disease grade in both US and MRI outcomes ([figures 2 and 3](#)). In PsO patients, the diagnosis of PsA is not likely unless they present with X-ray

Table 2 Differences in MRI, X-ray and US outcomes of the distal interphalangeal joints and components of the synovial-entheseal-complex in PSA compared with OA and PSO with corresponding 95% CI

	PsA mean (SE)	Diagnosis	Mean (SE)	Mean difference	95% CI	P value
US Extensor tendon thickness, mm	0.669 (0.013)	OA	0.673 (0.025)	-0.004	-0.059 to 0.051	0.878
		PsO	0.682 (0.027)	-0.013	-0.072 to 0.056	0.677
US Flexor Tendon thickness, mm	0.846 (0.022)	OA	0.888 (0.043)	-0.042	-0.138 to 0.054	0.392
		PsO	0.871 (0.047)	-0.025	-0.128 to 0.079	0.644
US nail matrix thickness, mm	2.061 (0.055)	OA	2.119 (0.107)	-0.058	-0.297 to 0.181	0.630
		PsO	2.016 (0.117)	0.045	-0.211 to 0.301	0.727
US nail bed thickness, mm	1.769 (0.051)	OA	1.704 (0.1)	0.065	-0.157 to 0.287	0.565
		PsO	1.964 (0.108)	-0.195	-0.432 to 0.042	0.106
US nail thickness, mm	0.631 (0.014)	OA	0.612 (0.027)	0.019	-0.041 to 0.080	0.523
		PsO	0.673 (0.029)	-0.042	-0.106 to 0.023	0.202
US flow Max ratio	0.329 (0.024)	OA	0.338 (0.047)	-0.009	-0.113 to 0.095	0.863
		PsO	0.389 (0.051)	-0.060	-0.172 to 0.051	0.287
US flow Min ratio	0.148 (0.017)	OA	0.121 (0.034)	0.027	-0.048 to 0.102	0.481
		PsO	0.196 (0.037)	-0.049	-0.129 to 0.032	0.231
US synovial hypertrophy (0-3)	0.520 (0.067)	OA	1.019 (0.130)	-0.499	-0.790 to -0.209	0.001
		PsO	0.318 (0.142)	0.202	-0.109 to 0.513	0.201
US Doppler signals (0-3)	0.030 (0.021)	OA	0.135 (0.047)	-0.105	-0.194 to -0.015	0.023
		PsO	0.045 (0.044)	0.030	-0.111 to 0.081	0.750
US erosions (0-3)	0.140 (0.027)	OA	0.096 (0.053)	0.044	-0.073 to 0.161	0.460
		PsO	0.023 (0.057)	0.117	-0.008 to 0.243	0.067
US new bone formation (0-3)	0.530 (0.056)	OA	1.442 (0.110)	-0.912	-1.158 to -0.667	<0.001
		PsO	0.295 (0.120)	0.235	-0.028 to 0.497	0.079
MRI synovial hypertrophy	0.482 (0.066)	OA	1.271 (0.123)	-0.789	-1.067 to 0.510	<0.001
		PsO	0.389 (0.142)	0.093	-0.219 to 0.406	0.553
MRI tenosynovitis	0.381 (0.060)	OA	0.833 (0.113)	-0.452	-0.709 to -0.196	0.001
		PsO	0.500 (0.131)	-0.119	-0.407 to 0.169	0.441
MRI periarticular inflammation	0.673 (0.755)	OA	1.563 (0.140)	-0.890	-1.206 to -0.573	<0.001
		PsO	0.725 (0.153)	-0.052	-0.393 to 0.288	0.759
MRI bone marrow oedema	0.387 (0.138)	OA	1.917 (0.259)	-1.530	-0.157 to 0.287	<0.001
		PsO	0.250 (0.270)	0.137	-0.470 to 0.744	0.654
MRI erosions	0.197 (0.069)	OA	1.271 (0.129)	-1.074	-1.365 to -0.782	<0.001
		PsO	0.091 (0.134)	0.106	-0.195 to 0.408	0.484
DCE-MRI flow ME*nVOXEL	1062.886 (110.177)	OA	879.622 (193.744)	183.264	-247.983 to 614.510	0.399
		PsO	699.788 (202.359)	363.098	-83.617 to 809.813	0.109
DCE-MRI flow IRE*nVOXEL	8.647 (0.983)	OA	5.322 (1.966)	3.325	-1.073 to 7.722	0.136
		PsO	11.042 (2.313)	-2.395	-7.422 to 2.632	0.344
X-ray erosions (0-3)	1.163 (0.091)	OA	2.077 (0.177)	-0.914	-1.310 to -0.418	<0.001
		PsO	0.917 (0.184)	0.247	-0.162 to 0.656	0.233
X-ray enthesal change (0-3)	1.255 (0.081)	OA	1.731 (0.158)	-0.476	-0.830 to -0.121	0.009
		PsO	0.833 (0.164)	0.422	0.056 to 0.788	0.024

Bold values are statistical significant $p \leq 0.05$.

DCE, dynamic contrast-enhanced; IRE, Initial rate of enhancement; ME, maximum enhancement; OA, osteoarthritis; PsA, psoriatic arthritis; PsO, skin psoriasis; US, ultrasound.

Table 3 The OR and risk ratio for psoriatic arthritis if imaging outcomes are present in MRI, X-ray and US compared with PsO or OA with 95% CI

Imaging outcomes	Groups	n(%) / n(%)	OR for PsA diagnosis (95% CI)	P value*	Risk ratio for PsA (95% CI)
MRI DIP-joint synovial hypertrophy	PsA/PsO	75 (45)/14 (39)	1.27 (0.61 to 2.65)	0.528	1.15 (0.74 to 1.79)
	PsA/OA	75 (45)/42 (88)	0.12 (0.05 to 0.29)	<0.001	0.51 (0.42 to 0.62)
MRI Tenosynovitis	PsA/PsO	58 (35)/18 (50)	0.53 (0.26 to 1.09)	0.081	0.69 (0.47 to 1.02)
	PsA/OA	558 (35)/35 (73)	0.20 (0.10 to 0.40)	<0.001	0.47 (0.36 to 0.62)
MRI New bone formation	PsA/PsO	101 (60)/27 (61)	0.95 (0.48 to 1.88)	0.881	0.98 (0.75 to 1.28)
	PsA/OA	101 (60)/45 (94)	0.10 (0.03 to 0.34)	<0.001	0.64 (0.56 to 0.74)
MRI Periarticular inflammation	PsA/PsO	82 (49)/24 (60)	0.64 (0.32 to 1.28)	0.205	0.81 (0.61 to 1.09)
	PsA/OA	82 (49)/43 (90)	0.11 (0.04 to 0.29)	<0.001	0.55 (0.45 to 0.65)
MRI Bone marrow oedema	PsA/PsO	24 (14)/7 (16)	0.88 (0.35 to 2.20)	0.786	0.90 (0.41 to 1.95)
	PsA/OA	24 (14)/34 (71)	0.07 (0.03 to 0.15)	<0.001	0.20 (0.13 to 0.31)
MRI Erosions	PsA/PsO	25 (15)/3 (7)	2.41 (0.69 to 8.37)	0.168	2.20 (0.70 to 6.94)
	PsA/OA	25 (15)/31 (65)	0.10 (0.05 to 0.20)	<0.001	0.23 (0.15 to 0.35)
X-ray Erosions	PsA/PsO	156 (80)/37 (77)	1.16 (0.54 to 2.47)	0.702	1.03 (0.87 to 1.22)
	PsA/OA	156 (80)/52 (100)	n.e.	–	0.80 (0.74 to 0.85)
X-ray Enthesial change	PsA/PsO	167 (85)/38 (80)	1.52 (0.68 to 3.37)	0.309	1.08 (0.92 to 1.26)
	PsA/OA	167 (85)/52 (100)	n.e.	–	0.85 (0.80 to 0.90)
US DIP-joint synovial hypertrophy	PsA/PsO	86 (43)/12 (27)	2.01 (0.98 to 4.13)	0.057	1.58 (0.95 to 2.62)
	PsA/OA	86 (43)/34 (65)	0.40 (0.21 to 0.76)	0.005	0.66 (0.51 to 0.85)
US Doppler signals	PsA/PsO	4 (2)/1 (2)	0.88 (0.10 to 8.05)	0.908	0.88 (0.10 to 7.68)
	PsA/OA	4 (2)/5 (10)	0.20 (0.10 to 0.74)	0.017	0.21 (0.06 to 0.75)
US Erosions	PsA/PsO	24 (12)/1 (2)	5.86 (0.77 to 44.56)	0.087	5.28 (0.73 to 38.00)
	PsA/OA	24 (12)/5 (10)	1.28 (0.46 to 3.54)	0.632	1.25 (0.50 to 3.11)
US New bone formation	PsA/PsO	90 (45)/13 (30)	1.95 (0.96 to 3.95)	0.063	1.52 (0.25 to 2.47)
	PsA/OA	90 (45)/45 (87)	0.13 (0.06 to 0.30)	<0.001	0.52 (0.43 to 0.63)
US Extensor tendon enthesitis	PsA/PsO	85 (43)/17 (39)	1.17 (0.60 to 2.29)	0.638	1.10 (0.73 to 1.65)
	PsA/OA	85 (43)/15 (29)	1.82 (0.94 to 3.54)	0.075	1.48 (0.93 to 2.33)
US Peritendonitis	PsA/PsO	26 (13)/2 (5)	3.14 (0.72 to 13.75)	0.111	2.86 (0.71 to 11.61)
	PsA/OA	26 (13)/4 (8)	1.79 (0.60 to 5.39)	0.298	1.69 (0.62 to 4.63)

*P value for OR calculated by Mantel-Haenszel Common OR Estimate. Bold values are statistical significant $p \leq 0.05$.

DIP, distal interphalangeal; n.e., not estimable; OA, osteoarthritis; PsA, psoriatic arthritis; PsO, skin psoriasis; US, ultrasound.

enthesitis and at least a grade 2 US erosion and US NBF score or grade 2 MRI synovitis, tenosynovitis, erosion score or grade 3 MRI bone marrow oedema.

A high prevalence of US NBF, Doppler and SH were seen in patients with OA of the DIP joints, and these patients also reported the highest 68/66 tender joint score, VAS joint-related pain, and HAQ-DI (table 1). It was surprising that the OA group also exhibited US enthesitis, but it has been proposed that PsA and OA could share a common enthesitis-associated area with microdamage as a common disease driver.³³ It could also reflect that we cannot differentiate capsular hypertrophy and enthesitis with our current imaging resolution as it may look the same on US and MRI. US only revealed subtle differences between the PsA and OA group, but MRI PsAMRIS

and X-ray revealed considerable differences in disease severity in all semiquantitative outcomes. A high prevalence of these findings reduces the risk of PsA (table 3). This opposes the notion that DIP-joint synovitis is more severe in autoimmune processes^{34 35} and could reflect that the OA group does not receive adequate treatment. In the PsA group, these symptoms are likely suppressed as most receive DMARD treatment.

No US Doppler was observed in the flexor or extensor enthesitis in either patient group, and caution should be exhibited because of greater flow from adjacent dorsal branches from lateral digital arteries might obscure any smaller neoangiogenic vessels in the enthesitis. In this context, using a Doppler signal ≤ 2 mm from the bony cortex as a landmark of enthesitis in SpA as suggested in

Outcome Measures in Rheumatology³⁶ may not be reliable for the extensor tendon at the DIP-joint.

Even though DCE-MRI Flow ME*nVOXEL and IRE*nVOXEL proved to have the highest probability of differentiating between PsA versus PsO and PsA versus OA, it did not prove sensitive enough to be of diagnostic use in the current study, but this could be due to the relatively small sample size of OA and PsO patients warranting more extensive studies to study this association in more details. To support the current findings, Schraml *et al*³⁷ also found comparable synovial enhancement between PsA and OA until 15 min postcontrast, where higher values were found in OA. The same group also found a difference between RA and PsA 15 min postcontrast, but a correlation between clinical findings and DCE-MRI only existed in the RA group.³⁸ We did not obtain data 15 min postcontrast because of an inherent overestimation of enhancement of synovitis on static postcontrast enhanced images based on the risk of diffusion of contrast to adjacent extracellular fluid already after 5 min postcontrast injection.³⁹

Strengths

The study benefits from consecutively enrolled patients in outpatient clinics in dermatology and rheumatology comparing PsA and PsO patients already in DMARD treatment, reflecting the diagnostic dilemmas in a clinical setting, thus strengthening the external validity. The imaging assessors were blinded to the diagnose and results from the other findings.

Limitations

A consecutive enrolment strategy resulted in an all-female hand OA group, which might weaken the generalisability of our findings. However, the Framingham Studies showed a higher prevalence of hand OA among women.^{40 41}

A possible limitation is that 82% of PsA and 67% of the PsO patients were in DMARD therapy. This is likely to lower the chance of findings related to inflammatory activity. It may also explain the relatively high prevalence of these findings in the OA group as they are not offered DMARD therapy.

The cross-sectional design limits any conclusions about temporal developments and association over time of the different findings.

CONCLUSIONS

In conclusion, we found that the differentiation between PsA, PsO, and hand OA using US, MRI and X-ray is possible based on the degree of structural involvement using a combination of semiquantitative OMERACT US scores, PsAMRIS score and X-ray score. No imaging variable was a positive predictor for PsA. On the other hand, a high grade of US, MRI and X-ray NBF and MRI bone marrow oedema predicted OA compared with PsA. In demarcating PsA from PsO patients, it is of importance if they present with X-ray enthesitis and a high degree

of US erosions and NBF or MRI synovitis-, tenosynovitis-, erosion score or bone marrow oedema.

Quantitative flow measures in both DCE-MRI and US and US measures of DIP-joint tendon enthesis, nail and nailbed/matrix are of limited value in differentiating between PsA, PsO and OA. X-ray can be used to identify hand OA but not to distinguish between PsA and PsO.

Author affiliations

¹The Parker Institute, Frederiksberg, Denmark

²Department of Rheumatology, Slagelse Hospital, Slagelse, Denmark

³Department of Dermatology, Bispebjerg Hospital, Copenhagen, Denmark

⁴Radiology Department, Guy's and St Thomas' Hospitals NHS Trust, London, UK

⁵University of Leeds Leeds Institute of Rheumatic and Musculoskeletal Medicine, Leeds, UK

⁶Department of Radiology, Bispebjerg Hospital, Copenhagen, Denmark

⁷IAG Image Analysis Group, London, UK

⁸Department of Rheumatology, Aalborg University Hospital, Aalborg, North Denmark Region, Denmark

Acknowledgements We wish to thank René Cordtz at the Department of Clinical Medicine, University of Aalborg, Denmark for proofreading and Line Rustad at the Parker Institute for organising the flow of participants. A huge thanks to Lene Terslev, Hilde Hammer, Heidi Siddle, Ruth Wittoek, Kate Smith, Etienne Qvistgaard, Lene Jensen, Lars Juul and Marion Kortekaas for contributing to the preliminary probe comparison web-survey. A huge thanks to the MRI staff for performing the examinations, with special thanks to Janus Damm Nybing and Frederik Hvid Linden.

Contributors JG-M, MH and LEK act as guarantors and had full access to all the data in the study, takes full responsibility for the integrity of the work and the accuracy of the data analysis and the decision to publish. JG-M, LEK: study concept and design. JG-M, KE, MM, MB: acquisition of data. JG-M, MH and LEK: statistical analysis. All authors: interpretation of data; critical revision of the manuscript for important intellectual content. JG-M: drafting of the manuscript. MH, KE and LEK: study supervision.

Funding The study was funded by an investigator-initiated grant from Novartis, a core grant from The Oak Foundation (OCAY-13-309) and the Minister Erna Hamilton Foundation for Science and Art.

Competing interests JG-M has received speaking fees from AbbVie, NOVARTIS, Eli-Lilly and BK Ultrasound outside the present work. LEK has received fees for speaking and/or consultancy from Pfizer, AbbVie, Amgen, UCB, Celgene, BMS, Biogen, Sanofi, MSD, Novartis, Eli Lilly, Janssen Pharmaceuticals. MH declares to be a member of the scientific advisory board of the Thuasne group. MB has received speaking fees from AbbVie, Novartis, Esote, Eli-Lilly, UCB and is a consultant for Image Analysis Group. LD has received speaking fees from UCB, MSD, Eli-Lilly, Janssen Pharmaceuticals, and a BMS research grant outside the present work. ALT has acted as a consultant for or received honoraria from AbbVie, Eli Lilly, Gilead, Janssen, Novartis, Pfizer, UCB. OK and JD are shareholders and employees at IAG, Image Analysis Group. KE, RJW and MM declare no competing interests.

Patient consent for publication Not applicable.

Ethics approval Signed informed consent was obtained from all participants, and the study was conducted in compliance with the Declaration of Helsinki and approved by the Committee of the Capital Region in Denmark on 25-05-2018, Journal-nr.: H-18006696 and the Danish Data Protection Agency on 04-06-2018 (VD-2018-149, med I-Suite no.: 6392).

Provenance and peer review Not commissioned; externally peer reviewed.

Data availability statement Data are available on reasonable request. Not applicable.

Supplemental material This content has been supplied by the author(s). It has not been vetted by BMJ Publishing Group Limited (BMJ) and may not have been peer-reviewed. Any opinions or recommendations discussed are solely those of the author(s) and are not endorsed by BMJ. BMJ disclaims all liability and responsibility arising from any reliance placed on the content. Where the content includes any translated material, BMJ does not warrant the accuracy and reliability of the translations (including but not limited to local regulations, clinical guidelines, terminology, drug names and drug dosages), and is not responsible for any error and/or omissions arising from translation and adaptation or otherwise.

Open access This is an open access article distributed in accordance with the Creative Commons Attribution Non Commercial (CC BY-NC 4.0) license, which permits others to distribute, remix, adapt, build upon this work non-commercially, and license their derivative works on different terms, provided the original work is properly cited, appropriate credit is given, any changes made indicated, and the use is non-commercial. See: <http://creativecommons.org/licenses/by-nc/4.0/>.

ORCID iDs

Jørgen Guldberg-Møller <http://orcid.org/0000-0002-6521-5825>

Ai Lyn Tan <http://orcid.org/0000-0002-9158-7243>

REFERENCES

- O'Neill T, Silman AJ. Psoriatic arthritis. historical background and epidemiology. *Baillieres Clin Rheumatol* 1994;8:245–61.
- Tillett W, Charlton R, Nightingale A, et al. Interval between onset of psoriasis and psoriatic arthritis comparing the UK clinical practice research Datalink with a hospital-based cohort. *Rheumatology* 2017;56:2109–13.
- Villani AP, Rouzaud M, Sevrain M, et al. Prevalence of undiagnosed psoriatic arthritis among psoriasis patients: systematic review and meta-analysis. *J Am Acad Dermatol* 2015;73:242–8.
- Egeberg A, Kristensen LE, Thyssen JP, et al. Incidence and prevalence of psoriatic arthritis in Denmark: a nationwide register linkage study. *Ann Rheum Dis* 2017;76:1591–7.
- Gladman DD, Antoni C, Mease P, et al. Psoriatic arthritis: epidemiology, clinical features, course, and outcomes. *Ann Rheum Dis* 2005;64 Suppl 2:ii14–17.
- Lee S, Mendelsohn A, Sarnes E. The burden of psoriatic arthritis: a literature review from a global health systems perspective. *P T* 2010;35:680–9.
- Mease PJ. Psoriatic arthritis: update on pathophysiology, assessment and management. *Ann Rheum Dis* 2011;70 Suppl 1:i77–84.
- Taylor W, Gladman D, Helliwell P, et al. Classification criteria for psoriatic arthritis: development of new criteria from a large international study. *Arthritis Rheum* 2006;54:2665–73.
- Coates LC, Helliwell PS. Psoriatic arthritis: state of the art review. *Clin Med* 2017;17:65–70.
- Kristensen LE, Jørgensen TS, Christensen R, et al. Societal costs and patients' experience of health inequities before and after diagnosis of psoriatic arthritis: a Danish cohort study. *Ann Rheum Dis* 2017;76:1495–501.
- Ballegaard C, Højgaard P, Dreyer L, et al. Impact of comorbidities on tumor necrosis factor inhibitor therapy in psoriatic arthritis: a population-based cohort study. *Arthritis Care Res* 2018;70:592–9.
- Wiell C, Szkudlarek M, Hasselquist M, et al. Ultrasonography, magnetic resonance imaging, radiography, and clinical assessment of inflammatory and destructive changes in fingers and toes of patients with psoriatic arthritis. *Arthritis Res Ther* 2007;9:R119.
- Zhang W, Doherty M, Leeb BF. EULAR evidence-based recommendations for the diagnosis of hand osteoarthritis: report of a task force of ESCISIT. *Ann Rheum Dis* 2009.
- Tan AL, Grainger AJ, Tanner SF, et al. A high-resolution magnetic resonance imaging study of distal interphalangeal joint arthropathy in psoriatic arthritis and osteoarthritis: are they the same? *Arthritis Rheum* 2006;54:1328–33.
- Love TJ, Gudjonsson JE, Valdimarsson H, et al. Small joint involvement in psoriatic arthritis is associated with onycholysis: the Reykjavik psoriatic arthritis study. *Scand J Rheumatol* 2010;39:299–302.
- Eder L, Chandran V, Shen H, et al. Incidence of arthritis in a prospective cohort of psoriasis patients. *Arthritis Care Res* 2011;63:619–22.
- Eder L, Law T, Chandran V, et al. Association between environmental factors and onset of psoriatic arthritis in patients with psoriasis. *Arthritis Care Res* 2011;63:1091–7.
- Ogdie A, Weiss P. The epidemiology of psoriatic arthritis. *Rheum Dis Clin North Am* 2015;41:545–68.
- McGonagle D. Enthesitis: an autoinflammatory lesion linking nail and joint involvement in psoriatic disease. *J Eur Acad Dermatol Venereol* 2009;23 Suppl 1:9–13.
- McGonagle D, Tan AL, Benjamin M. The nail as a musculoskeletal appendage—implications for an improved understanding of the link between psoriasis and arthritis. *Dermatology* 2009;218:97–102.
- Acosta-Felquer ML, Ruta S, Rosa J, et al. Ultrasound enthesal abnormalities at the distal interphalangeal joints and clinical nail involvement in patients with psoriasis and psoriatic arthritis, supporting the nail-enthesitis theory. *Semin Arthritis Rheum* 2017;47:338–42.
- Maehima H, Taniguchi T, Watarai A, et al. Evaluation of nail disease in psoriatic arthritis by using a modified nail psoriasis severity score index. *Int J Dermatol* 2010;49:901–6.
- Bossuyt PM, Reitsma JB, Bruns DE. STARD 2015 : an updated list of essential items for. *BMJ Open* 2015;351:1–9.
- Altman R, Alarcón G, Appelrouth D, et al. The American College of rheumatology criteria for the classification and reporting of osteoarthritis of the hand. *Arthritis Rheum* 1990;33:1601–10.
- Bruce B, Fries JF. The health assessment questionnaire (HAQ). *Clin Exp Rheumatol* 2005;23.
- Maksymowych WP, Mallon C, Morrow S, et al. Development and validation of the spondyloarthritis research Consortium of Canada (SPARCC) Enthesitis index. *Ann Rheum Dis* 2009;68:948–53.
- Terslev L, Naredo E, Aegerter P, et al. Scoring ultrasound synovitis in rheumatoid arthritis: a EULAR-OMERACT ultrasound taskforce-Part 2: reliability and application to multiple joints of a standardised consensus-based scoring system. *RMD Open* 2017;3:e000427.
- Ellegaard K, Torp-Pedersen S, Lund H, et al. Quantification of colour Doppler activity in the wrist in patients with rheumatoid arthritis—the reliability of different methods for image selection and evaluation. *Ultraschall Med* 2008;29:393–8.
- Glinatsi D, Bird P, Gandjbakhch F, et al. Validation of the OMERACT psoriatic arthritis magnetic resonance imaging score (PsAMRIS) for the hand and foot in a randomized placebo-controlled trial. *J Rheumatol* 2015;42:2473–9.
- Shrout PE, Fleiss JL. Intraclass correlations: uses in assessing rater reliability. *Psychol Bull* 1979;86:420–8.
- Guidelines CDV. Criteria, and rules of thumb for evaluating Normed and standardized assessment instruments in psychology. *Psychol Assess* 1994;6:284–90.
- Aydin SZ, Castillo-Gallego C, Ash ZR, et al. Ultrasonographic assessment of nail in psoriatic disease shows a link between onychopathy and distal interphalangeal joint extensor tendon enthesopathy. *Dermatology* 2012;225:231–5.
- McGonagle D, Hermann K-GA, Tan AL. Differentiation between osteoarthritis and psoriatic arthritis: implications for pathogenesis and treatment in the biologic therapy era. *Rheumatology* 2015;54:29–38.
- Scanzello CR. Role of low-grade inflammation in osteoarthritis. *Curr Opin Rheumatol* 2017;29:79–85.
- Penatti A, Facciotti F, De Matteis R, et al. Differences in serum and synovial CD4+ T cells and cytokine profiles to stratify patients with inflammatory osteoarthritis and rheumatoid arthritis. *Arthritis Res Ther* 2017;19:103.
- Terslev L, Naredo E, Iagnocco A, et al. Defining enthesitis in spondyloarthritis by ultrasound: results of a Delphi process and of a reliability reading exercise. *Arthritis Care Res* 2014;66:741–8.
- Schraml C, Schwenzer NF, Martirosian P, et al. Assessment of synovitis in erosive osteoarthritis of the hand using DCE-MRI and comparison with that in its major mimic, the psoriatic arthritis. *Acad Radiol* 2011;18:804–9.
- Schwenzer NF, Köttler I, Henes JC, et al. The role of dynamic contrast-enhanced MRI in the differential diagnosis of psoriatic and rheumatoid arthritis. *AJR Am J Roentgenol* 2010;194:715–20.
- Boesen M, Kubassova O, Sudoł-Szopińska I, et al. MR imaging of joint infection and inflammation with emphasis on dynamic contrast-enhanced MR imaging. *PET Clin* 2018;13:523–50.
- Zhang Y, Niu J, Kelly-Hayes M, et al. Prevalence of symptomatic hand osteoarthritis and its impact on functional status among the elderly: the Framingham study. *Am J Epidemiol* 2002;156:1021–7.
- Haugen IK, Englund M, Aliabadi P, et al. Prevalence, incidence and progression of hand osteoarthritis in the general population: the Framingham osteoarthritis study. *Ann Rheum Dis* 2011;70:1581–6.