

Radiographic outcome after maxillary sinus floor augmentation with allogeneic adipose tissue-derived stem cells seeded on deproteinized bovine bone mineral. A randomized controlled experimental study

Starch-Jensen, Thomas; Spin-Neto, Rubens; Veiss-Pedersen, Pernille; Dahlin, Christer; Bruun, Niels Henrik; Fink, Trine

Published in:
Journal of Cranio-Maxillofacial Surgery

DOI (link to publication from Publisher):
[10.1016/j.jcms.2023.05.011](https://doi.org/10.1016/j.jcms.2023.05.011)

Creative Commons License
CC BY 4.0

Publication date:
2023

Document Version
Publisher's PDF, also known as Version of record

[Link to publication from Aalborg University](#)

Citation for published version (APA):

Starch-Jensen, T., Spin-Neto, R., Veiss-Pedersen, P., Dahlin, C., Bruun, N. H., & Fink, T. (2023). Radiographic outcome after maxillary sinus floor augmentation with allogeneic adipose tissue-derived stem cells seeded on deproteinized bovine bone mineral. A randomized controlled experimental study. *Journal of Cranio-Maxillofacial Surgery*, 51(5), 321-331. <https://doi.org/10.1016/j.jcms.2023.05.011>

General rights

Copyright and moral rights for the publications made accessible in the public portal are retained by the authors and/or other copyright owners and it is a condition of accessing publications that users recognise and abide by the legal requirements associated with these rights.

- Users may download and print one copy of any publication from the public portal for the purpose of private study or research.
- You may not further distribute the material or use it for any profit-making activity or commercial gain
- You may freely distribute the URL identifying the publication in the public portal -

Take down policy

If you believe that this document breaches copyright please contact us at vbn@aub.aau.dk providing details, and we will remove access to the work immediately and investigate your claim.

Downloaded from vbn.aau.dk on: December 04, 2025



Radiographic outcome after maxillary sinus floor augmentation with allogeneic adipose tissue-derived stem cells seeded on deproteinized bovine bone mineral. A randomized controlled experimental study

Thomas Starch-Jensen ^{a,*}, Rubens Spin-Neto ^b, Pernille Veiss-Pedersen ^c,
Christer Dahlin ^d, Niels Henrik Bruun ^e, Trine Fink ^f

^a Department of Oral and Maxillofacial Surgery, Aalborg University Hospital and Department of Clinical Medicine, The Faculty of Medicine, Aalborg University, Aalborg, Denmark

^b Department of Dentistry and Oral Health, Section of Oral Radiology, Faculty of Health, Aarhus University, Aarhus, Denmark

^c Department of Radiology, Aalborg University Hospital, Aalborg, Denmark

^d Department of Biomaterials, BIOMATCELL VINN Excellence Center, Institute for Surgical Science, The Sahlgrenska Academy, University of Gothenburg, and Department of Oral and Maxillofacial Surgery, NU-Hospital, Organization Trollhättan, Gothenburg, Sweden

^e Unit of Clinical Biostatistics, Aalborg University Hospital, Aalborg, Denmark

^f Regenerative Medicine Group, Department of Health Science and Technology, The Faculty of Medicine, Aalborg University, Aalborg, Denmark

ARTICLE INFO

Article history:

Paper received 24 March 2023

Received in revised form

1 May 2023

Accepted 21 May 2023

Available online 12 June 2023

Handling Editor: Prof. Emeka Nkenke

Keywords:

Adipose-derived mesenchymal stem cells

Alveolar ridge augmentation

Computed tomography

Maxilla

Maxillary sinus floor augmentation

Radiography

ABSTRACT

The objective was to test the hypothesis of no difference in radiographic outcome after maxillary sinus floor augmentation (MSFA) with allogeneic adipose tissue-derived stem cells (ASCs) seeded on deproteinized bovine bone mineral (DBBM) (test) compared with excipient on DBBM (control). Eighteen minipigs were assigned into three groups of six animals and euthanised after one month (T1), two months (T2), and four months (T3), respectively. Each maxillary sinus was randomly allocated to either test or control with an equal volume of graft. Computed tomography scans (CTs) after MSFA (T0) were compared with CTs after euthanasia to evaluate graft volume (GV) changes and bone density (BD) using three-dimensional measurements and Hounsfield units. GV was larger in test compared with control at T1 ($P = 0.046$), whereas GV was larger in control compared with test at T3 ($P = 0.01$). BD increased from T0 to T1-T3 ($P < 0.001$) with both treatments. Higher BD was observed in control compared with test at T3 ($P = 0.01$), while no significant difference was observed at T1 and T2. Conclusively, the present study demonstrate that allogeneic ASCs seeded on DBBM in conjunction with MSFA seemed not to improve the radiographic outcome compared with excipient on DBBM. However, radiological outcomes need to be supplemented by bone histomorphometry before definitive conclusions can be provided about the beneficial use of allogeneic ASCs seeded on DBBM in conjunction with MSFA compared with DBBM alone.

© 2023 The Authors. Published by Elsevier Ltd on behalf of European Association for Cranio-Maxillo-Facial Surgery. This is an open access article under the CC BY license (<http://creativecommons.org/licenses/by/4.0/>).

1. Introduction

Maxillary sinus floor augmentation (MSFA) applying the lateral window technique is used to increase the alveolar bone height of the posterior maxilla (Esposito et al., 2010; Raghoobar et al., 2019; Starch-Jensen et al., 2018; Starch-Jensen et al., 2018; Starch-Jensen and Jensen, 2017), and autogenous bone is considered the preferred

graft (Sakkar et al., 2017). However, autogenous bone is associated with an unpredictable resorption (Jensen et al., 2012a; Shanbhag et al., 2014), and volumetric stability of the graft represents an important parameter for successful implant treatment outcome (Kirmeier et al., 2008; Shanbhag et al., 2014). Autogenous bone is therefore frequently combined or replaced by xenogeneic bone substitutes that possess low substitution rate to improve the volumetric graft stability (Jensen et al., 2012b; Starch-Jensen et al., 2021). However, xenogeneic bone substitutes contain solely osteoconductive properties and therefore necessitates a prolonged healing period or addition of autogenous bone, growth factors or bioactive proteins to improve the osteoinductive and osteogenic

* Corresponding author. Department of Oral and Maxillofacial Surgery, Aalborg University Hospital, 18-22 Hobrovej, DK-9000, Aalborg, Denmark.

E-mail address: thomas.jensen@rn.dk (T. Starch-Jensen).

graft capacity (Amid et al., 2021; Shanbhag and Shanbhag, 2015). Different ratios of autogenous bone and xenogeneic bone substitutes have previously been used as graft in conjunction with MSFA (Krennmair et al., 2018; Mordenfeld et al., 2014; Schmitt et al., 2015). However, the disputed osteogenic potential of autogenous bone and risk of donor site morbidity have contributed to novel cell-based strategies utilizing undifferentiated stem cells combined with a scaffold to improve the osteogenic potential of composite grafts and diminish patient discomfort (Avila-Ortiz et al., 2016; Eini et al., 2022; Jakobsen et al., 2013; Liang et al., 2017; Miron et al., 2013; Niño-Sandoval et al., 2019; Tabassum et al., 2020; Varshney et al., 2020).

Mesenchymal stem cells are multipotent stromal cells that differentiate into a variety of cell types including osteoblasts and thus facilitating bone regeneration (Niño-Sandoval et al., 2019). Bone marrow-derived mesenchymal stem cells are the most used stem cells in tissue engineering (Eini et al., 2022; Niño-Sandoval et al., 2019). However, the frequency of bone marrow-derived mesenchymal stem cells is rather low, and the cells lose their proliferative as well as their differentiation capacity during cell expansion (Niño-Sandoval et al., 2019). Thus, adipose tissue-derived stem cells (ASCs) have been used increasingly for tissue engineering purposes, since ASCs contain a high cell to volume ratio and proliferate rapidly (Niño-Sandoval et al., 2019). Moreover, ASCs attach rapidly to a scaffold and differentiate toward the osteogenic lineage, which have been revealed in experimental and clinical studies (Eini et al., 2022; Niño-Sandoval et al., 2019; Varshney et al., 2020). However, acquisition of autogenous ASCs are associated with risk of donor site morbidity due to the harvesting procedure. Moreover, the laboratory procedure for cellular isolation and culturing is costly as well as time and labour consuming. Thus, allogeneic ASCs (AASCs) seeded on a scaffold will simplify the procedure and diminish patient discomfort.

Previous studies in rabbits, rats, and dogs have demonstrated bone regeneration in artificial created bone defects with AASCs seeded on scaffolds (Gu et al., 2014; Kang et al., 2014; Liu et al., 2013; Wen et al., 2016), while human studies are missing. However, AASCs seeded on a scaffold in conjunction with MSFA have never previously been investigated. Thus, studies in larger animals and humans assessing clinical, radiographic, and histologic outcomes after MSFA with AASCs is needed. The objective of the study is therefore to test the hypothesis of no difference in radiographic outcome after MSFA with AASCs seeded on deproteinized bovine bone mineral (DBBM) compared with excipient on DBBM in minipigs at different time points.

2. Material and methods

2.1. Ethical considerations

License was obtained from The Danish Experimental Animal Inspectorate, The Danish Veterinary and Food Administration, Ministry of Environment and Food of Denmark, Copenhagen, Denmark (Approval no.: 2020-15-0201-00552). The study was conducted in accordance with institutional and national standards as well as ARRIVE guidelines for animal studies and directive 2010/63/EU.

2.2. Power calculation

Sample size was calculated using [Clincalc.com](http://clincalc.com/stats/samplesize.aspx) (<http://clincalc.com/stats/samplesize.aspx>). A mean normal distributed graft volume (GV) of 170 mm³ with a standard deviation of 15 mm³ between groups were expected. Sample size analysis revealed that six

animals per group was necessary to provide a statistical power of 0.80 with an alpha value of 0.05 and beta of 0.2.

2.3. Allogeneic adipose tissue-derived stem cells

The protocol for acquisition of AASCs from a minipig donor including cellular isolation, culturing, and stem cell attachment to DBBM is based on an unpublished pilot study conducted at The Department of Health Science and Technology, Aalborg University, Aalborg, Denmark.

2.4. Harvesting of adipose tissue

ASCs were obtained from a minipig donor aged 18 months, which was not included in the study. The minipig was positioned in a supine position exposing the abdominal adipose tissue. Under aseptic condition, a small subcutaneous incision was made 5 cm lateral for the ventral midline using diathermy. A tumescent solution containing 100 ml saline solution and 1 ml adrenalin was infiltrated with a multi-perforated cannula with a blunt tip. Liposuction was conducted after 20 min by manual hand-held aspiration using a 20 ml syringe connected to the cannula. Approximately 50 ml adipose tissue was aspirated for stem cell isolation and culturing.

2.5. Cellular isolation and expansion

The laboratory procedure for collecting of ASCs from lipos aspirate has previously been published (Zachar et al., 2011). In brief, the lipos aspirate was washed repeatedly with phosphate buffered saline followed by enzymatic digestion with collagenase. The digest was filtered and centrifuged to obtain a heterogeneous population of cells termed stromal vascular fraction (SVF). The SVF was seeded in T175 cell culture flasks and cultured until confluency in growth medium comprised of α -minimum essential medium supplemented with 10% foetal bovine serum, 100 U/mL penicillin, 0.1 mg/mL streptomycin (all from Invitrogen), and 0.25 μ g/mL amphotericin B (Sigma-Aldrich). During this expansion, the population of cells become homogenous, resulting in a population of nearly 100% ASCs, defined by their co-expression of surface markers CD29, CD44, CD90, and CD105 and absence of marker CD45. Upon confluency, the ASCs were detached by trypsin, loaded into a hollow-fiber bioreactor (Terumo) and expanded in growth media without amphotericin B for 10 days, after which they were harvested. The expansion yielded 500 \times 10⁶ cells that were cryopreserved in aliquots of 35 \times 10⁶ cells in 1 mL cryoprotectant (Cryostor 10, Sigma-Aldrich) and stored in liquid nitrogen until use.

2.6. Randomization

For each aliquot of AASCs (test), an excipient was prepared consisting of 1 mL cryoprotectant supplemented with 5% growth medium (control). The test and control aliquot to be used in each animal were numbered and randomly assigned label A or B. The aliquots were fabricated with identical appearance and quantity. Aliquot A was always applied in the right sinus, whereas aliquot B was applied in the left. The randomization treatment code was secured at cell production facility. Surgeon and assessors were blinded to the randomization until data had been collected.

2.7. Animals

Eighteen adult, female Göttingen minipigs (Ellegaard Göttingen Minipigs A/S, Dalmose, Denmark) were included. During the study, the animals were fed daily with standard laboratory diet (Altromin

9023, Altromin International GmbH, Lage, Germany) and water ad libitum.

The minipigs were assigned into three groups of six animals with different healing periods (I: one month; II: two months; III: four months) (Table 1). Bilateral MSFA was performed in each animal with aliquot of AASCs seeded on DBBM (Creos, xenogain, bovine bone mineral matrix, vival, L, 1.0–2.0, 2 g, Nobel Biocare, Gothenburg, Sweden) or aliquot of excipient on DBBM (Table 2).

2.8. Drug administration

2.8.1. Anesthesia

Anesthesia was induced by an intramuscular injection (IMI) in the neck region with a mixture of zoletil (0.125 ml/kg, Rompun, Bayer Health care AG, Leverkusen, Germany), ketamine (1.6 mg/kg, Ketaminol, Intervet International B.V, Boxmeer, the Netherlands), and butorphanol (0.3 mg/kg, Torbugesic, Fort Dodge Veterinaria S.A., Girona, Spain). A standard straight 5.5-mm orotracheal tube with a cuff (Portex, Kent, UK) was placed and anesthesia was maintained by inhalation anesthesia with 1% sevoflurane (Forene, Abbott GmbH, Wiesbaden, Germany). The animals received a continuous intravenous infusion through an ear vein of a physiological saline solution containing propofol 10 mg/ml (4 mg/kg) and fentanyl 50 µm/ml (0.03 µm/kg) during surgery.

2.8.2. Antibiotics

An IMI with Curamox® Prolongatum Vet, Amoxicillinum Trihydricum, 150 mg/ml (0.1 ml/kg, Meda AS, Allerød, Denmark), was given 1 h before surgery. Peroral Imacillin 50 mg/ml (14 ml/kg,

Meda AS, Allerød, Denmark) was given twice a day on the third and fourth day postoperatively.

2.8.3. Analgesic

An IMI with Metacam®, 5 mg/ml (2 ml/25 kg, Boehringer Ingelheim 3 A/S), was given preoperatively. Metacam®, oral suspension for pigs, 15 mg/ml (2.7 ml/100 kg, Boehringer Ingelheim Denmark A/S), was given peroral for 5 days postoperatively.

2.9. Maxillary sinus floor augmentation

The surgical procedure has previously been described in detail (Jensen et al., 2012b). In brief, the lateral sinus wall was exposed through a sagittal skin incision below the lower eyelid (Fig. 1). A bony window to the sinus was prepared maintaining an intact Schneiderian membrane. The window and membrane were elevated from the original sinus floor and displaced dorsocranially. The sinus wall posterior to the created window was reduced to a thickness of 5 mm before an implant bed was prepared according to manufacturer's surgical protocol. A straight implant (NobelParallel Conical Connection TiUltra RP, 4.0 × 15 mm, Nobel Biocare, Gothenburg, Sweden) was inserted with cover screw. Aliquot A or B was mixed with DBBM in different cups before the graft was applied. The entire graft was packed around the implant surface protruding into the sinus securing identical quantities of the graft within each sinus. The window to the sinus was covered by a collagen barrier membrane (Creos, xenoprotect membrane 30 × 40 mm, Nobel Biocare, Gothenburg, Sweden). Periosteum and skin were sutured in layers with Vicryl 3–0 and Nylon 3–0 (Ethicon, Norderstedt, Germany).

2.10. Euthanasia and perfusion

The animals were deeply anaesthetized. The left and right common carotid arteries were exposed and dissected through a midline neck incision from the thyroid cartilage to just above the suprasternal notch. The carotid arteries were cannulated with a catheter (Avanti, Cordia Cashel, Ireland) and perfused with 1000 ml neutral-buffered Ringer solution (2500 ml/min) followed by 1000 ml neutral-buffered formaldehyde solution (2500 ml/min).

2.11. Radiographic assessment

The method used for three-dimensional radiographic assessment of graft volume (GV) changes has previously been described in detail (Starch-Jensen et al., 2023). GV and bone density (BD) were assessed by computed tomography scans (CTs) obtained immediately after MSFA (T0) and compared with CTs obtained after euthanasia at one month (T1), two months (T2), and four months (T3), respectively. The minipigs were placed in a supine position with a horizontal occlusal plane, before spiral multislice CTs (Discovery CT750 HD, General Electric Company, United States) were acquired with 0.625 mm axial section thickness and 0.312 mm distance between the slices. The CTs were coded to provide blinding for the examiner. To ensure standardized image generation and spatial orientation, all image datasets were uniformly oriented in all dimensions using computer software (Syngo.via, Siemens Healthcare, Erlangen, Germany).

GV was produced as DICOM-based data sets using software (OnDemand 3DApplication, version 10, Cybermed, Seoul, South Korea). GV at T0 was used as reference and compared with GV at T1, T2, and T3, respectively. The registration was conducted by an automatized detection of hundreds of virtual landmarks in the volumes, which was manually adjusted based on visible (i.e., anatomical) landmarks. The axial, coronal, and sagittal planes were

Table 1
Age and weight of the minipigs within each group.

Minipig group:	I	II	III	Mean
Number of minipigs:	6	6	6	
Age at surgery (months):	18.0 ± 0.0	19.8 ± 1.0	19.3 ± 1.0	19.0 ± 1.1
Weight preoperatively (kg):	39.1 ± 5.2	37.2 ± 1.7	32.2 ± 1.5	36.2 ± 4.3
Weight at euthanasia (kg)	39.9 ± 5.3	38.0 ± 2.8	37.1 ± 3.3	38.3 ± 1.4

Table 2
Procedure for systematic random selection of graft.

Minipig no.:	Right maxillary sinus	Left maxillary sinus
Group I:		
1.	Control	Test
2.	Test	Control
3.	Control	Test
4.	Control	Test
5.	Test	Control
6.	Test	Control
Group II:		
1.	Control	Test
2.	Test	Control
3.	Test	Control
4.	Control	Test
5.	Control	Test
6.	Test	Control
Group III:		
1.	Test	Control
2.	Control	Test
3.	Control	Test
4.	Test	Control
5.	Test	Control
6.	Control	Test

Control: deproteinized bovine bone mineral.

Test: allogeneic adipose tissue-derived stem cells seeded on deproteinized bovine bone mineral.

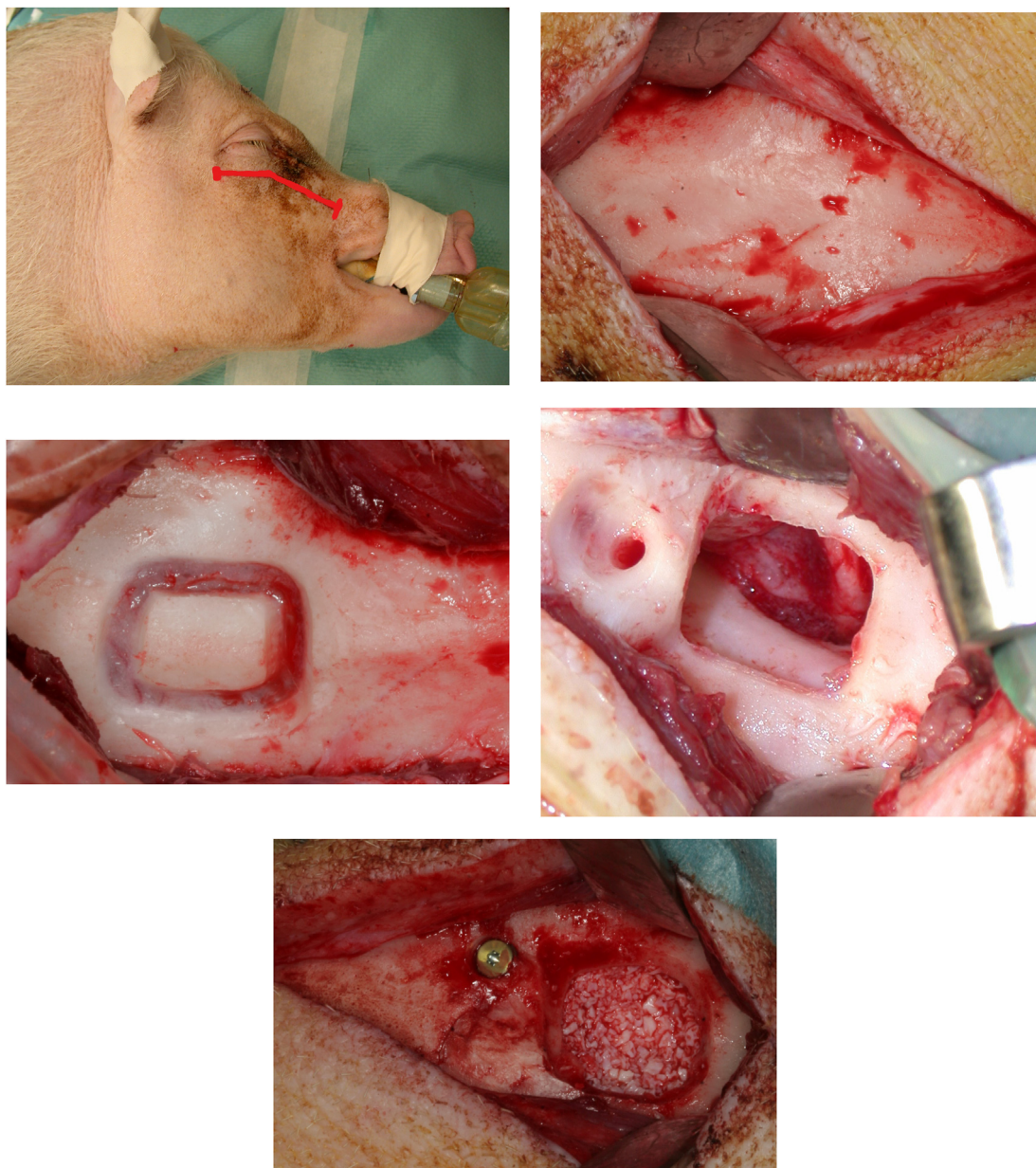


Fig. 1. Maxillary sinus floor augmentation. A, B: The lateral sinus wall was exposed through a sagittal skin incision below the lower eyelid. C: A window to the maxillary sinus was created. D: The bony window and the Schneiderian membrane was carefully elevated before the maxillary sinus wall posterior to the created window was reduced to a thickness of 5 mm and an implant bed was successively prepared. E: An implant was inserted and mounted with a cover screw before the selected graft was packed around the implant surface protruding into the maxillary sinus.

adjusted based on the centre of the longitudinal implant axis at T0 and fit to the augmented site, as seen in the CTs at T1, T2, and T3, respectively. In the sequence, cross-sections (i.e., coronal sections), with a thickness of 1 mm, and representative of the augmented area, were generated. This registration process ensured the images represented the same region, based on the same orientation and reconstruction planes. Number of cross-sections varied among sites depending on individual size, but the same number of sections was generated and evaluated for each area. Each selected cross-sectional image of sinus was assessed by one trained observer (TSJ) by manually tracing the augmented area, in mm^2 (Fig. 2). The GV, in mm^3 , on the sites was calculated by adding the measured

areas of each selected cross-section image, in each period of evaluation. Volumetric GV changes in mm^3 were finally calculated by subtraction of the measured volumes at T1, T2, and T3 from the T0 volume.

BD of the graft within the sinus was determined by Hounsfield unit (HU). The different planes corresponding to the centre of the longitudinal implant axis were adjusted on the two sets of CTs. Five sequential axial CT images on each side of the longitudinal implant axis were selected. A region of interest ($15 \times 15 \text{ mm}$) was randomly outlined on each CTs image within the periphery of the graft and original border of the sinus without interfering with the implant (Fig. 3).

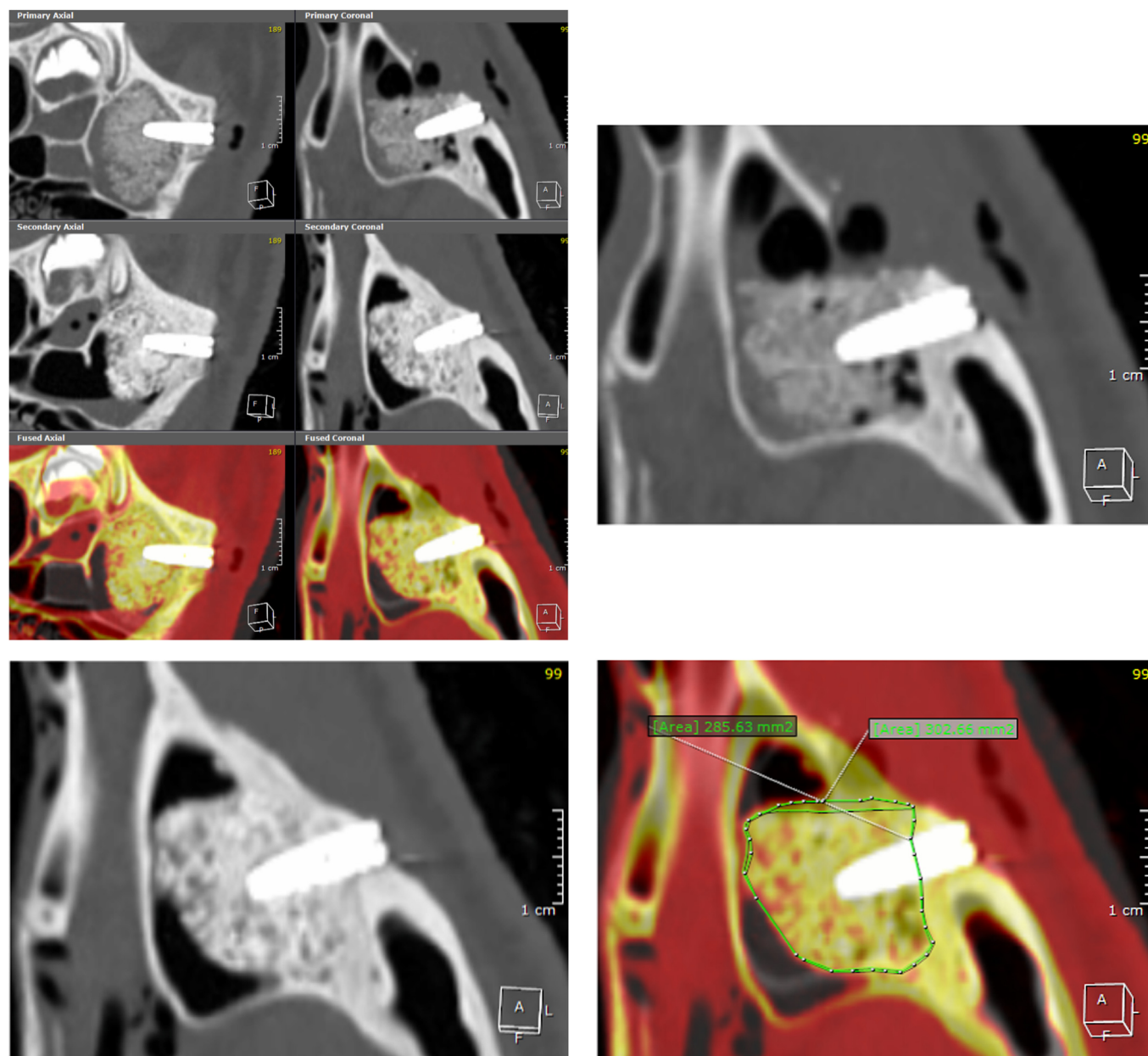


Fig. 2. Graft volume changes assessed by computed tomography scan. A: Computed tomography scan (CTs) obtained immediately after maxillary sinus floor augmentation are superimposed with CTs taken after euthanasia. B: CTs obtained immediately after maxillary sinus floor augmentation is adjusted based on the center of the longitudinal implant axis. C: Corresponding CTs at euthanasia. D: The original border of the maxillary sinus and circumference of the augmented area are outlined before the volume of the graft is calculated, at the different time periods.

2.12. Data management and statistical analysis

Data management and analysis was conducted using STATA (Data analysis and statistical software, version 17, StataCorp P, Texas, USA). All procedures were performed twice on two randomly selected animals in each group. The intraobserver reliability were estimated using the intraclass correlation coefficient from a two-way random-effects model. Mean and 95% confidence intervals (CI) of means were reported for three-dimensional radiographic assessment of GV changes and BD using random intercept regression models. Level of significance was 0.05.

3. Results

Healing was uneventful in all animals. Intra- and postoperative complications are outlined in Table 3. Accidental perforation of the Schneiderian membrane occurred in 10 sinuses (test: 4; control: 6). The perforation was covered by a collagen barrier membrane before the graft was applied as planned. Perforation of the membrane seemed not to influence the GV, although radiographic signs of infection with graft dissolution was observed in both sinuses of one animal having bilateral sinus membrane perforation. Thus, the minipig was omitted from the study.

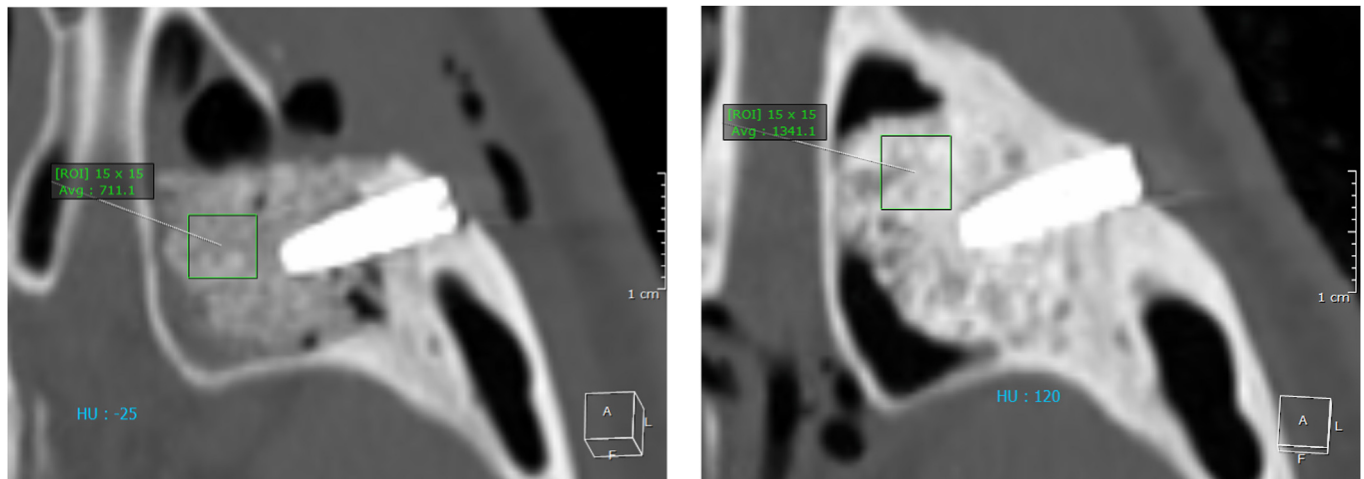


Fig. 3. Bone density of the graft determined by Hounsfield units. A: Bone density is determined by Hounsfield units on computed tomography scans obtained immediately after maxillary sinus floor augmentation within a randomly selected region of interest. B: Identical measurements are performed on computed tomography scans obtained at euthanasia.

Table 3
Frequency of intra- and postoperative complications.

Minipig no.:	Right maxillary sinus	Left maxillary sinus
Group I:		
1.		PSM
2.		
3.	PSM/infection ^a	PSM/infection ^a
4.		
5.		PSM
6.		
Group II:		
1.	PSM	
2.		
3.	PSM	
4.	Signs of graft dissolution	
5.		
6.		PSM
Group III:		
1.		
2.	PSM	PSM
3.		
4.		PSM
5.		
6.		

PSM: perforation of the Schneiderian membrane.

^a Omitted from the study.

Table 4
Graft volume.

Volume of the grafting material (mm ³)	MSFA with DBBM mean [95% CI]	P-value	MSFA with allogeneic ASCs seeded on DBBM mean [95% CI]	P-value
T0	179.57 [170.96; 188.18]		183.80 [175.19; 192.41]	0.294
T1	173.27 [160.65; 185.90]		187.18 [174.56; 199.81]	0.046 ^a
T2	189.60 [176.98; 202.22]		186.39 [173.77; 199.02]	0.646
T3	197.52 [184.89; 210.14]		177.81 [165.18; 190.43]	0.005 ^a
Volumetric changes (mm³)				
T0-T1	-6.29 [-18.44; 5.85]	0.310	3.39 [-8.76; 15.53]	0.585
T0-T2	10.03 [-2.11; 22.18]	0.105	2.60 [-9.55; 14.74]	0.675
T0-T3	17.95 [5.80; 30.09]	0.004 ^a	-5.99 [-18.14; 6.15]	0.334

ASCs, adipose tissue-derived stem cells; DBBM, deproteinized bovine bone mineral; MSFA, maxillary sinus floor augmentation; SD, standard deviation.

T0, immediately after maxillary sinus floor augmentation; T1, one month; T2, two months; T3, four months.

^a Statistically significant.

3.1. Graft volume

Mean GV at T0-T3 is outlined in Table 4 and Fig. 4.

3.1.1. AASCs seeded on DBBM (test)

GV was marginally increased from T0 to T1 ($P = 0.585$) and T0 to T2 ($P = 0.675$), while a none significantly decrease was observed from T0 to T3 ($P = 0.334$). GV changes from T0 to T1 were 3.39 mm³ [95% CI: 8.76; 15.53], T0 to T2 were 2.60 mm³ [95% CI: 9.55; 14.74], and T0 to T3 were -5.99 mm³ [95% CI: 18.14; 6.15], respectively.

3.1.2. Excipient on DBBM (control)

GV was significant increased from T0 to T3 ($P = 0.004$), while no significant difference was observed from T0 to T1 ($P = 0.310$) or T0 to T2 ($P = 0.105$). GV changes from T0-T1 were -6.29 mm³ [95% CI: 18.44; 5.85], T0-T2 were 10.03 mm³ [95% CI: 2.11; 22.18], and T0-T3 were 17.95 mm³ [95% CI: 5.80; 30.09], respectively.

A significant larger GV was observed in test compared with control at T1 ($P = 0.046$), while GV was significantly larger in control compared with test at T3 ($P = 0.005$). No significant difference between the two treatment modalities was observed at T0 ($P = 0.294$) and T2 ($P = 0.646$) (Fig. 5).

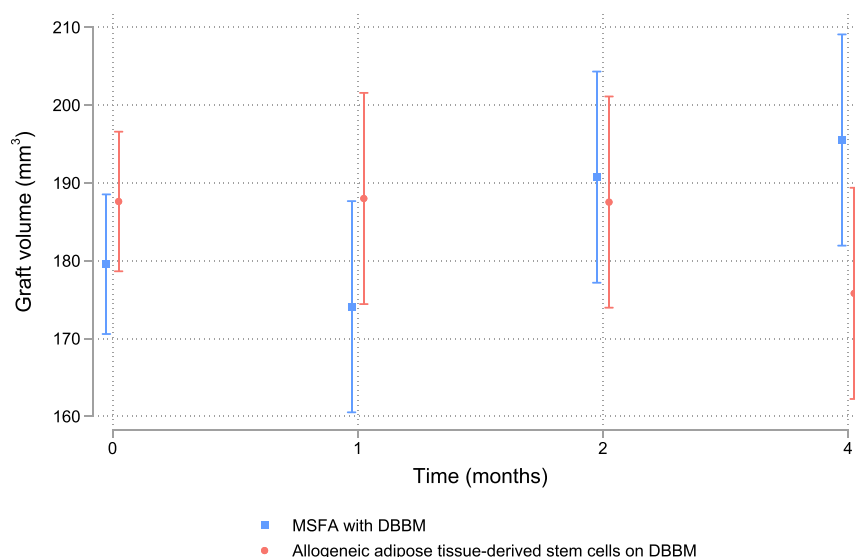


Fig. 4. Graft volume changes. Graft volume changes (mm³) at T1, T2 and T3 compared with T0.

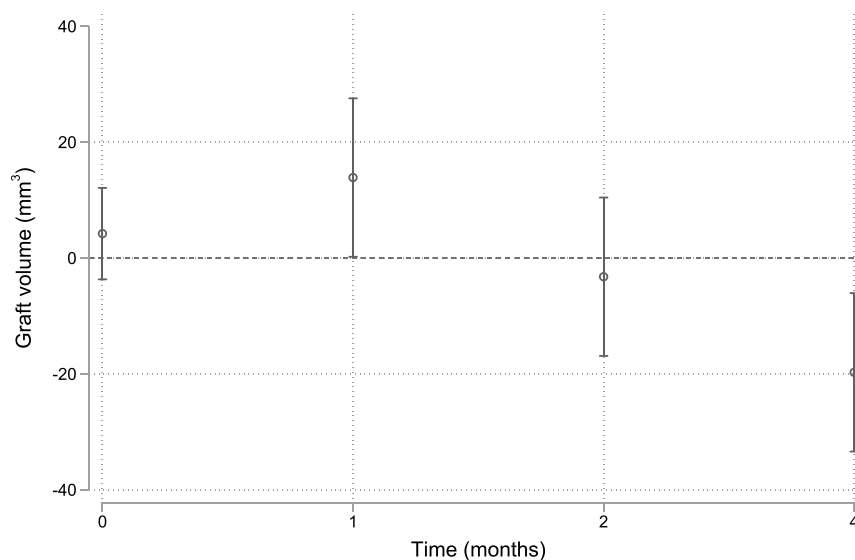


Fig. 5. Graft volume changes between the two treatment modalities.

Graft volume was significant larger with allogeneic adipose tissue-derived stem cells seeded on deproteinized bovine bone mineral compared with sham seeded on deproteinized bovine bone mineral at T1 ($P = 0.046$), while the graft volume was significant larger with sham seeded on deproteinized bovine bone mineral compared with allogeneic adipose tissue-derived stem cells seeded on deproteinized bovine bone mineral at T3 ($P = 0.005$). No significant difference between the two treatment modalities was observed at T0 ($P = 0.294$) and T2 ($P = 0.646$).

3.2. Bone density

Mean BD at T0-T3 is outlined in Table 5 and Fig. 6.

3.2.1. AASCs seeded on DBBM (test)

BD increased from T0 to T1 ($P < 0.001$), T0 to T2 ($P < 0.001$), and T0 to T3 ($P < 0.001$), respectively. Changes in HU values from T0 to T1 were 207.87 [95% CI:105.61; 310.13], T0 to T2 were 235.27 [95% CI:140.59; 329.95], and T0 to T3 were 438.74 [95% CI:344.07; 533.42].

3.2.2. Excipient on DBBM (control)

BD increased from T0 to T1 ($P < 0.001$), T0 to T2 ($P < 0.001$), and T0 to T3 ($P < 0.001$), respectively. Changes in HU values from T0-T1 were 276.69 [95% CI:174.78; 378.61], T0 to T2 were 332.60 [95% CI:238.30; 426.90], and T0 to T3 were 590.39 [95% CI:496.09; 684.69].

A significant higher BD was observed in control compared with test at T3 ($P = 0.014$), while no significant difference was observed at T0 ($P = 0.636$), T1 ($P = 0.377$), and T2 ($P = 0.138$) (Fig. 7).

Table 5
Bone density.

Bone density (Hounsfield units)	MSFA with DBBM mean [95% CI]	P-value	MSFA with allogeneic ASCs seeded on DBBM mean [95% CI]	P-value
T0	761.97 [705.79; 818.14]		777.34 [719.77; 834.91]	0.636
T1	1038.66 [940.47; 1136.85]		985.21 [887.02; 1083.40]	0.377
T2	1094.57 [1004.31; 1184.83]		1012.61 [922.35; 1102.87]	0.138
T3	1352.36 [1262.10; 1442.62]		1216.09 [1125.83; 1306.35]	0.014*
<i>Changes in bone density</i>				
T0-T1	276.69 [174.78; 378.61]	P < 0.001*	207.87 [105.61; 310.13]	P < 0.001*
T0-T2	332.60 [238.30; 426.90]	P < 0.001*	235.27 [140.59; 329.95]	P < 0.001*
T0-T3	590.39 [496.09; 684.69]	P < 0.001*	438.74 [344.07; 533.42]	P < 0.001*

ASCs, adipose tissue-derived stem cells; DBBM, deproteinized bovine bone mineral; MSFA, maxillary sinus floor augmentation.

T0, immediately after maxillary sinus floor augmentation; T1, one month; T2, two months; T3, four months.

*Statistically significant.

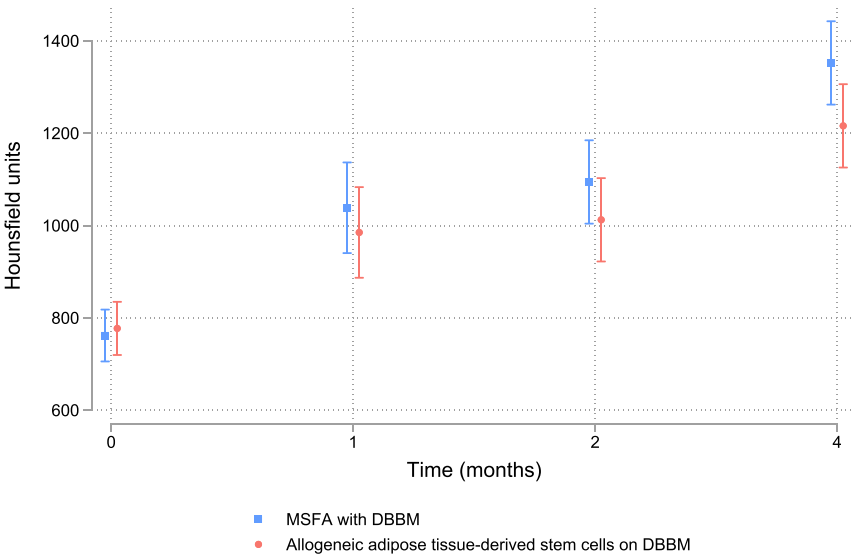


Fig. 6. Bone density.
Bone density changes (Hounsfield units) at T1, T2 and T3 compared with T0.

3.3. Intraobserver reliability

Intraobserver reliability for GV and BD was 0.98 (95% CI:0.96; 0.99), indicating almost perfect reliability. Bland-Altman plot revealed no relation between the differences of the repeated estimates against the corresponding means (Figs. 8 and 9).

4. Discussion

Results of this study indicates that AASCs seeded on DBBM seemed not to improve the radiographic outcome in conjunction with MSFA. However, the difference was diminutive and probably without clinical relevance. Conclusions drawn from the results of this study should therefore be cautiously interpreted and further studies involving bone histomorphometry are needed to supplement these radiological outcomes.

The present study contains various limitations. However, the main limitation was the small but statistically representative number of animals in each group. Moreover, translation of data derived from experimental animal studies to clinical recommendations in humans should be associated with several reservations due mainly to obvious genetic variations. Hence, the result of the present study needs to be verified in human studies.

Allogeneic and xenogeneic biomaterials comprise risk of eliciting an immune response or disease transmission (Keane and Badylak, 2015). Previous studies in rabbits and rats have demonstrated bone regeneration in artificial created bone defects using AASCs seeded on an osteoconductive scaffold without triggering an immune response as evaluated by flow cytometry (Gu et al., 2014; Liu et al., 2013; Wen et al., 2016). In the present study, all animals gained in weight without signs of a systemic immune response involving infection, fever, or lack of appetite.

Minipigs have previously been used for radiographical and histological assessment of bone regeneration in conjunction with MSFA due to its anatomical and physiological similarities (Jensen et al., 2012b; Mardas et al., 2014; Štembírek et al., 2012). However, the volumetric graft stability within the maxillary sinus of a minipig is influenced by a different physiology involving increased dynamic pressure changes during respiration and grunt. A previous study in minipigs have revealed that the volumetric graft stability was significantly influenced by the ratio of autogenous bone and DBBM disclosing a gradually reduced shrinkage with higher proportions of DBBM, while GV was reduced by 65% when autogenous bone was used alone (Jensen et al., 2012b). Xenogeneic bone substitutes are characterized by a low substitution rate (Shanbhag et al., 2014), which enables the biomaterial to withstand

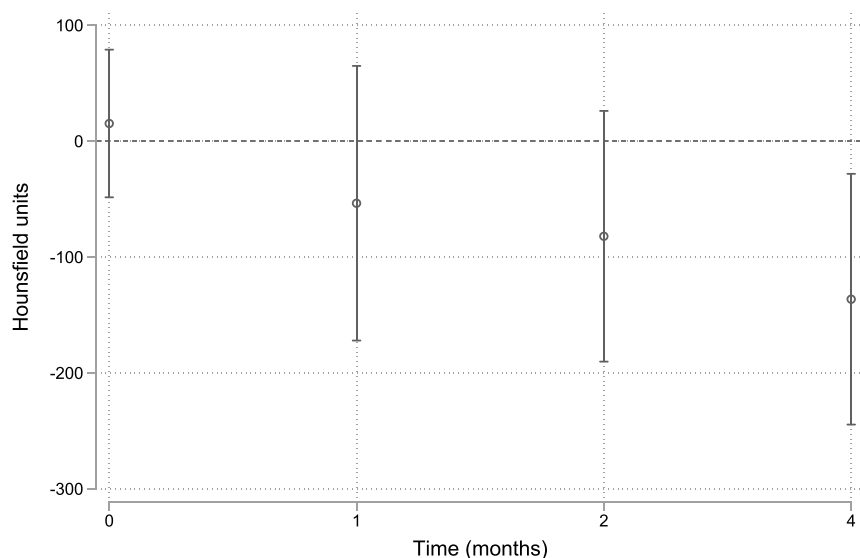


Fig. 7. Bone density changes between the two treatment modalities.

Bone density was significant higher with sham seeded on deproteinized bovine bone mineral compared with allogeneic adipose tissue-derived stem cells seeded on deproteinized bovine bone mineral at T3 ($P = 0.014$), while no significant difference was observed at T0 ($P = 0.636$), T1 ($P = 0.377$), and T2 ($P = 0.138$).

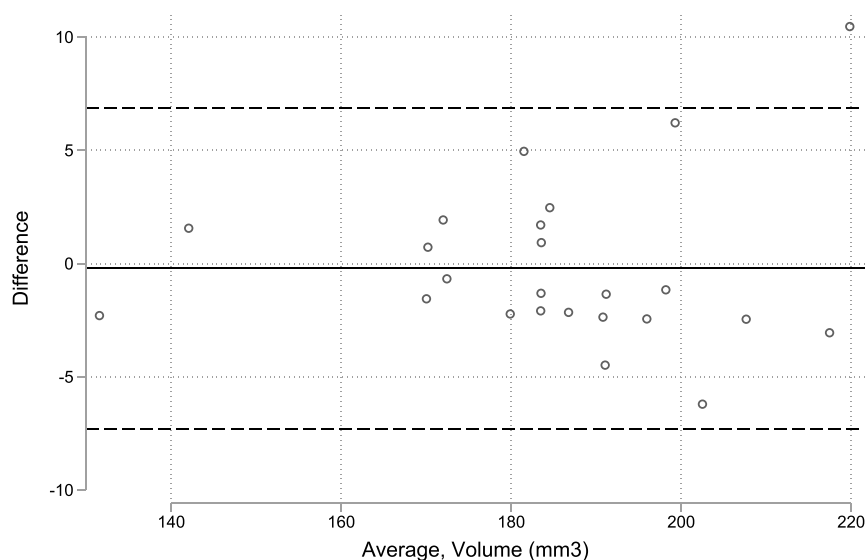


Fig. 8. Intraobserver reliability for assessment of graft volume.

Bland-Altman plot revealed no relation between the differences of the repeated estimates against the corresponding means.

increased dynamic pressure within the sinus of a minipig. In the present study, diminutive GV changes were revealed with both treatment modalities indicating substantial volumetric graft stability.

Volumetric graft stability is prerequisite for successful long-term implant treatment outcome in conjunction with MSFA (Kirmeier et al., 2008; Shanbhag et al., 2014). Various parameters influence GV changes including the used graft, anatomical characteristic of the sinus, radiographic assessment method, and residual bone height (Klijn et al., 2012; Zhang et al., 2019). Radiographic assessment of GV changes after MSFA are often conducted by two-

dimensional linear measurements (Jensen et al., 2012b; Shanbhag et al., 2014). However, the graft within the maxillary sinus is an inhomogeneous and three-dimensional anisotropic structure. Three-dimensional radiographic methods should therefore be applied for assessment of GV changes. Several computer software systems have previously been used for three-dimensional assessment of GV changes in conjunction with MSFA disclosing excellent intraobserver reliability (Cosso et al., 2014; Gorla et al., 2015). In the present study, OnDemand 3D Application was used for assessment of GV changes revealing almost perfect intraobserver reliability,

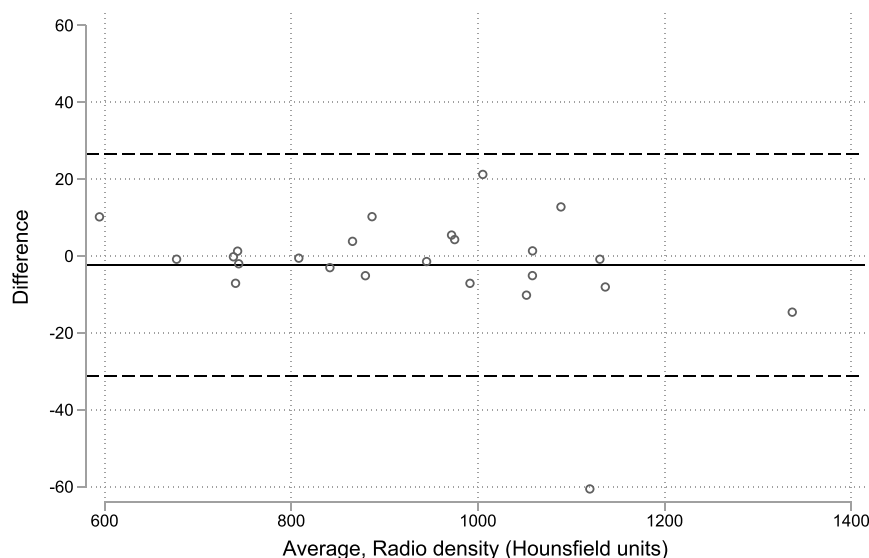


Fig. 9. Intraobserver reliability for assessment of bone density.

Bland-Altman plot revealed no relation between the differences of the repeated estimates against the corresponding means.

which is in accordance with previous publications (Kim et al., 2013; Ohe et al., 2016).

HU quantification on CTs is a valid radiographic method to determine the rate of ossification. Previous clinical and animal studies have reported a positive correlation between BD at the implant recipient site and primary implant stability as evaluated by CTs (Marquezan et al., 2012; Salimov et al., 2014). In the present study, a significantly increase in BD was observed with both treatment modalities at different time periods implying improved graft ossification within the sinus over time. However, the BD was higher with excipient on DBBM indicating that AASCs seeded on DBBM seemed not to improve graft ossification in conjunction with MSFA.

Conclusion

Within the limitations of the study it seems that allogeneic ASCs seeded on DBBM in conjunction with MSFA seemed not to improve the radiographic outcome compared with excipient on DBBM. However, radiological outcomes need to be supplemented by bone histomorphometry before definitive conclusions can be provided about the beneficial use of allogeneic ASCs seeded on DBBM in conjunction with MSFA compared with DBBM alone.

Funding

The study was supported by grants from Svend Andersen Fonden, Aalborg, Denmark and Tandlægeforeningens Forskningsudvalg (FORSKU), Copenhagen, Denmark. Implants, surgical drill kit, cover screws, healing abutments, Creos bone substitute and Creos collagen barrier membrane were kindly provided by NobelBiocare, Gothenburg, Sweden.

Ethical approval and consent to participate

License was obtained from The Danish Experimental Animal Inspectorate, The Danish Veterinary and Food Administration, Ministry of Environment and Food of Denmark, Copenhagen,

Denmark (Approval no.: 2020-15-0201-00552). The study was conducted in accordance with institutional and national standards as well as ARRIVE guidelines for animal studies and directive 2010/63/EU.

Consent for publication

Not relevant.

Availability of supporting data

Study protocol and all data are available from the corresponding author on reasonable request.

Authors' contributions

All authors have contributed substantial to the conception and design of the study, drafting the article, and approval of the final version to be submitted. The statistical analysis was conducted mainly by Niels Henrik Bruun, Unit of Clinical Biostatistics, Aalborg University Hospital, Aalborg, Denmark. Conception and design of study: TSJ, RSN, CD, NHB, and TF. Surgery: TSJ. Acquisition of data: TSJ, RSN, PVP, NHB, and TF. Analysis of data: TSJ, RSN, PVP, CD, NHB, and TF. Drafting of article: TSJ, Critical revision: RSN, PVP, CD, NHB, and TF. Final approval of manuscript: TSJ, RSN, PVP, CD, NHB, and TF.

Authors' information (optional)

Not applicable.

Declaration of competing interest

All authors declare no financial interest or conflict of interest, either directly or indirectly, in the products or information listed in the article.

Acknowledgements

The authors are deeply indebted to Dr Benedict Kjærgaard, Mr Torben Madsen, Ms Pernille Mikkelsen, and Ms Helle Christiansen for excellent handling of the animals. Moreover, the authors wish to thank Ms Lene Boelsmand Henriksen, Ms Liselotte Bruun Bierregaard and Ms Julie Vitenson for valuable assistance during the surgical procedures, and Dr Qiuyue Peng and Ms Lisa Engen for assistance with cell expansion and flow cytometric analysis.

Appendix A. Supplementary data

Supplementary data to this article can be found online at <https://doi.org/10.1016/j.jcms.2023.05.011>.

References

- Amid, R., Kheiri, A., Kheiri, L., Kadkhodazadeh, M., Ekhlasmandkermani, M., 2021. Structural and chemical features of xenograft bone substitutes: a systematic review of in vitro studies. *Biotechnol. Appl. Biochem.* 68, 1432–1452.
- Avila-Ortiz, G., Bartold, P.M., Giannobile, W., Katagiri, W., Nares, S., Rios, H., Spagnoli, D., Wikesjö, U.M., 2016. Biologics and cell therapy tissue engineering approaches for the management of the edentulous maxilla: a systematic review. *Int. J. Oral Maxillofac. Implants* 31 (Suppl. 1), s121–s164.
- Cosso, M.G., de Brito Jr., R.B., Piattelli, A., Shibli, J.A., Zenóbio, E.G., 2014. Volumetric dimensional changes of autogenous bone and the mixture of hydroxyapatite and autogenous bone graft in humans maxillary sinus augmentation. A multislice tomographic study. *Clin. Oral Implants Res.* 25, 1251–1256.
- Eini, E., Ghaemi, A., Rahim, F., 2022. Bone using stem cells for maxillofacial bone disorders: a systematic review and meta-analysis. *Adv. Exp. Med. Biol.* (Online ahead of print).
- Esposito, M., Grusovin, M.G., Rees, J., Karasoulos, D., Felice, P., Alissa, R., Worthington, H., Coulthard, P., 2010. Effectiveness of sinus lift procedures for dental implant rehabilitation: a Cochrane systematic review. *Eur. J. Oral Implant.* 3, 7–26.
- Gorla, L.F., Spin-Neto, R., Boos, F.B., Pereira Rdos, S., Garcia-Junior, I.R., Hochuli-Vieira, E., 2015. Use of autogenous bone and beta-tricalcium phosphate in maxillary sinus lifting: a prospective, randomized, volumetric computed tomography study. *Int. J. Oral Maxillofac. Surg.* 44, 1486–1491.
- Gu, H., Xiong, Z., Yin, X., Li, B., Mei, N., Li, G., Wang, C., 2014. Bone regeneration in a rabbit ulna defect model: use of allogeneic adipose-derived stem cells with low immunogenicity. *Cell Tissue Res.* 358, 453–464.
- Jakobsen, C., Sørensen, J.A., Kassem, M., Thygesen, T.H., 2013. Mesenchymal stem cells in oral reconstructive surgery: a systematic review of the literature. *J. Oral Rehabil.* 40, 693–706.
- Jensen, T., Schou, S., Stavropoulos, A., Terheyden, H., Holmstrup, P., 2012a. Maxillary sinus floor augmentation with Bio-Oss or Bio-Oss mixed with autogenous bone as graft: a systematic review. *Clin. Oral Implants Res.* 23, 263–273.
- Jensen, T., Schou, S., Svendsen, P.A., Forman, J.L., Gundersen, H.J., Terheyden, H., Holmstrup, P., 2012b. Volumetric changes of the graft after maxillary sinus floor augmentation with Bio-Oss and autogenous bone in different ratios. A radiographic study in minipigs. *Clin. Oral Implants Res.* 23, 902–910.
- Kang, S.H., Chung, Y.G., Oh, I.H., Kim, Y.S., Min, K.O., Chung, J.Y., 2014. Bone regeneration potential of allogeneic or autogenic mesenchymal stem cells loaded onto cancellous bone granules in a rabbit radial defect model. *Cell Tissue Res.* 355, 81–88.
- Keane, T.J., Badylak, S.F., 2015. The host response to allogeneic and xenogeneic biological scaffold materials. *J. Tissue Eng Regen Med* 9, 504–511.
- Klijn, R.J., van den Beucken, J.J., Bronkhorst, E.M., Berge, S.J., Meijer, G.J., Jansen, J.A., 2012. Predictive value of ridge dimensions on autologous bone graft resorption in staged maxillary sinus augmentation surgery using Cone-Beam CT. *Clin. Oral Implants Res.* 23, 409–415.
- Kim, E.S., Moon, S.Y., Kim, S.G., Park, H.C., Oh, J.S., 2013. Three-dimensional volumetric analysis after sinus grafts. *Implant Dent.* 22, 170–174.
- Kirmeier, R., Payer, M., Wehrschuetz, M., Jakse, N., Platzer, S., Lorenzoni, M., 2008. Evaluation of three-dimensional changes after sinus floor augmentation with different grafting materials. *Clin. Oral Implants Res.* 19, 366–372.
- Krennmair, S., Weinländer, M., Malek, M., Forstner, T., Krennmair, G., Stimmelmayer, M., 2018. Clinical outcome of implants placed in staged maxillary sinus augmentation using bovine bone mineral mixed with autogenous bone at three different ratios: a 5-year prospective follow-up study. *Int. J. Oral Maxillofac. Implants* 33, 1351–1361.
- Liang, C., Lin, X., Wang, S.L., Guo, L.H., Wang, X.Y., Li, J., 2017. Osteogenic potential of three different autogenous bone particles harvested during implant surgery. *Oral Dis.* 23, 1099–1108.
- Liu, G., Zhang, Y., Liu, B., Sun, J., Li, W., Cui, L., 2013. Bone regeneration in a canine cranial model using allogeneic adipose derived stem cells and coral scaffold. *Biomaterials* 34, 2655–2664.
- Mardas, N., Dereka, X., Donos, N., Dard, M., 2014. Experimental model for bone regeneration in oral and cranio-maxillo-facial surgery. *J. Invest. Surg.* 27, 32–49.
- Marquezan, M., Osório, A., Sant'Anna, E., Souza, M.M., Maia, L., 2012. Does bone mineral density influence the primary stability of dental implants? A systematic review. *Clin. Oral Implants Res.* 23, 767–774.
- Miron, R.J., Gruber, R., Hedbom, E., Saulacic, N., Zhang, Y., Sculean, A., Bosshardt, D.D., Buser, D., 2013. Impact of bone harvesting techniques on cell viability and the release of growth factors of autografts. *Clin. Implant Dent. Relat. Res.* 15, 481–489.
- Mordenfeld, A., Albrektsson, T., Hallman, M., 2014. A 10-year clinical and radiographic study of implants placed after maxillary sinus floor augmentation with an 80:20 mixture of deproteinized bovine bone and autogenous bone. *Clin. Implant Dent. Relat. Res.* 16, 435–446.
- Niño-Sandoval, T.C., Vasconcelos, B.C., D Moraes, S.L., A Lemos, C.A., Pellizzer, E.P., 2019. Efficacy of stem cells in maxillary sinus floor augmentation: systematic review and meta-analysis. *Int. J. Oral Maxillofac. Surg.* 48, 1355–1366.
- Ohe, J.Y., Kim, G.T., Lee, J.W., Al Nawas, B., Jung, J., Kwon, Y.D., 2016. Volume stability of hydroxyapatite and β -tricalcium phosphate biphasic bone graft material in maxillary sinus floor elevation: a radiographic study using 3D cone beam computed tomography. *Clin. Oral Implants Res.* 27, 348–353.
- Raghoebar, G.M., Onclin, P., Boven, G.C., Vissink, A., Meijer, H.J.A., 2019. Long-term effectiveness of maxillary sinus floor augmentation: a systematic review and meta-analysis. *J. Clin. Periodontol.* 46 (Suppl. 21), 307–318.
- Sakkas, A., Wilde, F., Heufelder, M., Winter, K., Schramm, A., 2017. Autogenous bone grafts in oral implantology—is it still a “gold standard”? A consecutive review of 279 patients with 456 clinical procedures. *Int. J. Implant Dent* 3, 23.
- Salimov, F., Tatli, U., Kürkcü, M., Akoçlan, M., Oztunç, H., Kurtoglu, C., 2014. Evaluation of relationship between preoperative bone density values derived from cone beam computed tomography and implant stability parameters: a clinical study. *Clin. Oral Implants Res.* 25, 1016–1021.
- Schmitt, C.M., Moest, T., Lutz, R., Neukam, F.W., Schlegel, K.A., 2015. Anorganic bovine bone (ABB) vs. autologous bone (AB) plus ABB in maxillary sinus grafting. A prospective non-randomized clinical and histomorphometrical trial. *Clin. Oral Implants Res.* 26, 1043–1050.
- Shanbhag, S., Shanbhag, V., Stavropoulos, A., 2014. Volume changes of maxillary sinus augmentations over time: a systematic review. *Int. J. Oral Maxillofac. Implants* 29, 881–892.
- Shanbhag, S., Shanbhag, V., 2015. Clinical applications of cell-based approaches in alveolar bone augmentation: a systematic review. *Clin. Implant Dent. Relat. Res.* 17 (Suppl. 1), e17–e34.
- Starch-Jensen, T., Jensen, J.D., 2017. Maxillary sinus floor augmentation: a review of selected treatment modalities. *J. Oral Maxillofac. Res.* 8, e3.
- Starch-Jensen, T., Aludden, H., Hallman, M., Dahlin, C., Christensen, A.E., Mordenfeld, A., 2018. A systematic review and meta-analysis of long-term studies (five or more years) assessing maxillary sinus floor augmentation. *Int. J. Oral Maxillofac. Surg.* 47, 103–116.
- Starch-Jensen, T., Deluiz, D., Vitenson, J., Bruun, N.H., Tinoco, E.M.B., 2021. Maxillary sinus floor augmentation with autogenous bone graft compared with a composite grafting material or bone substitute alone: a systematic review and meta-analysis assessing volumetric stability of the grafting material. *J. Oral Maxillofac. Res.* 12, e1.
- Starch-Jensen, T., Bruun, N.H., Spin-Neto, R., 2023. Endo-sinus bone gain following osteotome-mediated sinus floor elevation with Bio-Oss collagen compared with no grafting material. A one-year randomized controlled trial. *Int. J. Oral Maxillofac. Surg.* (online ahead of print).
- Štembirek, J., Kyllar, M., Putnová, I., Stehlik, L., Buchtová, M., 2012. The pig as an experimental model for clinical craniofacial research. *Lab. Anim* 46, 269–279.
- Tabassum, A., Wismeijer, D., Hogervorst, J., Tahmaseb, A., 2020. Comparison of proliferation and differentiation of human osteoblast-like cells harvested during implant osteotomy preparation using two different drilling protocols. *Int. J. Oral Maxillofac. Implants* 35, 141–149.
- Varshney, S., Dwivedi, A., Pandey, V., 2020. Efficacy of autologous stem cells for bone regeneration during endosseous dental implants insertion - a systematic review of human studies. *J. Oral. Biol. Craniofac. Res.* 10, 347–355.
- Wen, C., Yan, H., Fu, S., Qian, Y., Wang, D., Wang, C., 2016. Allogeneic adipose-derived stem cells regenerate bone in a critical-sized ulna segmental defect. *Exp. Biol. Med.* 241, 1401–1409.
- Zachar, V., Rasmussen, J.G., Fink, T., 2011. Isolation and growth of adipose tissue-derived stem cells. *Methods Mol. Biol.* 698, 37–49.
- Zhang, L., Si, M., Shi, J., Yang, G., Shi, Y., 2019. Evaluation of three-dimensional contraction of the volume of grafts after staged augmentation of the sinus floor, and an analysis of influential factors. *Br. J. Oral Maxillofac. Surg.* 57, 323–329.