

Scrotal Paget's Disease Associated With Human Epidermal Growth Factor Receptor 2-Overexpressing Metastatic Apocrine Carcinoma With Complete Response to Paclitaxel, Trastuzumab, and Pertuzumab

Nowicka-Matus, Kinga; Salkus, Giedrius; Sønderkær, Mads; Søkilde Pedersen, Inge; Ernst, Anja; Kubik, Magdalena; Takacs-Szabo, Zsuzsanna; Ladekarl, Morten

Published in:
JCO Precision Oncology

DOI (link to publication from Publisher):
[10.1200/PO.23.00173](https://doi.org/10.1200/PO.23.00173)

Creative Commons License
CC BY-NC-ND 4.0

Publication date:
2023

Document Version
Publisher's PDF, also known as Version of record

[Link to publication from Aalborg University](#)

Citation for published version (APA):

Nowicka-Matus, K., Salkus, G., Sønderkær, M., Søkilde Pedersen, I., Ernst, A., Kubik, M., Takacs-Szabo, Z., & Ladekarl, M. (2023). Scrotal Paget's Disease Associated With Human Epidermal Growth Factor Receptor 2-Overexpressing Metastatic Apocrine Carcinoma With Complete Response to Paclitaxel, Trastuzumab, and Pertuzumab. *JCO Precision Oncology*, 7, Article e2300173. <https://doi.org/10.1200/PO.23.00173>

General rights

Copyright and moral rights for the publications made accessible in the public portal are retained by the authors and/or other copyright owners and it is a condition of accessing publications that users recognise and abide by the legal requirements associated with these rights.





- Users may download and print one copy of any publication from the public portal for the purpose of private study or research.
- You may not further distribute the material or use it for any profit-making activity or commercial gain
- You may freely distribute the URL identifying the publication in the public portal -

Take down policy

If you believe that this document breaches copyright please contact us at vbn@aub.aau.dk providing details, and we will remove access to the work immediately and investigate your claim.

Downloaded from vbn.aau.dk on: December 04, 2025

6 Scrotal Paget's Disease Associated With Human Epidermal Growth Factor Receptor 2–Overexpressing Metastatic Apocrine Carcinoma With Complete Response to Paclitaxel, Trastuzumab, and Pertuzumab

Kinga Nowicka-Matus, MD¹ ; Giedrius Salkus, MD, PhD²; Mads Sønderkær, MSci, PhD³; Inge Søkilde Pedersen, MSci, PhD^{3,4} ; Anja Ernst, MSci³ ; Magdalena Kubik, MD⁵; Zsuzsanna Takacs-Szabo, MD⁶; and Morten Ladekarl, MD, DMSc^{1,4} 

DOI <https://doi.org/10.1200/PO.23.00173>

ACCOMPANYING CONTENT

Appendix

Accepted July 13, 2023

Published August 18, 2023

JCO Precis Oncol 7:e2300173

© 2023 by American Society of
Clinical Oncology

Creative Commons Attribution
Non-Commercial No Derivatives
4.0 License

INTRODUCTION

Paget's disease is a malignant condition localized within the epidermis and was first described affecting breast nipple or areola in 1874 by Sir James Paget.¹ The first report of extramammary Paget's disease was made by Crocker² in 1889, who noticed similar lesions on scrotum and penis. In contrast to mammary Paget's disease, in which approximately 90% of cases are associated with underlying breast cancer, only 7%–40% of extramammary cases have associated underlying malignancy.³

Extramammary Paget's disease may be associated with cutaneous apocrine carcinoma,^{4–6} a rare type of sweat glands neoplasm usually localized in the axillary or anogenital regions.⁷ The estimated incidence rate ranges from 0.05 to 0.17 per one million per year.⁸ Metastatic cases pose diagnostic and therapeutic challenges because of the disease's rarity and lack of evidence-based treatments.⁹ Case reports have demonstrated clinical benefit for some chemotherapeutic agents^{10,11} and immune checkpoint inhibitors.^{12,13} Tumors may show overexpression of human epidermal growth factor receptor 2 (HER2/ERBB2),^{14,15} estrogen or androgen receptors,^{9,16} providing possibilities of targeted treatment.

We report on a male patient with scrotal Paget's disease with associated malignant apocrine features and primary metastatic disease who responded very well to treatment with paclitaxel in combination with anti-HER2 humanized monoclonal antibodies, trastuzumab and pertuzumab. Reviewing the literature on similar cases, we find a clear role for targeted treatment in these rare patients.

An informed consent from the patient and his spouse was obtained for publication of this case report.

CASE DESCRIPTION

A 65-year-old, previously healthy man with an Eastern Cooperative Oncology Group Performance Status of 0 (ECOG PS 0) presented with an erythematous, ulcerative, and painful area at the scrotal skin and palpable lymph nodes in the left groin. An ¹⁸F-fluorodeoxyglucose (¹⁸F-FDG) positron emission tomography-computed tomography (PET/CT) scan showed bilateral FDG-avid, enlarged inguinal and iliac lymph nodes and FDG uptake in the 6th cervical vertebrae, with a bone metastasis confirmed by magnetic resonance imaging (MRI). A punch biopsy from the scrotum (Fig 1) showed Paget's disease involving the epidermis and sweat ducts with invasive foci of carcinoma in the dermis. Histologic features and the receptor profile (androgen receptors) were highly suggestive of apocrine carcinoma. Tumor cells showed expression of cytokeratin (CK) 7 and gross cystic disease fluid protein 15. There were no expressions of estrogen receptors, progesterone receptors, nor CK5. HER2 immunostaining was strongly positive (3+).

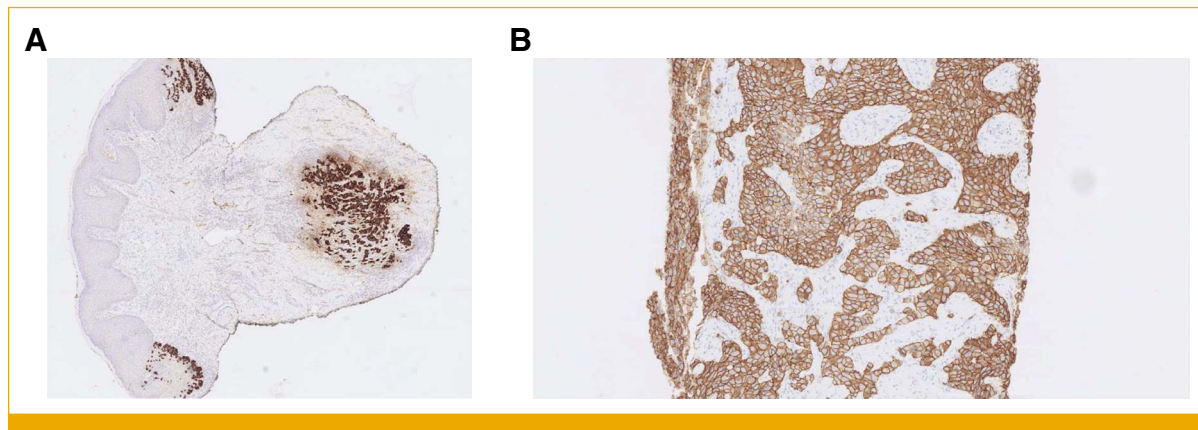


FIG 1. (A) Punch biopsy from the scrotum: foci of Paget's disease in the epidermis and invasive carcinoma in the dermis, highlighted by the stain for cytokeratin 7, 2.5 \times . (B) Diffusely strong membranous stain for HER2; needle core biopsy from the inguinal metastasis, 10 \times . HER2, human epidermal growth factor receptor 2.

Metastasis was confirmed by a needle core biopsy from the left inguinal lymph node. The patient was included in an in-house precision medicine program, and fresh tissue from the left inguinal lymph node was used to perform genomic profiling. A paired tumor/normal whole-exome sequencing (WES) analysis for detection of somatic single-nucleotide variations (SNVs), copy number variations (CNVs), and additional fusion gene detection using mRNAseq as previously described was performed.¹⁷ Three clinically relevant alterations were detected by genomic profiling: an *ERBB2*-amplification, a pathogenic *TP53* mutation, and a likely pathogenic *SETD2* mutation (Table 1). The tumor was microsatellite stable, and tumor mutational burden was low (four mutations/Mb).

After discussion of the case at the national molecular tumor board and a review of literature, the patient was offered first-line treatment with once a week paclitaxel (80 mg/m²) combined with trastuzumab (8 mg/kg loading dose, afterward 6 mg/kg) and pertuzumab (840 mg initially, 420 mg following series) once every third week, similar to a regimen used for treatment of metastatic HER2-positive breast cancer.¹⁸ After three cycles, a CT scan showed complete regression of enlarged lymph nodes and sclerosing of the 6th cervical vertebrae. On visual inspection, the tumor area on the scrotum had decreased dramatically in size, and the patient no longer experienced pain. Paclitaxel was

discontinued after six cycles because of grade 2 (common terminology criteria for adverse event version 5) nail changes, fatigue, peripheral neuropathy, and a grade 3 infection (erysipelas) requiring hospitalization. The patient continued treatment with trastuzumab and pertuzumab for 9 months with good tolerability. After nine cycles of first-line treatment, a complete response (CR) was obtained, both on visual inspection and by an FDG-PET/CT scan. Photographs of the scrotal skin lesion and PET scans obtained during treatment are shown in Figures 2 and 3, respectively, whereas sections of CT scans are shown in Appendix Figure A1.

Fourteen months after treatment initiation and 7 months after achieving CR, while the HER-2 treatment was ongoing, the patient was admitted to the neurologic department because of hemiparesis and dysarthria. Multiple, bilateral brain metastases were disclosed by MRI. The treatment with trastuzumab and pertuzumab was withheld. High-dose steroids and whole brain irradiation (30 Gy/10 fractions) were given followed by re-exposure to trastuzumab as a single drug once every third week. After 6 months of treatment with trastuzumab, brain metastases progressed, and treatment was changed to trastuzumab-emtansine (TDM-1), 3.6 mg/kg every third week. However, the patient's neurologic symptoms and general condition worsened, and treatment was aborted after 42 days. The patient succumbed without evidence of extracerebral progression

TABLE 1. Clinically Relevant Somatic Genetic Alterations Detected in Tumor/Normal WES Genomic Profiling

Gene	Type	Alteration	Location	VAF	Copy Number	Refseq ID	COSMIC ID
<i>TP53</i>	Splicing	p.? (c.376-2A>G)	Intron 4	0.27	NA	NM_000546.5	COSV52689235
<i>SETD2</i>	Stop gain	p.Gln2292* (c.6874C>T)	Exon 15	0.22	NA	NM_014159.6	COSV57447206
<i>ERBB2</i>	Whole gene amplification				11	NM_004448.4	NA

NOTE. p.? signifies that it is unknown how the protein sequence is affected.

Abbreviations: COSMIC ID, catalogue of somatic mutations in cancer identifier; NA, not analyzed; VAF, variant allele frequency; WES, whole exome sequencing.

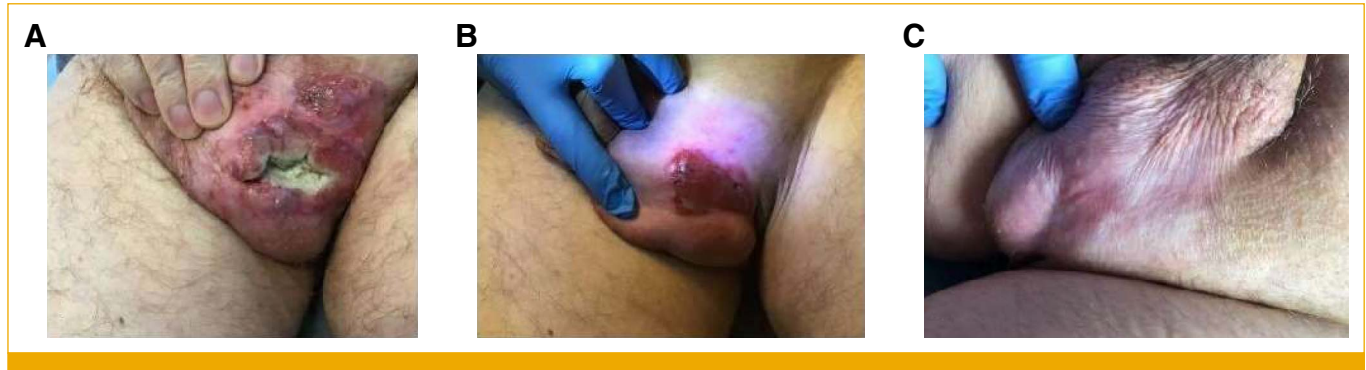

FIG 2. Affected skin area on patient's scrotum (A) at baseline, (B) after three cycles of treatment, and (C) after nine cycles.

3 months after initiation of TDM-1 and 23 months after first-line treatment initiation.

Circulating tumor DNA (ctDNA) analysis was performed on 10 mL of blood samples drawn in collection tubes (Streck, La Vista, NE) at baseline and during treatment for comparison with the clinical course. All analyses were performed after the patient's death. ctDNA was extracted using the QIAasymphony Virus/pathogen Midi Kit (Qiagen, Hilden, Germany). The TruSight Oncology 500 assay (Illumina, San Diego, CA) was used for library preparation. 2×150 -bp paired-end sequencing was performed on a NovaSeq 6000 (Illumina), producing a minimum of $900 \times$ coverage of the targeted regions. Data analysis was performed using the TruSight Oncology 500 v2.2 Local App. As shown in Appendix Figure A2, all three clinically relevant variants found in tumor tissue at baseline were also detected by the ctDNA analysis, with three-fold changes in *ERBB2* and variant

allele frequencies of approximately 15%. In all eight samples drawn after treatment initiation, starting at day 62 at the first evaluation by imaging and ending at day 510, 2.7 months after CNS progression, SNV variants could only be detected at very low allele frequencies ($<1\%$). The fold changes of *ERBB2* dropped to around 5%, thus not high enough to detect the *ERBB2* amplification. A transient, minor increase was observed at day 125, colliding with the patient's admission because of erysipelas.

DISCUSSION

Besides breast and gastroesophageal adenocarcinomas, HER2 overexpression occurs in a small percentage of common neoplasms, including bladder¹⁹ and colorectal²⁰ cancers, and with higher frequency in some rare cancer entities, such as carcinomas of salivary glands.²¹ Increasing evidence suggests that HER2-targeted treatment may be

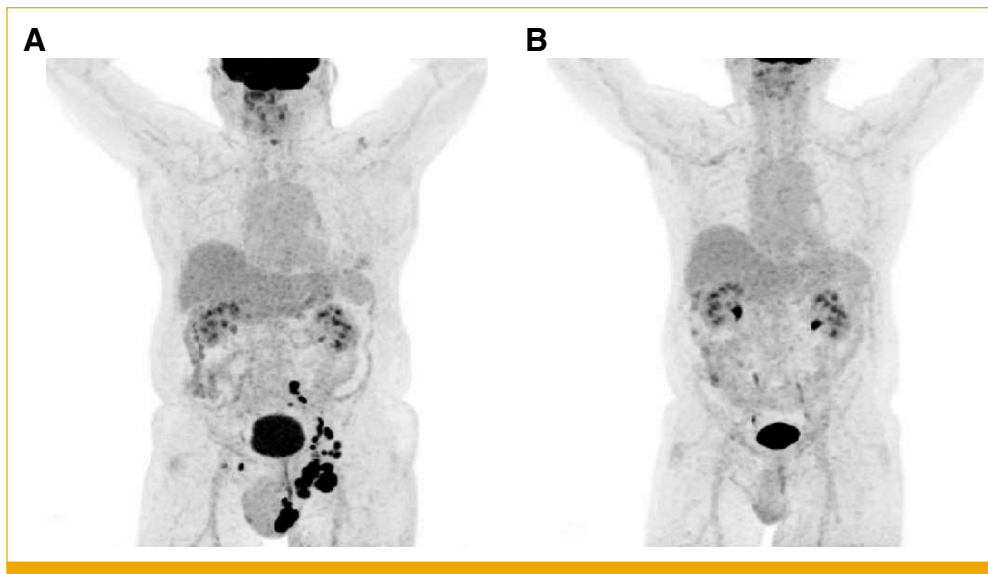


FIG 3. FDG-PET scans (A) at baseline, showing diffuse FDG uptake on the left side of scrotum, in multiple inguinal, iliac, and paraaortic lymph nodes, and in sixth cervical vertebra. (B) After nine cycles of treatment, showing a complete metabolic response. FDG-PET, fluorodeoxyglucose-positron emission tomography.

TABLE 2. Results of HER2-Targeted Treatment of HER2-Positive Extramammary Paget's Disease or Cutaneous Apocrine Carcinoma

Diagnosis (primary site)	HER2/ <i>ERBB2</i> -Status	Treatment	Response	Time to Progression
Recurrent EMPD, met. to lymph nodes, lung and liver (labia major) ²⁶	HER2-IHC 3+	Trastuzumab once every third week	Near CR	NR (>12.5 months)
Recurrent EMPD, met. to lymph nodes and bones (scrotum) ²⁷	HER2-IHC 3+	Trastuzumab once every third week	Near CR	NR (>12 months)
Recurrent EMPD, local recurrence (vulva and perianal area) ²⁸	HER2-IHC 3+	Trastuzumab once a month	PR	NR (>14 months)
Metastatic AC, met. to lymph nodes, bone, and liver (scrotum) ¹⁶	HER2-IHC 3+; <i>ERBB2</i> amp.; <i>ERBB2</i> ^{S3010F} mut.	Carboplatin + gemcitabine; leuprolide + trastuzumab (sequence not stated)	PD	NR
Metastatic EMPD, met. to lymph nodes (vulva) ²⁹	HER2-IHC+	Trastuzumab weekly -> trastuzumab + paclitaxel once a week	PR	NR (>13 months)
Recurrent EMPD, local recurrence, and met. to lymph nodes (scrotum) ³⁰	HER2-IHC+	Trastuzumab once a week + docetaxel once a month, later exchanged with paclitaxel once a week CNS radiotherapy and second-line low-dose cisplatin and 5-FU	Near CR SD	6 months (PD in CNS only) NR (approximately 6 months)
Recurrent EMPD, met. to lymph nodes, vagina, and perineum (vulva) ³¹	HER2-IHC+	Trastuzumab + paclitaxel once a week	PR	NR (>30 months)
Locally advanced AC, met. to axillary lymph nodes (chest wall) ¹⁵	HER2-IHC+	Pertuzumab + trastuzumab + docetaxel once every third week -> surgery + high-dose radiotherapy -> trastuzumab once every third week	CR	NR (>16 months)
Recurrent AC, met. to lymph nodes and liver (scalp) ¹⁴	HER2-IHC 3+	Trastuzumab once a week second-line lapatinib + capecitabine	CR CR	7 months NR (>10 months)
Recurrent EMPD, met. to lymph nodes and lung (scrotum) ³²	<i>ERBB2</i> ^{S310F} mut.; HER2-IHC 2+; <i>ERBB2</i> not amp. HER2-IHC 3+ <i>ERBB3</i> amp.	Lapatinib second-line trastuzumab + carboplatin once every third week Third-line afatinib	PD PR ND	NR approximately 7.5 months <1 months
Locally advanced EMPD, met. to inguinal lymph nodes (perineal and perianal regions) ³³	HER2-IHC 3+; <i>ERBB2</i> amp.	Metronomic capecitabine second-line carboplatin + paclitaxel + trastuzumab once every third week -> trastuzumab once every third week Third-line metronomic vinorelbine + trastuzumab once every third week	SD PR ND	4 months approximately 36.5 months 6 months
Primary metastatic EMPD, met. to lymph nodes and bone (scrotum; current case)	HER2-IHC 3+; <i>ERBB2</i> amp.	Carboplatin + paclitaxel + trastuzumab + pertuzumab once every third week -> pertuzumab + trastuzumab once every third week Second-line trastuzumab emtansine	CR ND	14 months (PD in CNS only) 1.5 months

Abbreviations: AC, apocrine carcinoma; amp., amplification; CR, complete response; EMPD, extramammary Paget's disease; IHC, immunohistochemistry; met., metastases; mut, mutation; ND, not determined; NR, not reported; PD, progressive disease; PR, partial response; SD, stable disease.

used in a tissue-agnostic manner,²¹ but validated, predictive assays of HER2 immunostains have not been established in rarer cancer types, and assessment of *ERBB2* copy numbers may be more feasible as it is not dependent on subjective scoring of immunostains by variable scoring systems dependent on the tissue type.^{21,22} *ERBB2* copy number changes in consecutive ctDNA samples may furthermore reflect treatment response,²³ and mechanisms of resistance may be disclosed by sequencing.²⁴ In our case, the molecular findings in biopsies and blood at baseline were concordant, and ctDNA dropped as a reflection of reduced tumor burden. However, recurrence in the brain was not detectable by a rise in ctDNA, which is in agreement with a recent study of patients with breast cancer in which ctDNA reflected systemic disease, but did not seem to capture DNA shed from CNS.²⁵

Results of HER2-targeted treatment of advanced cutaneous apocrine carcinoma or extramammary Paget's disease have

been reported in a few previous cases, summarized in Table 2.

Although publication bias is probable, the response rate is very high, including a number of durable and complete responders. The single published, nonresponding case was a patient with simultaneous HER2 overexpression/amplification and a mutation in *ERBB2* exon 8 pS310F¹⁶ that may cause resistance to trastuzumab and pertuzumab.³⁴

In conclusion, HER2-targeted treatment with pertuzumab and trastuzumab combined with once a week paclitaxel may be an efficient first-line treatment option for patients with HER2-positive, metastatic cutaneous apocrine carcinoma. Patients are at risk of developing brain metastases,^{31,35} even in the absence of extracerebral progression.³⁰ ctDNA is useful for monitoring of response to systemic therapy, but not for diagnosis of isolated CNS relapse.

AFFILIATIONS

¹Department of Oncology and Clinical Cancer Research Center, Aalborg University Hospital, Aalborg, Denmark

²Department of Pathology, Aalborg University Hospital, Aalborg, Denmark

³Department of Molecular Diagnostic and Clinical Cancer Research Center, Aalborg University Hospital, Aalborg, Denmark

⁴Department of Clinical Medicine, Aalborg University, Aalborg, Denmark

⁵Department of Nuclear Medicine, Aalborg University Hospital, Aalborg, Denmark

⁶Department of Radiology, Aalborg University Hospital, Aalborg, Denmark

CORRESPONDING AUTHOR

Kinga Nowicka-Matus, MD, Department of Oncology and Clinical Cancer Research Center, Aalborg University Hospital, Hobrovej 18-21, 9000 Aalborg, Denmark; e-mail: kinia_doc@hotmail.com.

SUPPORT

H.E. & N.C. Brogaards Legat til Kræftforskningens Fremme supported the preparation of this manuscript by an unrestricted grant. The recipient of the grant is Prof Morten Ladekarl.

AUTHOR CONTRIBUTIONS

Conception and design: Kinga Nowicka-Matus, Morten Ladekarl

Financial support: Morten Ladekarl

Administrative support: Morten Ladekarl

Provision of study materials or patients: Kinga Nowicka-Matus, Morten Ladekarl

Collection and assembly of data: All authors

Data analysis and interpretation: All authors

Manuscript writing: All authors

Final approval of manuscript: All authors

Accountable for all aspects of the work: All authors

AUTHORS' DISCLOSURES OF POTENTIAL CONFLICTS OF INTEREST

The following represents disclosure information provided by authors of this manuscript. All relationships are considered compensated unless otherwise noted. Relationships are self-held unless noted.

I = Immediate Family Member, Inst = My Institution. Relationships may not relate to the subject matter of this manuscript. For more information about ASCO's conflict of interest policy, please refer to www.asco.org/rwc or ascopubs.org/po/author-center.

Open Payments is a public database containing information reported by companies about payments made to US-licensed physicians ([Open Payments](http://OpenPayments.org)).

Morten Ladekarl

Research Funding: Scandion Oncology (Inst)

No other potential conflicts of interest were reported.

REFERENCES

1. Paget J: On the disease of the mammary gland areola preceding cancer of the mammary gland. *St Barts Hosp Rep* 10:87-89, 1874
2. Crocker H: Paget's disease affecting the scrotum and penis. *Trans Pathol Soc Lond* 40:187-191, 1889
3. Chanda JJ: Extramammary Paget's disease: Prognosis and relationship to internal malignancy. *J Am Acad Dermatol* 13:1009-1014, 1985
4. Seo SH, Shin DH, Sung HW: Apocrine carcinoma of the groin possibly associated with extramammary Paget's disease. *Ann Dermatol* 23:519, 2011
5. Bowling JCR, Powles A, Nasiri N, et al: Spontaneous regression of extramammary Paget's disease after excision of primary apocrine carcinoma, in an immunosuppressed patient. *Br J Dermatol* 153:676-677, 2005
6. Pascual JC, Perez-Ramos M, Devesa JP, et al: Extramammary Paget's disease of the groin with underlying carcinoma and fatal outcome. *Clin Exp Dermatol* 33:595-598, 2008
7. Cham PMH, Niehans GA, Foman N, et al: Primary cutaneous apocrine carcinoma presenting as carcinoma erysiplodes. *Br J Dermatol* 158:194-196, 2008
8. Naylor E, Sarkar P, Perlis CS, et al: Primary cutaneous adenoid cystic carcinoma. *J Am Acad Dermatol* 58:636-641, 2008

9. Collette F, Hamoir M, Van Eeckhout P, et al: Metastatic cutaneous apocrine adenocarcinoma successfully treated with systemic anti-androgen therapy—A case report. *Clin Case Rep* 8:3471-3477, 2020
10. Tlemcani K, Levine D, Smith RV, et al: Metastatic apocrine carcinoma of the scalp: Prolonged response to systemic chemotherapy. *J Clin Oncol* 28:e412-e414, 2010
11. Piedbois P, Breau JL, Moreire JF, et al: Sweat gland carcinoma with bone and visceral metastases. Prolonged complete remission lasting 16 months as a result of chemotherapy. *Cancer* 60: 170-172, 1987
12. Guercio BJ, Iyer G, Kidwai WZ, et al: Treatment of metastatic extramammary Paget disease with combination ipilimumab and nivolumab: A case report. *Case Rep Oncol* 14:430-438, 2021
13. Rogatsch M, Schmid J, Lax S, et al: Metastatic cutaneous apocrine adenocarcinoma responsive to the programmed cell death protein 1 inhibitor pembrolizumab. *Eur J Cancer* 90:146-148, 2018
14. Hidaka T, Fujimura T, Watabe A, et al: Successful treatment of HER-2-positive metastatic apocrine carcinoma of the skin with lapatinib and capecitabine. *Acta Derm Venereol* 92:654-655, 2012
15. Otsuka M, Yamasaki O, Kaji T, et al: Metastatic cutaneous apocrine adenocarcinoma treated with a combination of pertuzumab-based targeted therapy and taxane chemotherapy. *JAMA Dermatol* 152:111, 2016
16. Kamanda S, Epstein JI, Osunkoya AO, et al: Poorly differentiated scrotal carcinoma with apocrine immunophenotype. *Am J Dermatopathol* 44:260-266, 2022
17. Ladekarl M, Nøhr AK, Sønderkær M, et al: Feasibility and early clinical impact of precision medicine for late-stage cancer patients in a regional public academic hospital. *Acta Oncol (Madr)* 62: 261-271, 2023
18. Miles D, Ciruelos E, Schneeweiss A, et al: Final results from the PERUSE study of first-line pertuzumab plus trastuzumab plus a taxane for HER2-positive locally recurrent or metastatic breast cancer, with a multivariable approach to guide prognostication. *Ann Oncol* 32:1245-1255, 2021
19. Lima NF, Sampaio LAF, Xavier CB, et al: Complete response to sequential human epidermal growth factor receptor 2-targeted strategies in a heavily pretreated patient with human epidermal growth factor receptor 2-amplified metastatic bladder cancer. *JCO Precis Oncol* 10.1200/PO.22.00414
20. Torres-Jiménez J, Esteban-Villarrubia J, Ferreira-Monteagudo R: Precision medicine in metastatic colorectal cancer: Targeting ERBB2 (HER-2) oncogene. *Cancers (Basel)* 14:3718, 2022
21. Oh DY, Bang YJ: HER2-targeted therapies—A role beyond breast cancer. *Nat Rev Clin Oncol* 17:33-48, 2020
22. Shah AN, Sunderraj A, Finkelman B, et al: Positive predictive value of ERBB2 copy number gain by tissue or circulating tumor DNA next-generation sequencing across advanced cancers. *Oncotarget* 13:273-280, 2022
23. Rothé F, Silva MJ, Venet D, et al: Circulating tumor DNA in HER2-amplified breast cancer: A translational research substudy of the NeoALTTO phase III trial. *Clin Cancer Res* 25:3581-3588, 2019
24. Schlam I, Tarantino P, Tolane SM: Overcoming resistance to HER2-directed therapies in breast cancer. *Cancers (Basel)* 14:3996, 2022
25. Shah AN, Santa-Maria CA, Mukhija D, et al: A phase II single-arm study of palbociclib in patients with HER2-positive breast cancer with brain metastases and analysis of ctDNA in patients with active brain metastases. *Clin Breast Cancer* 23:324-329, 2023
26. Wakabayashi S, Togawa Y, Yoneyama K, et al: Dramatic clinical response of relapsed metastatic extramammary Paget's disease to trastuzumab monotherapy. *Case Rep Dermatol Med* 2012:1-3, 2012
27. Barth P, Dulaimi AI-Saleem E, Edwards KW, et al: Metastatic extramammary Paget's disease of scrotum responds completely to single agent trastuzumab in a hemodialysis patient: Case report, molecular profiling and brief review of the literature. *Case Rep Oncol Med* 2015:1-7, 2015
28. Karam A, Berek JS, Stenson A, et al: HER-2/neu targeting for recurrent vulvar Paget's disease. *Gynecol Oncol* 111:568-571, 2008
29. Hanawa F, Inozume T, Harada K, et al: A case of metastatic extramammary Paget's disease responding to trastuzumab plus paclitaxel combination therapy. *Case Rep Dermatol* 3:223-227, 2011
30. Takahagi S, Noda H, Kamegashira A, et al: Metastatic extramammary Paget's disease treated with paclitaxel and trastuzumab combination chemotherapy. *J Dermatol* 36:457-461, 2009
31. Ichihara T, Gomi D, Fukushima T, et al: Successful and long-term response to trastuzumab plus paclitaxel combination therapy in human epidermal growth factor receptor 2-positive extramammary Paget's disease: A case report and review of the literature. *Mol Clin Oncol* 7:763-766, 2017
32. Nordmann TM, Messerli-Odermatt O, Meier L, et al: Sequential somatic mutations upon secondary anti-HER2 treatment resistance in metastatic ERBB2S310F mutated extramammary Paget's disease. *Oncotarget* 10:6647-6650, 2019
33. Zattarin E, Nichetti F, Ligorio F, et al: Case Report: Prolonged clinical benefit with sequential trastuzumab-containing treatments in a patient with advanced extramammary Paget disease of the groin. *Front Oncol* 12:925551, 2022
34. Shin JW, Kim S, Ha S, et al: The HER2 S310F mutant can form an active heterodimer with the EGFR, which can be inhibited by cetuximab but not by trastuzumab as well as pertuzumab. *Biomolecules* 9:629, 2019
35. Shimato S, Wakabayashi T, Mizuno M, et al: Brain metastases from apocrine carcinoma of the scalp: Case report. *J Neurooncol* 77:285-289, 2006

APPENDIX

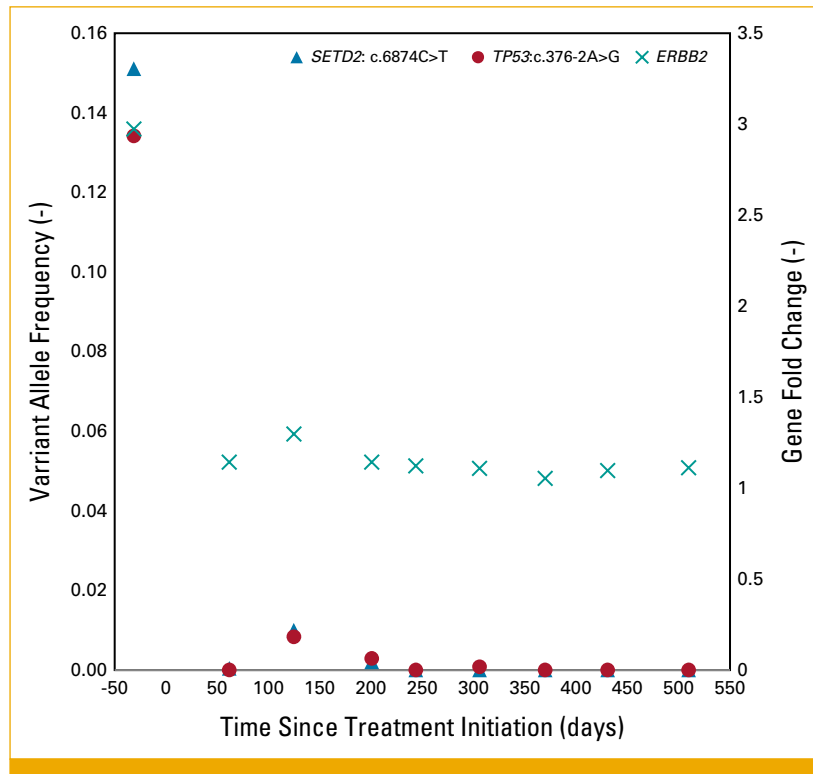


FIG A1. ctDNA analysis of clinically relevant genetic alterations. Variant allele frequencies of *SETD2*: c.6874C>T and *TP53*: c.376-2A>G are indicated on the left axis, and gene fold changes of *ERBB2* are indicated on the right axis. Day 0 indicates the day of treatment initiation. ctDNA, circulating tumor DNA.

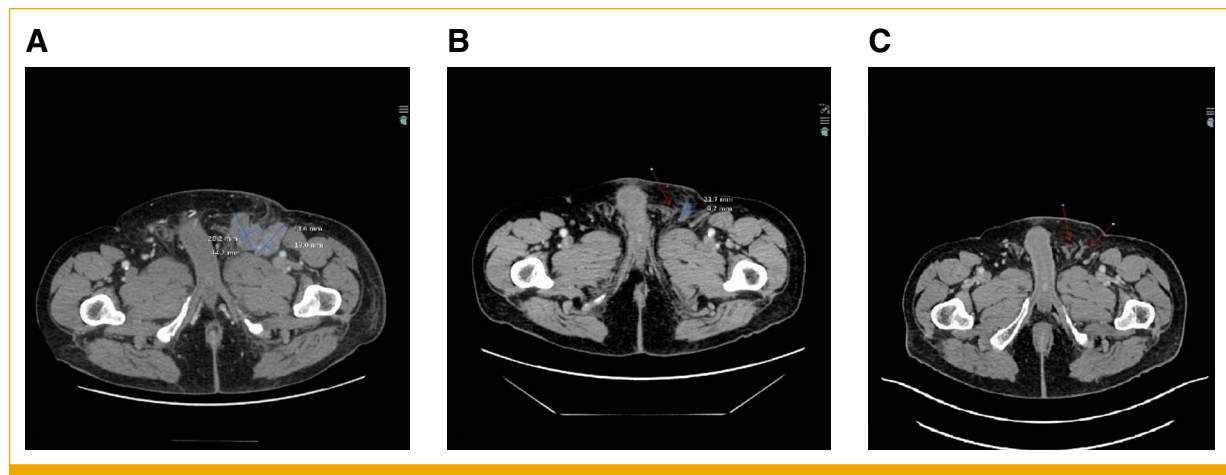


FIG A2. Contrast-enhanced axial CT scans of the pelvic area. (A) Baseline, showing enlarged pathologic lymph nodes in the left inguinal region. (B) After three cycles of treatment, showing partial regression. (C) After nine cycles of treatment, showing complete regression of lymph node metastases. CT, computed tomography.