

Detailed motility and function of the opioid-affected colon

A study based on MRI and the electromagnetic capsule system

Mark, Esben Bolvig

DOI (link to publication from Publisher):
[10.54337/aau306526107](https://doi.org/10.54337/aau306526107)

Publication date:
2019

Document Version
Publisher's PDF, also known as Version of record

[Link to publication from Aalborg University](#)

Citation for published version (APA):

Mark, E. B. (2019). *Detailed motility and function of the opioid-affected colon: A study based on MRI and the electromagnetic capsule system*. Aalborg Universitetsforlag. <https://doi.org/10.54337/aau306526107>

General rights

Copyright and moral rights for the publications made accessible in the public portal are retained by the authors and/or other copyright owners and it is a condition of accessing publications that users recognise and abide by the legal requirements associated with these rights.

- Users may download and print one copy of any publication from the public portal for the purpose of private study or research.
- You may not further distribute the material or use it for any profit-making activity or commercial gain
- You may freely distribute the URL identifying the publication in the public portal -

Take down policy

If you believe that this document breaches copyright please contact us at vbn@aub.aau.dk providing details, and we will remove access to the work immediately and investigate your claim.

DETAILED MOTILITY AND FUNCTION OF THE OPIOID-AFFECTED COLON

**A STUDY BASED ON MRI AND THE ELECTROMAGNETIC
CAPSULE SYSTEM**

**BY
ESBEN BOLVIG MARK**

DISSERTATION SUBMITTED 2019



AALBORG UNIVERSITY
DENMARK

DETAILED MOTILITY AND FUNCTION OF THE OPIOID-AFFECTED COLON

**A STUDY BASED ON MRI AND THE ELECTROMAGNETIC
CAPSULE SYSTEM**

by

Esben Bolvig Mark

Dissertation submitted January 2019



AALBORG UNIVERSITY
DENMARK



NORTH DENMARK REGION

Dissertation submitted: January 2019

PhD supervisor: Professor Asbjørn Mohr Drewes, MD, DMSc, PhD
Aalborg University Hospital
Aalborg University, Denmark

PhD co-supervisors: Professor Jens Brøndum Frøkjær, MD, PhD
Aalborg University Hospital
Aalborg University, Denmark

Associate Professor Lasse Riis Østergaard, PhD
Aalborg University, Denmark

PhD committee: Allan Carlé, Clinical Associate Professor (chairman)
Aalborg University

Bodil Ohlsson, Professor of Medicine
Lund University

Alexander Menys, Researcher
University College London

PhD Series: Faculty of Medicine, Aalborg University

Department: Department of Clinical Medicine

ISSN (online): 2246-1302
ISBN (online): 978-87-7210-377-8

Published by:
Aalborg University Press
Langagervej 2
DK – 9220 Aalborg Ø
Phone: +45 99407140
aauf@forlag.aau.dk
forlag.aau.dk

© Copyright: Esben Bolvig Mark

Printed in Denmark by Rosendahls, 2019

CV

Esben Bolvig Mark

Born in 1988, Aalborg, Denmark



Current position

2015–2019 PhD student at Mech-Sense, Department of Gastroenterology and Hepatology, Aalborg University Hospital

Education

2015 M.Sc. in Biomedical Engineering and Informatics at Aalborg University

Publications

1. **Mark EB**, Klinge MW, Grønlund D, Schlageter V, Scott SM, Krogh K, Drewes AM. Ambulatory assessment of colonic motility using the electromagnetic capsule tracking system: effects of opioids. Submitted: Am J Gastroenterol. January 2019.
2. **Mark EB**, Brendstrup MB, Grønlund D, Østergaard LR, Frøkjaer JB, Drewes AM. MRI analysis of fecal volume and dryness – validation study using an experimental oxycodone-induced constipation model. J Magn Reson Imaging. 2019. [in press]
3. **Mark EB**, Poulsen JL, Haase A-M, et al. Ambulatory assessment of colonic motility using the electromagnetic capsule tracking system. Neurogastroenterol Motil. 2018. [in press]

4. Ozola-Zālīte I, **Mark EB**, Gudauskas T, et al. Reliability and validity of the new VikingSlice software for computed tomography body composition analysis. *Eur J Clin Nutr*. 2018. [in press]
5. Kipp JP, Olesen SS, **Mark EB**, Frederiksen LC, Drewes AM, Frøkjær JB. Normal pancreatic volume in adults is influenced by visceral fat, vertebral body width and age. *Abdom Radiol*. 2018. [in press]
6. Poulsen JL, **Mark EB**, Brock C, Frøkjær JB, Krogh K, Drewes AM. Colorectal transit and volume during treatment with prolonged-release oxycodone/naloxone versus oxycodone plus macrogol 3350. *J Neurogastroenterol Motil*. 2018;24(1):119-127.
7. Madzak A, Olesen SS, Poulsen JL, **Mark EB**, Drewes AM, Frøkjær JB. MRI assessed pancreatic morphology and exocrine function are associated with disease burden in chronic pancreatitis. *Eur J Gastroenterol Hepatol*. 2017;29(11):1269-1275.
8. **Mark EB**, Poulsen JL, Haase AM, et al. Assessment of colorectal length using the electromagnetic capsule tracking system: a comparative validation study in healthy subjects. *Colorectal Dis*. 2017;19(9):O350-O357.
9. Lelic D, Hansen TM, **Mark EB**, Olesen AE, Drewes AM. The effects of analgesics on central processing of tonic pain: A cross-over placebo controlled study. *Neuropharmacology*. 2017;123:455-464.
10. Thomsen LP, Aliuskeviciene A, Sørensen K, Nørgaard AC, Sørensen PL, **Mark EB**, Riddersholm SJ, Thorgaard P. Non-invasive estimation of respiratory depression profiles during robot-assisted laparoscopic surgery using a model-based approach. In: Badnjevic A, ed. *CMBEBIH 2017: Proceedings of the International Conference on Medical and Biological Engineering 2017*. Vol 62. IFMBE Proceedings. 2017:223-231.
11. Hansen TM, **Mark EB**, Olesen SS, Gram M, Frøkjær JB, Drewes AM. Characterization of cortical source generators based on electroencephalography during tonic pain. *J Pain Res*. 2017:1401-1409.

The thesis is based on the following four papers:

- I. **Mark EB**, Poulsen JL, Haase AM, et al. Assessment of colorectal length using the electromagnetic capsule tracking system: a comparative validation study in healthy subjects. *Colorectal Dis.* 2017;19(9):O350-O357.
- II. **Mark EB**, Poulsen JL, Haase A-M, et al. Ambulatory assessment of colonic motility using the electromagnetic capsule tracking system. *Neurogastroenterol Motil.* 2018. [in press]
- III. **Mark EB**, Brendstrup MB, Grønlund D, Østergaard LR, Frøkjær JB, Drewes AM. MRI analysis of fecal volume and dryness – validation study using an experimental oxycodone-induced constipation model. *J Magn Reson Imaging.* 2019. [in press]
- IV. **Mark EB**, Klinge MW, Grønlund D, Schlageter V, Scott SM, Krogh K, Drewes AM. Ambulatory assessment of colonic motility using the electromagnetic capsule tracking system: effects of opioids. Submitted: *Am J Gastroenterol.* January 2019.

ABBREVIATIONS

CNS	Central nervous system
CPM	Contractions per minute
ENS	Enteric nervous system
GI	Gastrointestinal
HAPS	High-amplitude propagating sequences
HRM	High-resolution manometry
MRI	Magnetic resonance imaging
OIBD	Opioid-induced bowel dysfunction
OIC	Opioid-induced constipation
PAMORA	Peripherally acting μ -opioid receptor antagonist
WMC	Wireless motility capsule

ENGLISH SUMMARY

Opioids are often used in treatment of acute and chronic pain, but unfortunately lead to several unwanted side effects in the gastrointestinal (GI) tract. Opioid-induced constipation (OIC) is reported as the most common side effect, experienced by 40-70% of patients taking opioids. The pathophysiology underlying OIC is complex and rely on activation of μ -opioid receptors in the enteric nervous system that have a negative impact on colonic motility, GI fluid secretion/absorption and sphincter function. OIC is normally treated with laxatives, although the efficacy is often low, and treatment may lead to additional GI symptoms. Recently, alternative treatment for OIC has become available. That includes co-administration of peripherally acting μ -opioid receptor antagonists (PAMORA), which specifically treats the mechanisms underlying the pathophysiology of OIC. Measures of colonic function and motility can be difficult to obtain due to anatomy of the colon and the current available measurement techniques. The purpose of this PhD project was to establish objective measures of colonic function and apply them to test how colon physiology is affected by opioids and opioid-antagonists.

The first objective was to develop and validate methods to investigate detailed colonic motility, content and volume with objective measurement techniques including magnetic resonance imaging (MRI) and ingestible motility capsules (3D-Transit). The second objective was to assess the effect of oxycodone treatment on detailed colonic motility, fecal dryness and volume using the newly established measurement techniques. The third objective was to assess the efficacy of the opioid-antagonist naloxegol combined with oxycodone on detailed colonic motility.

Objective 1 was investigated in 45 healthy volunteers and 7 patients with known chronic diarrhea. Data were combined from three independent clinical trials to be used for development of measurement methods. It was possible to establish a method that could estimate colonic length and describe colonic motor patterns that moved a motility capsule at fast and slow velocities, at differing length and mostly antegrade, but also retrograde. Furthermore, colonic fecal volume and fecal dryness were described for each colonic segment using MRI. Objective 2 was investigated in 25 healthy volunteers who were treated for five days with oxycodone or placebo in a double-blinded, randomized, crossover design. Oxycodone treatment effectively induced OIC symptoms including increased colonic transit time, increased colonic fecal volume and decreased stool water amount. Colonic motor patterns were slower during oxycodone treatment. Objective 3 included 24 healthy volunteers who were treated for six days with naloxegol combined with oxycodone or placebo combined with oxycodone in a double-blinded, randomized, cross-over design. Naloxegol effectively reversed most of the oxycodone-induced symptoms on colonic motor function including colonic transit time and made the motor patterns faster compared to oxycodone alone.

In conclusion, methods using motility capsules and MRI were developed and showed that oxycodone treatment affects colonic motor patterns and content.

Naloxegol reverses most of the induced changes in colonic motility. Despite limitations of study design, the proposed methods were useful to investigate the complex pathophysiology underlying OIC. Further validation of methods and comparison with e.g. high-resolution manometry may optimize methods to enable classification of more detailed motor patterns.

DANSK RESUME

Opioider som morfin, bliver ofte brugt i behandlingen af akutte og kroniske smerter, hvilket desværre medfører en række bivirkninger i mavetarmkanalen. Opioid-induceret forstoppelse er den hyppigste bivirkning, og 40-70% af patienter i opioid-behandling får forstoppelse. Patofysiologien bag forstoppelsen er kompleks og afhænger af aktivering af μ -opioid receptorer i det enteriske nervesystem, som har en negativ effekt på tyktarmens kontraktionsmønstre, sekretion, væskeabsorption og sfinkterfunktion. Opioid-induceret forstoppelse bliver normalt behandlet med laksantia. Denne behandling er ofte ineffektiv og bidrager ofte med yderligere bivirkninger i mavetarmkanalen. En nyere behandlingsmetode benytter perifert virkende μ -opioid antagonist, som specifikt behandler de mekanistiske forandringer i tarmvæggen forårsaget af opioidbehandlingen. Det kan være svært at måle på tyktarmens funktioner og kontraktionsmønstre pga. dens anatomiske lokalisering og begrænsninger af de nuværende metoder til at måle tarmfunktion. Formålet med dette ph.d.-projekt var at udvikle og etablere målemetoder til at måle på tyktarmsfunktion og anvende dem til at teste dens fysiologi under opioidbehandling og efterfølgende under behandling med opioid-antagonister.

Projektets første formål var at udvikle og validere objektive målemetoder til at undersøge tyktarmens kontraktionsmønstre, volumen og indhold ved brug af magnetisk resonans (MR) skanninger og motilitetskapsler (3D-Transit). Det andet formål var at bruge de nyudviklede metoder til at vurdere, hvordan behandling med opioidet oxycodon påvirker tyktarmens kontraktionsmønstre, tørhed og volumen af indhold. Det tredje formål var at vurdere, hvor effektivt opioid-antagonisten naloxegol kombineret med oxycodon kunne modvirke de opioid-inducerede ændringer i tyktarmens kontraktionsmønstre.

Første formål blev undersøgt i 45 raske frivillige og 7 patienter med kendt kronisk diarré. Data blev indsamlet i tre uafhængige kliniske forsøg og skulle anvendes til at udvikle målemetoderne. Det var muligt at etablere en metode, der kunne estimere længden af tyktarmen samt beskrive tyktarmens kontraktionsmønstre med en motilitetskapsel. Kapslen kunne måle hurtige og langsomme tarmbevægelser i forskellige længder, som kunne være enten forud- eller bagudrettet. Desuden kunne MR-skanninger bruges til at beskrive volumen og tørhed af tyktarmsindhold. Det andet formål blev undersøgt i 25 raske frivillige, som blev behandlet i fem dage med oxycodon eller placebo i et dobbeltblindet, randomiseret, overkrydsningsstudie. Behandling med oxycodon resulterede i symptomer i mavetarmkanalen. Transittid igennem tyktarmen og volumen af tyktarmsindhold var forøget, mens indholdet havde mindre vandindhold. Bevægelsesmønstrene i tyktarmen var langsommere under opioidbehandlingen sammenlignet med placebo. Det tredje formål blev undersøgt i 24 raske frivillige, som blev behandlet i seks dage med opioidantagonisten naloxegol kombineret med oxycodon eller placebo kombineret med oxycodon i et dobbeltblindet, randomiseret, overkrydsningsstudie. Naloxegol ændrede de fleste af de opioid-inducerede forstyrrelser i tyktarmens bevægelsesmønstre tilbage mod

normalen. Behandlingen nedsatte transittiden og gjorde bevægelsesmønstrene hurtigere sammenlignet med oxycodonbehandlingen.

Den nye metode baseret på målinger med motilitetskapsler og MR-skanninger viste at oxycodon-behandling påvirker tyktarmens bevægelsesmønstre og tarmindehold. Naloxegol modvirker de fleste af bivirkningerne. Til trods for begrænsninger med det valgte studiedesign, kunne de foreslåede metoder undersøge den komplekse patofysiologi bag opioid-induceret forstoppelse. Et fremtidigt valideringsstudie af de anvendte metoder, kunne kombinere undersøgelserne med f.eks. højopløsnings-manometri, hvorefter det burde være muligt at optimere metoderne til at klassificere tarmens bevægelsesmønstre i endnu højere detaljegrad end i dette ph.d.-studie.

ACKNOWLEDGEMENTS

The studies compiled in this PhD thesis could not have been completed without assistance from my helpful supervisors, colleagues and friends.

At first, I would like to thank my supervisor professor Asbjørn Mohr Drewes. He has been an inspiring mentor since I started my research career at Mech-Sense in 2015. Asbjørn has so many exciting research ideas and it has been a pleasure to help him investigate a few of those in this PhD project. Despite that Asbjørn was often not present during (very) long periods of my project due to obligations outside Denmark, he always has time to answer my emails within 30 minutes. And this is also during conference meetings and Sunday afternoons.

I would also like to thank my two co-supervisors, professor Jens Brøndum Frøkjær (Department of Radiology, Aalborg University Hospital) and associate professor Lasse Riis Østergaard (Department of Health Science and Technology, Aalborg University). I wish to thank Jens for his often-critical review of my work and the never-ending talks regarding the wonders of radiology; and I wish to thank Lasse for the many discussions of the best (and often most simple) methods to investigate the gastrointestinal tract using image analysis. Beside the credited supervisors, professor Klaus Krogh (Neurogastroenterology Unit, Aarhus University Hospital, DK), Dr. S. Mark Scott (Neurogastroenterology Group, Queen Mary University, UK) and Vincent Schlageter (Motilis Medica SA, CH) all served as brilliant mentors and have been vital for my research. Thanks for the always positive welcome when visiting you in Aarhus, London and Lausanne.

My co-authors also deserve a special recognition: Jakob Lykke Poulsen, Debbie Grønlund, Anne-Mette Haase, Tine Gregersen, Mette Winther Klinge, Mark Brendstrup Bødker, and Marie Espersen for contributing to Papers I-IV. A special thanks to Jakob Lykke Poulsen and Debbie Grønlund for the intellectual discussions of MRI and 3D-Transit data (and Stata), and Mette Winther Klinge for swift help when asked for.

My colleagues at Mech-Sense have all contributed in inspirational discussions and help is always coming if needed. Especially, discussions of analytical methods have been most beneficial due to my current and former engineer colleagues Tine Maria Hansen, Rasmus Wiberg Nedergaard, Samran Navid, Dina Lelic, and Mikkel Gram. I also appreciate all the time that Kenneth Krogh Jensen from the Department of Radiology has spent on looking at feces for my research. Furthermore, I wish to thank the healthy volunteers, who volunteering got induced constipation; and our collaborators at the Department of Gastroenterology and Hepatology for help in conducting the studies.

The clinical trials included in this thesis were funded by unrestricted research grants from The Svend Andersen foundation, Kyowa Kirin, AstraZeneca, Mundipharma Research GmbH & Co. KG, Aage og Johanne Louis-Hansens Fond,

A.P. Møller Foundation for the Advancement of Medical Science, Heinrich Kopps foundation and Novartis. Furthermore, PhD salary was partly funded from Region Nordjyllands Sundhedsvidenskabelige Forskningsfond. Traveling and dissemination of results have been funded by The Oticon foundation and the Lundbeck foundation.

Lastly, I wish to thank my wife, Julie, for your support in all the frustrating moments, and of course my baby daughter, Hannah, for reminding me that research after all is not the most important thing in the world.

Esben Bolvig Mark, January 2018, Aalborg

TABLE OF CONTENTS

Chapter 1. Introduction.....	15
Chapter 2. Background	17
2.1. Colonic anatomy and physiology.....	17
2.2. The enteric nervous system.....	18
2.3. Colonic motility	19
2.4. Opioid-induced constipation.....	21
2.5. Measurements of colonic motility	22
Chapter 3. Hypotheses & aims.....	25
Chapter 4. Materials & methods.....	27
4.1. Study design	27
4.2. The 3D-Transit system	30
4.2.1. Analysis pipeline for colonic motility.....	31
4.3. MRI-based measurements	36
4.3.1. Analysis pipeline for MRI measures.....	36
Chapter 5. Key results	39
5.1. Aim 1.....	39
5.2. Aim 2.....	40
5.3. Aim 3.....	40
5.4. Aim 4.....	41
5.5. Aim 5.....	41
5.6. Aim 6.....	42
Chapter 6. Discussion	43
6.1. Methodological considerations	43
6.1.1. 3D-Transit.....	43
6.1.2. Magnetic Resonance Imaging	47
6.2. Experimental settings	48
Chapter 7. Conclusion	51
7.1. Future perspectives & clinical implications.....	51
Literature list.....	52

CHAPTER 1. INTRODUCTION

Opioids are among the most commonly prescribed analgesics for moderate and severe acute and chronic pain. They are one among the potent treatments used for pain management and there has been a recent rise in opiate consumption leading to more frequently reported side effects.¹ Approximately 3-5% of all inhabitants in Denmark use opioids.² Unfortunately, opioids are associated with multiple adverse effects that counteracts their analgesic effect. The opioids bind to specific receptors within the central nervous system (CNS), whereby they decrease firing of nerves caused by pain stimuli and ultimately decrease the pain. The enteric nervous system (ENS) found in the gastrointestinal (GI) tract also contains opioid receptors, where the binding of opioids happens as well, although with unwanted side-effects. In the bowel wall, opioids binds to opioid μ -receptors,^{3,4} and affect gut motility, secretion and sphincter function.⁵ This causes a cluster of GI symptoms referred to as opioid-induced bowel dysfunction (OIBD). OIBD embraces gastroesophageal reflux, abdominal discomfort, vomiting, bloating, rumbling and infrequent, incomplete or difficult evacuation.⁶ The most common adverse effect of opioid treatment is opioid-induced constipation (OIC), which 40-70% of patients taking opioids suffer from.^{6,7} Unfortunately for the patients as well as for health care and social economics, OIC has been associated with reduced work productivity and quality of life.^{8,9} The side-effects of opioid treatment are cumulative. It is well-known that colonic transit time increases during opioid use,¹⁰ and a prolonged colonic transit increases passive water absorption leading to drier stools that ultimately contributes to OIC.¹¹ Opioids, however, also directly affect secretion of water to the gut. When investigating the pathophysiology behind OIC it is important to factor in knowledge of colonic water content and fecal volume, which helps to investigate colonic secretion and how the opioid treatment affects it.¹² Conventional laxatives are the recommended treatment for OIC.¹³ Unfortunately, laxatives do not always provide an adequate effect on the OIC,¹⁴ and they are also associated with a number of adverse effects like bloating, abdominal distension and gastroesophageal reflux.¹⁵ Several opioid receptor antagonists developed specifically for targeting the pathophysiology of OIC (i.e., does not cross the blood-brain barrier) have been introduced within the last decade,^{16,17} but studies investigating their effect on colonic volume, secretion and water absorption are lacking. As of now, it is thought that opioids reduce gut water secretion by inactivating chloride channels in the gut mucosa, which disrupts the osmotic gradient across the gut lumen.¹⁸ However, it is difficult to assess the effect of opioids on gut water content and fecal volume in clinical practice. We know that opioid receptor agonists have an impact on both excitatory and inhibitory activity, and they can activate the interstitial cell-muscle network. Hence, their effects on GI motility and secretion may be complex.¹⁹ Most of our current knowledge is obtained from isolated muscle strips or preclinical studies, why it remains to be determined how opioids affect the colon *in vivo*, and whether opioids lengthen transit by causing dyscoordinated peristalsis or changes the motor pattern.²⁰ Regardless, the pathophysiology behind OIC needs further investigations.

CHAPTER 2. BACKGROUND

2.1. COLONIC ANATOMY AND PHYSIOLOGY

The large intestine, also known as the colon, is the last part of the GI tract starting after the ileum and ending at the rectum. The colonic organ is about 1 to 1.5 meter long and has a width of 7.5 cm, however the size and shape of individual segments and the total length have very high variation between individuals.^{21–23} Especially the s-shaped sigmoid colon can change its shape and often folds up towards the transverse colon (**Figure 1**). The primary functions of the large intestine are to reabsorb water, absorb vitamins, and compress indigestible materials in preparation for defecation. Only 10% of the total GI nutrient absorption occurs in the colon.²³ The cecum is the most proximal part of the colon, where the fecal material is mixed and awaits further propagation. During propagation towards the rectum, most of the water content is absorbed through the gut wall. Each day 1400 mL of intestinal content enters the cecum from the ileum (small intestine) and only 150 mL of feces is evacuated.²³ The average composition of feces is 75% water, 5% bacteria, and a mixture of remains of epithelial cells, indigestible material and inorganic matter. Colonic content is moved towards the rectum by contractions of the circular muscle layer in the gut wall.

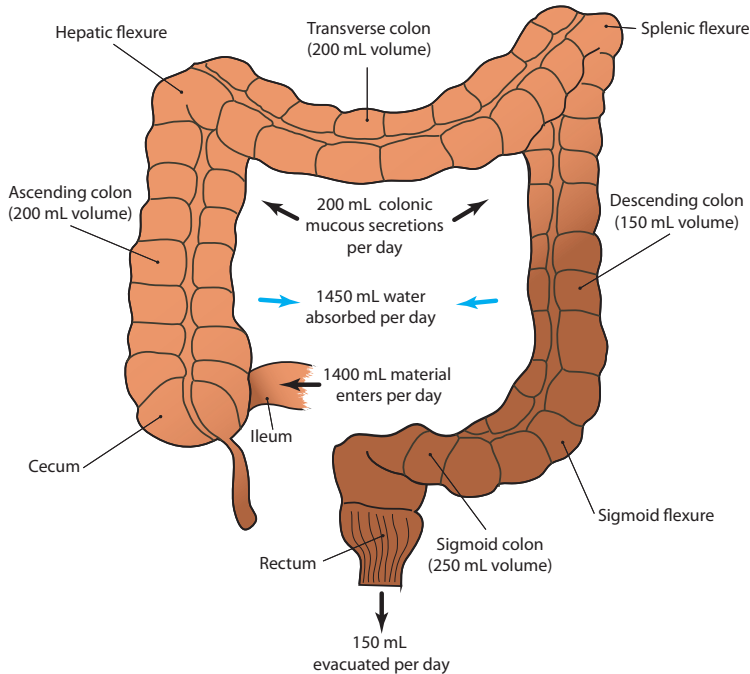


Figure 1. The anatomy of the large intestine and typical volumes for colonic segments, inputs and outputs. Absorption of water is marked with blue arrows.

Colonic contractions are collectively referred to as colonic motility which represents the complex mechanisms that transports the fecal material through the large intestine.

2.2. THE ENTERIC NERVOUS SYSTEM

The ENS plays a dominant role in GI physiology. The GI tract is innervated through an extrinsic component via the CNS and an intrinsic component mainly inside the bowel wall via the ENS. Even if parts of the GI tract is isolated from the CNS, motor activity is still observed.²⁴ GI function is mostly controlled through parasympathetic pathways, that increases secretion, peristalsis and vasodilation. In contrast, the sympathetic pathways reduces peristalsis and causes vasoconstriction.²⁵ The motor activity in the gut is controlled and monitored through the 200-600 million neurons in the ENS, that collectively forms a complex network of motor neurons, interneurons and sensory neurons.²⁵ The mechanical modulation and progression of luminal content are performed by the longitudinal and circular muscle fibers in the gut wall. In general, the nerves in ENS can be divided in the submucosal plexus and the myenteric plexus (**Figure 2**). Secretion and absorption are controlled by the submucosal plexus (located close to the intestinal epithelium), while the myenteric plexus mainly is responsible for controlling GI motor activity (located between the two muscle layers). The μ -receptor is the most expressed opioid receptor in the human ENS, and it is localized in both the myenteric and submucosal plexuses. The μ -receptors are involved in the control of GI motility and are activated by the endogenous ligands endorphins, dynorphins and enkephalins.²⁶ The opioid receptors (also including κ - and δ -receptors) lead to reduced neurotransmitter release and neuronal excitability.²⁷ Binding of opioid agonists to the receptors activate potassium

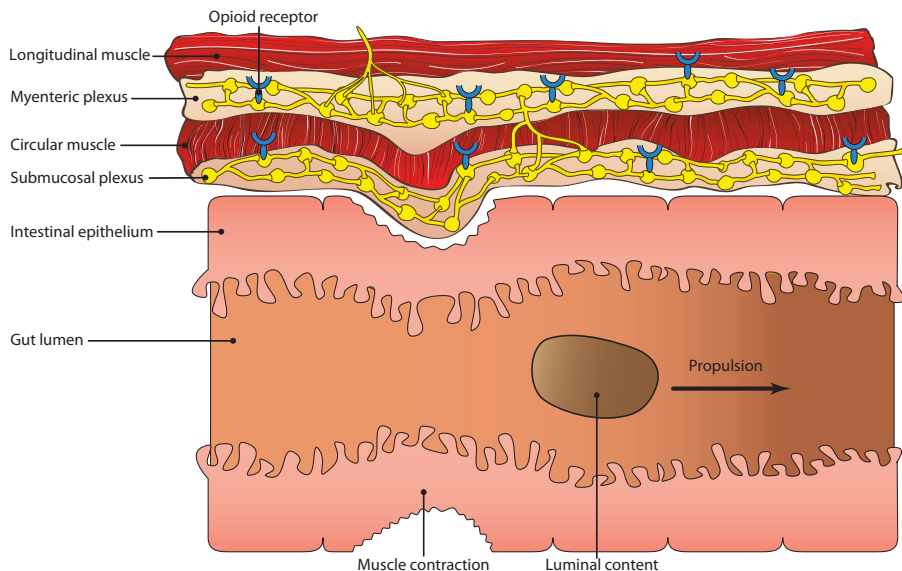


Figure 2. The enteric nervous system alongside the gastrointestinal tract.

channels and inhibit calcium channels, which leads to decreased release of neurotransmitter and hyperpolarization, ultimately reducing the probability for firing of action potentials.²⁸

2.3. COLONIC MOTILITY

“Colonic motor patterns are one of the most variable and unpredictable phenomena in organisms.”

This quote from SK. Sarna, 2010 clearly underlines the difficulties in understanding the human colon physiology.²⁹ Throughout the colon, contraction frequency and amplitude vary not only diurnally, but also according to gender, physical exercise, meals, and psychological stress.²⁹ Despite this, there has for many years been focus on investigating colonic motility, especially in relevance to pathophysiology of various GI diseases and unwanted side-effects to pharmacological interventions like opioid treatment.

Peristalsis

Most of colonic motor activity is coordinated contractions and relaxations of the intestinal lamina muscularis called peristalsis.³⁰ The contractions have the purpose of moving luminal contents through the gut and mixing it with secreted fluids. Three different contraction types perform most of the known colonic motility functions:²⁹

1. *Rhythmic phasic contractions* mix the luminal content and cause a slow progressive propulsion.
2. *Tonic contractions* aid the motor function of the rhythmic phasic contractions.
3. *Mass movements* are produced by the giant migrating contractions that occurs only few times per day. The distance of propagation and contraction amplitude during a mass movement are much larger than in the slower rhythmic phasic contractions. The large contractions of the smooth muscle cells increase the intraluminal pressure, thereby called high-amplitude propagating sequences (HAPS).³¹

These contraction types result in different colonic motility patterns (**Figure 3**). The colonic motility patterns shown in the figure are recently deducted from high-resolution manometry (HRM) studies,^{32,33} and additional motor patterns exist beside these, although these represent the most essential movements. Much alike the *mass movements*, the *long single propagating motor pattern* progresses throughout the colon and at faster velocity, although with much lower contraction amplitude.³² A *cyclic propagating motor pattern* has also been described and progresses either antegrade or retrograde, and will continue to make contractions at the same location to mix the content in a cycle lasting minutes.³²

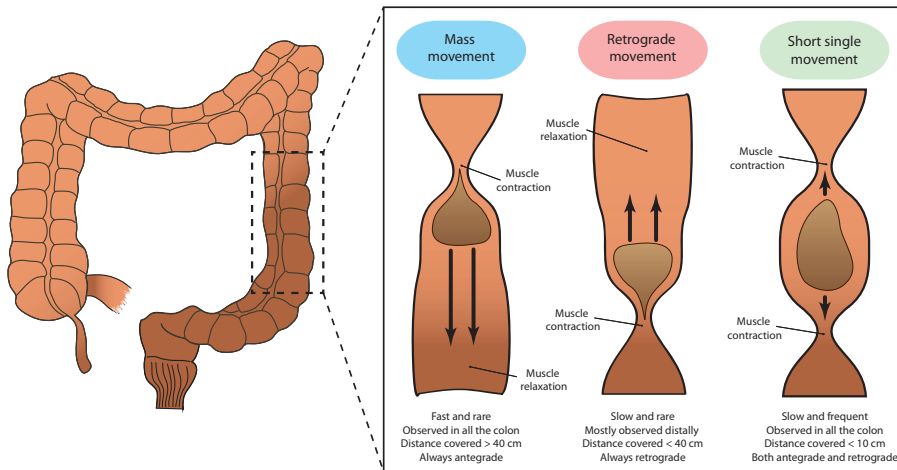


Figure 3. Colonic propulsive motor patterns.

Regulation of colonic motility

Colonic motility is very complex, and it is regulated both by internal and external signals. The colon has a contraction frequency of approximately 3-6 contractions per minute (CPM). Inhibitory neurons in the ENS determine the length and duration of the contractions and they can even decrease the pace of slow waves, which produces the smooth muscle contractions.³⁴

Regulation due to luminal content.

The neurons in the ENS have important mechanosensitive nerve endings in the smooth muscles in the gut wall, which are able to coordinate oral contraction and anal relaxation making the luminal content move forward.³⁵ Due to these mechanosensitive nerve endings, peristalsis can be triggered by mechanical distension of the gut.³⁰ The neurological pathways represent a neuromechanical loop that is responsible for propulsion related to the consistency of the luminal content. Hence, the complex mechanisms underlying colonic peristalsis are able to adjust motor activity accordingly and make fluid content progress faster than solid content.³⁵

Regulation by external signals.

The colonic contractions are regulated by several extrinsic factors including CNS, hormones, autonomic neurons, stress mediators, and inflammatory mediators.²⁹ Furthermore, colonic motility is triggered by early awakening and ingestion of meals and coffee due to the gastrocolic response.^{32,36,37} Analgesic treatment with opioids likewise affects colonic motility by occupying the μ -receptors in the ENS and block the firing of action potentials in the bowel wall, ultimately leading to reduced motility and constipation. The pathophysiology underlying OIC is elaborated in the following section.

2.4. OPIOID-INDUCED CONSTIPATION

Treatment with opioids often induce several unwanted GI side-effects that may reduce quality of life and burden daily activities and make patients discontinue treatment or reduce the opioid dose.^{38,39} As much as one third of patients feel the need of decreasing treatment dose or discontinue treatment due to side-effects.⁴⁰ Long term constipation in relation to opioid treatment may furthermore induce risk of ileus, colonic distension and gut perforation, which all are associated with increased mortality.⁴¹ The pathophysiology underlying OIC is complex and both gut secretion and motility are affected during treatment with opioids.

Opioids and gut secretion

Gut water secretion is reduced during opioid treatment due to inactivated chloride channels in the gut mucosa, which causes a disruption in the osmotic gradient.¹⁸ The decrease in secretion of intestinal fluids leads to drier and harder stools. Subsequently, motility is dependent on luminal content and volume, why a change in consistence and volume affects peristalsis.^{25,35}

Opioids and colonic motility

Opioid treatment increases the resting contractile tone of the circular muscle layer in the gut wall.^{42,43} This increases non-propulsive phasic contractions of the longitudinal muscle layer and thereby reduces propulsive motility.^{5,44} Furthermore, opioids may also cause dysregulated motility through a suppression of the neurotransmitter acetylcholine via CNS-stimulated sympathetic overflow in the gut.⁴⁵ Consequently, colonic transit is prolonged during opioid use,^{10,46} which prolongs time for passive absorption of fluids during colonic passage and results in dryer and harder stools. The changed contractile activity manifests as bloating, abdominal cramps and constipation. Most of our knowledge on opioids' effect on colonic motility is obtained from preclinical or ex-vivo studies, why it is yet to be determined how opioids affect the in-vivo human colon. It is important to establish whether opioids prolong transit by reducing the number of mass movement or by inducing uncoordinated peristalsis.

Treatment of OIC

It is recommended to perform physical activity and increase daily fiber intake to decrease constipation severity. However, only little evidence proof an effect of these lifestyle changes.²⁷ The mainstay first-line therapy for OIC is laxatives, but they have no effect on the underlying mechanisms.⁹ Laxatives increase the osmotic gradient, which increases water content (and volume) in the colon leading to a stimulation of the smooth muscles in the colon wall. Consequently, less than half of opioid treated patients using laxatives report an acceptable therapeutic effect, and furthermore, many patients still have GI symptoms even with the use of two or more types of laxatives.^{8,47} Laxative treatment has also been shown to induce several other symptoms like abdominal pain, gas, bloating, and gastro-esophageal reflux, why other treatments are warranted.⁴⁸ Peripherally acting μ -opioid receptor antagonists (PAMORAs) are a new

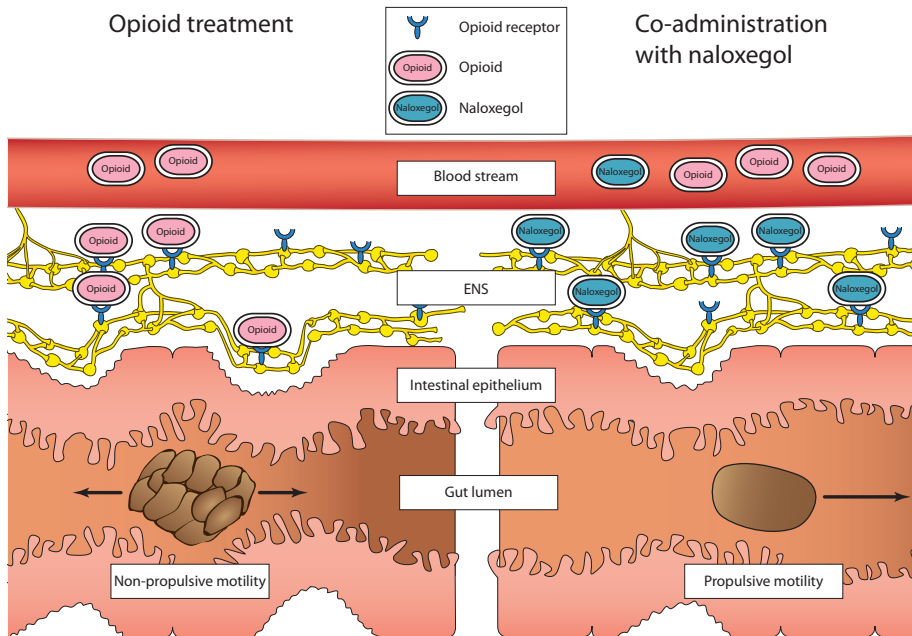


Figure 4. The effect of opioids and naloxegol on gut motility. Opioids occupy the μ -opioid receptors and decrease effective propulsion. Naloxegol blocks the μ -opioid receptors and decrease gastrointestinal side effects. Abbreviation: ENS, enteric nervous system.

group of treatments for opioid-induced GI side effects. They specifically block periphery μ -opioid receptors (in the gut wall) and preserve the wanted analgesic effect (**Figure 4**).⁴⁹ Naloxegol is a PAMORA, and is the OIC treatment included for investigation in this thesis. It is a derivative of naloxone and cannot enter the CNS through the blood-brain barrier mainly due to its large molecule size. Naloxegol has been shown to decrease GI symptoms and increase weekly stool frequency.^{50,51}

2.5. MEASUREMENTS OF COLONIC MOTILITY

Measurements of colonic motility can be difficult to perform due to the colon anatomy and its location. Although, during the recent years there has been technology advances in several different modalities including magnetic resonance imaging (MRI), HRM, and motility capsules.^{32,36,52} Several techniques are able to perform measurements inside the colon; however, most of our current knowledge on colonic motility and motor patterns has been obtained from colonic HRM studies.⁵³ This is mainly due to the impressive research by Phil Dinning and his colleagues, who have performed a long number of clinical studies in the past years including studies of proximal pressure waves,⁵⁴ patients with constipation,^{33,55–57} patients with colonic motor disorders,⁵⁸ the investigation of meal response,³² bowel preparation,⁵⁹ and the rectosigmoid brake.⁶⁰ The current gold-standard for direct assessment of colonic motor function is HRM.⁶¹

HRM provide the best available insight into colonic motility, however recordings are obtained with a catheter placed during colonoscopy. This requires a highly trained investigator, and the colon needs to be empty, which can disturb normal physiology. Furthermore, investigations often last more than 8 hours, and the technique is mainly used in pediatrics. In clinical practice, colonic motility is indirectly assessed by investigating transit time measured with scintigraphy and radiopaque markers.^{62,63} MRI holds the potential to a series of interesting measures of gut motility that does not involve unpleasant invasive procedures. It has recently been used to assess proximal colonic motility and to describe the luminal content of the colon.^{52,64–67} Beside the many applications of MRI, scanner technology develop fast, and most hospitals have access to MRI equipment, why this methodology is especially interesting to follow in the near future.

Motility capsules represent another and more ambulatory approach to measure colonic transit and motility. The wireless motility capsule (WMC, Given Imaging, Israel) allows estimates of regional transit times through the stomach, small bowel and colon. It also provides intraluminal pressure readings allowing for indirect assessment of GI motility.⁶⁸ The system does however, not determine the precise capsule position within the colon, which is needed for description of progression patterns.⁶⁹ The Motilis 3D-Transit system (Motilis Medica SA, Lausanne, Switzerland) determines the position of ingestible electromagnetic capsules throughout GI passage, making measurements of regional transit times possible.⁷⁰ Further analysis of the capsule position within the colon also allows for estimations of capsule movement. This is unfortunately, not possible to do using the native Motilis analysis software, and the development of such methodology is described in this thesis and was part of Paper I and Paper II.^{20,71} Description of colonic movements cannot be performed with other ambulatory systems than the 3D-Transit system. An overview of colonic measurement methods and their advantages is shown in **Table 1**.

Method	Measurement				Advantages							Relevant studies
	Transit times	Contractile activity	Colonic motor patterns	pH	Non- or minor invasive	Standardization and reliability	Ambulatory	Low time consumption	Inexpensive	No radiation exposure	Easy data interpretation	
Scintigraphy	✓	✗	✗	✗	✓	✓	✗	✗	✗	✗	✗	Parkman et al., 2014 ⁽⁶²⁾
Radiopaque markers	✓	✓	✗	✗	✓	✓	✓	✓	✓	✗	✓	Metcalf et al., 1987 ⁽⁶³⁾
WMC	✓	✓	✗	✓	✓	✓	✓	✗	✗	✓	✗	Wang et al., 2015 ⁽⁷²⁾ Farmer et al., 2017 ⁽⁷³⁾
3D-Transit	✓	✓	✓	✗	✓	✗	✓	✗	✗	✓	✗	Haase et al., 2014 ⁽⁷⁰⁾ Mark et al., 2018 ⁽²⁰⁾
MRI	✓	✓	✓	✗	✓	✗	✗	✗	✗	✓	✗	Hoed et al., 2016 ⁽⁵²⁾ Hoed et al., 2016 ⁽⁷⁴⁾ Murray et al., 2017 ⁽⁶⁶⁾
HRM	✗	✓	✓	✗	✗	✗	✗	✗	✗	✓	✗	Dinning et al., 2014 ⁽³²⁾ Dinning et al., 2015 ⁽³³⁾

Table 1. Summary of current methods to assess colonic content, transit and motility. Inspired by the review by Grönlund et al., 2017.⁷⁵ Abbreviations: WMC, wireless motility capsule; MRI, magnetic resonance imaging; HRM, high-resolution manometry.

CHAPTER 3. HYPOTHESES & AIMS

To establish reliable measurement techniques, the first objective of this thesis was to develop and validate methods to investigate colonic motility and assess colonic content and volume. Thus, it was *hypothesized* that measurement methods could be established, and they were reliable between days. This objective was studied in healthy volunteers and in a small cross-sectional study of patients with chronic diarrhea that was included to validate the measures of colonic motility.

The second objective was to assess the effect of oxycodone on colonic motility and content, and it was *hypothesized* that oxycodone would decrease colonic motility, induce dyscoordinated motility, increase fecal volume and increase stool dryness. This was studied in healthy volunteers who were treated with oxycodone to induce constipation in an experimental modelled setting. Measurements were performed during close-to-normal days, in two periods with either oxycodone treatment or placebo.

The third objective was to assess the effect of an opioid-antagonist (naloxegol) combined with oxycodone on colonic motility. Lastly, it was *hypothesized* that naloxegol in co-administration with opioids would normalize colonic motility. This was studied in healthy volunteers in an experimental setting. Measurements were performed during close-to-normal days, in two periods with either naloxegol co-administered with oxycodone or placebo co-administered with oxycodone.

The thesis is based on four papers (Paper I, II, and III are peer-reviewed) that compile data from four clinical trials. Study aims are shown in **Figure 5**.

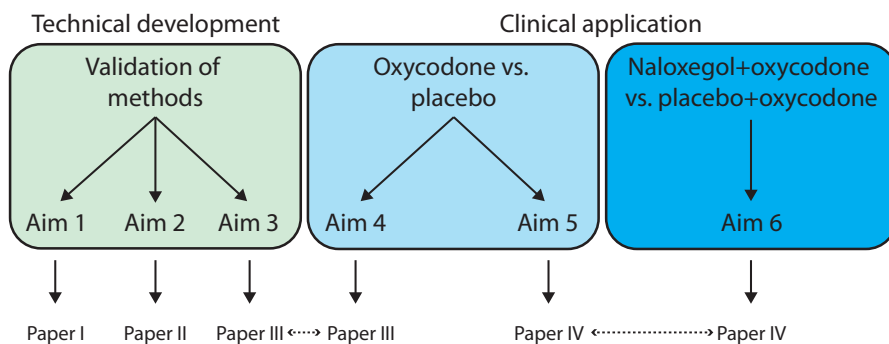


Figure 5. Overview of study aims and papers in the PhD thesis.

Aims

1. To develop, test reliability and validate a method to measure colonic length using the 3D-Transit system (Paper I).
2. To develop, test reliability and validate a method to measure detailed colonic motility using the 3D-Transit system (Paper II).
3. To develop and test reliability of a method to measure colonic fecal volume and colonic fecal dryness using MRI (Paper III).
4. To evaluate how oxycodone treatment, compared to placebo, affects colonic fecal volume and colonic fecal dryness (Paper III).
5. To evaluate how oxycodone treatment, compared to placebo, affects detailed colonic motility (Paper IV).
6. To evaluate how the opioid antagonist naloxegol co-administered with oxycodone, compared to placebo co-administered with oxycodone, affects detailed colonic motility (Paper IV).

CHAPTER 4. MATERIALS & METHODS

Colonic motility plays a dominant role in the cause of OIC, why the large intestine is a key segment to investigate in assessment of GI tract function. Research of the mechanisms behind the pathophysiology in the colon is therefore highly needed. To enlighten this specific subject, colonic function and motility were investigated using data recorded in four clinical trials, which are described in the following section.

4.1. STUDY DESIGN

The four included clinical trials all include measurements using the 3D-Transit system, while only trial 3 includes MRI. Data from the four trials have been combined in the four included papers. See an overview of the study design in **Figure 6** and a description of the four included clinical trials in **Table 2**. Detailed descriptions are listed in the following sections. All trials were carried out in accordance with the principles of the European Community rules of Good Clinical Practice (GCP) and the Declaration of Helsinki. Written informed consent was obtained from all participants. Trial 1 and 2 were carried out at the Neurogastroenterology Unit, Department of Hepatology and Gastroenterology, Aarhus University Hospital, Denmark, while trial 3 and 4 were carried out at the research facilities of Mech-Sense, Aalborg University

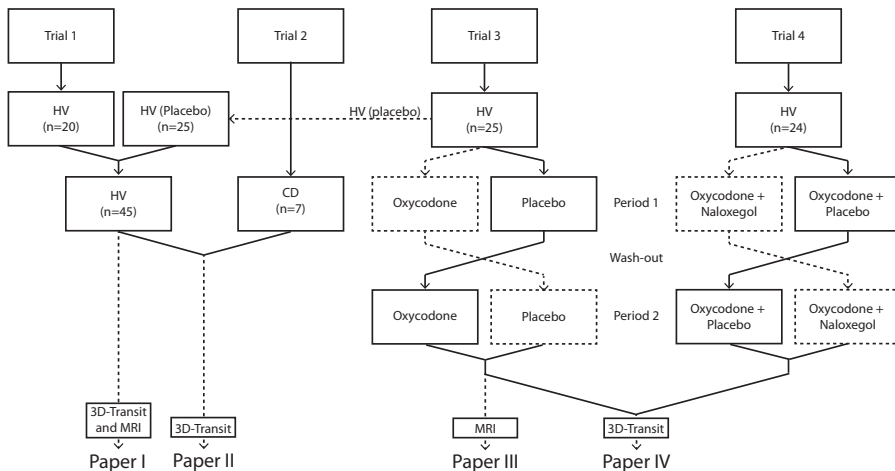


Figure 6. Overview of data from the four included clinical trials. Paper I combines data from trial 1 and 3 with the objective of developing and validating methods used to estimate colonic length. Paper II combines data from trial 1, 2 and 3 with the objective of developing and validating methods to describe detailed colonic motility. Paper III includes data from trial 3 to describe colonic content during opioid treatment. Paper IV includes data from trial 3 and 4 to describe detailed colonic motility during opioid and opioid antagonist treatments. Abbreviations: CD, patients with chronic diarrhea; HV, healthy volunteer; MRI, magnetic resonance imaging.

Hospital, Department of Gastroenterology & Hepatology, Aalborg, Denmark. The clinical trials did also include other end-points that are not part of the included papers and thereby not presented in this thesis.^{10,70,76–79} Development and validation of methods were performed using data from trial 1, 2, and 3, while the investigations of colonic function and detailed motility during pharmacological interventions were performed using data from trial 3 and 4.

	Subjects	Study design	Period length	Treatment	Included measures	Ethical reference no.	Danish Health and Medicines Authority	Research facility
Trial 1. <i>Paper: I, II</i> <i>Aim: 1,2</i>	HV (n=20)	Cross-sectional	1 x 5 days	None	3D-Transit	M-2010-0267	2011-123594	Aarhus University Hospital, DK
Trial 2 <i>Paper: II</i> <i>Aim: 2</i>	CD (n=7)	Cross-sectional	1 x 5 days	None	3D-Transit	-	2012-00393927	Aarhus University Hospital, DK
Trial 3 <i>Paper: I-III</i> <i>Aim: 1-5</i>	HV (n=25)	Cross-over	2 x 5 days	Oxycodone vs placebo	3D-Transit and MRI	N-2013-0030	2013-070299	Aalborg University Hospital, DK
Trial 4 <i>Paper: IV</i> <i>Aim: 6</i>	HV (n=24)	Cross-over	2 x 6 days	Oxycodone+ naloxegol vs. oxycodone+ placebo	3D-Transit	N-2015-0014	2015-021429	Aalborg University Hospital, DK

Table 2. Overview of the four trials included in the thesis. Abbreviations: no, number; HV, healthy volunteers; CD, patients with chronic diarrhea; MRI, magnetic resonance imaging.

Trial 1

Trial 1 included 3D-Transit recordings of 20 healthy volunteers studied with three capsules on two consecutive days (**Figure 7**). All healthy volunteers swallowed a capsule on completion of a standardized meal at 08:00. They also swallowed capsules at 18:30 on day 1 and 08:00 on the morning of day 2. Recordings continued until the capsules were evacuated.

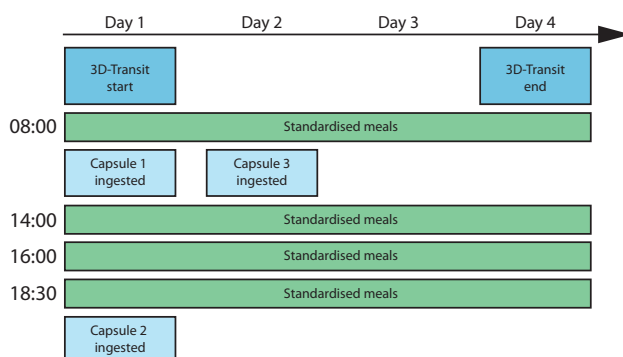


Figure 7. Overview on 3D-Transit capsule and meal ingestion times in trial 1.

Trial 2

Seven patients with pathology verified metastatic neuroendocrine tumors and carcinoid diarrhea were studied with one 3D-Transit capsule swallowed in the morning on completion of a standardized meal. The patients stayed at the hospital during the examination (**Figure 8**).




Figure 8. Overview on 3D-Transit recording time line in trial 2.

Trial 3

Trial 3 included 3D-Transit recordings and MRI scans in 25 healthy volunteers. Participants were studied in two study periods of five days each, where they were treated with either oxycodone or matching placebo (**Figure 9**). MRI was performed before first treatment dose on day 1 and after last dose on day 5. Capsules were ingested after the MRI scan on the first study day after a standardized meal.

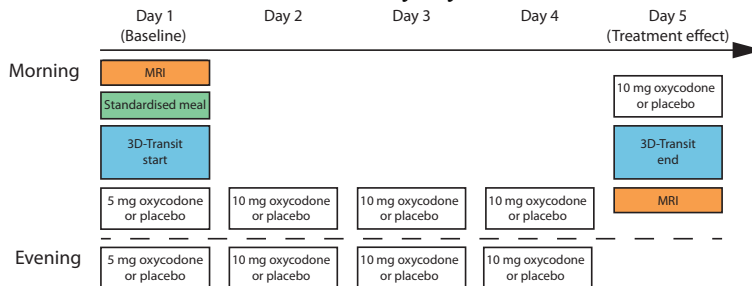


Figure 9. Overview on one five-day treatment period in trial 3.

Trial 4

Twenty-four healthy volunteers were studied with 3D-Transit in two study periods of six days each. They were treated with either combined oxycodone plus naloxegol or combined oxycodone plus placebo (**Figure 10**). 3D-Transit capsules were ingested on the second study day in each period after a standardized meal.

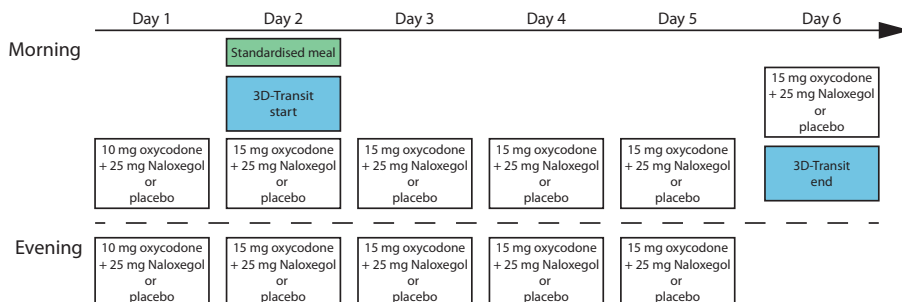


Figure 10. Overview on one six-day treatment period in trial 4.

4.2. THE 3D-TRANSIT SYSTEM

Colonic motility is quantified using the 3D-Transit system (Motilis Medica SA, Lausanne, Switzerland, www.motilis.com).^{20,70,71,79} The system consists of a detector plate worn in an abdominal belt that tracks small ingestible electromagnetic capsules, through their GI passage (**Figure 11**). The system can record data from passage through the stomach, small intestine and the colon. This thesis only contains data recorded in the colon, why examinations of other parts of the GI tract will not be discussed. The capsules emit an electromagnetic field that is tracked by four sensors inside the detector plate and the capsule battery allows for approximately 5 days recording with a 5 Hz sampling frequency. Additionally, breathing is recorded with a respiratory chest-worn belt and accelerations of the detector are recorded with an accelerometer. These data are useful when assessing data quality. The 3D-Transit system has previous been used to report segmental GI transit times,^{10,70,79–81} however an earlier version of the capsule system (MTS-1) was used to describe and quantify colonic motility.³⁶ The MTS-1 version of the capsule system relied on a permanent magnet and only allowed for stationary recordings, where the subject was positioned in a wooden bed at the research facility.^{82–85} The resulting colonic motility data reported by Hiroz et al., 2009 were unique, however the system had limited applicability due to its non-ambulatory nature.³⁶ The methods used to analyze the colonic recordings were never translated from the older version, why that specific task was included in the current thesis.

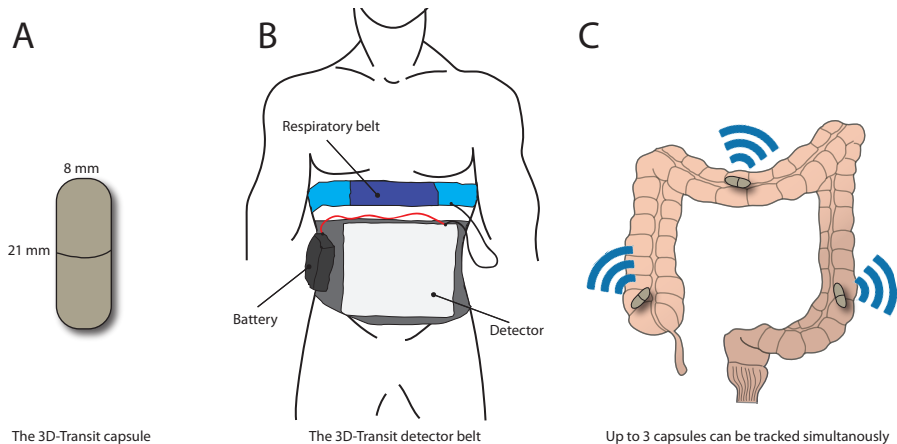


Figure 11. Overview of elements in the 3D-Transit system. A) Capsule size. Each capsule has a density of 1.6 g/cm^3 . B) The detector plate is worn in an abdominal belt and tracks the capsules through their gastrointestinal passage. The plate is powered by an external battery, and breathing is recorded from the respiratory belt. C) The capsules emit an electromagnetic field that can be translated into positional data.

4.2.1. ANALYSIS PIPELINE FOR COLONIC MOTILITY

A five-step analysis pipeline for colonic motility analysis was set up (**Figure 12**). The following sections will shortly present each step that was performed before quantification of capsule movement was possible.

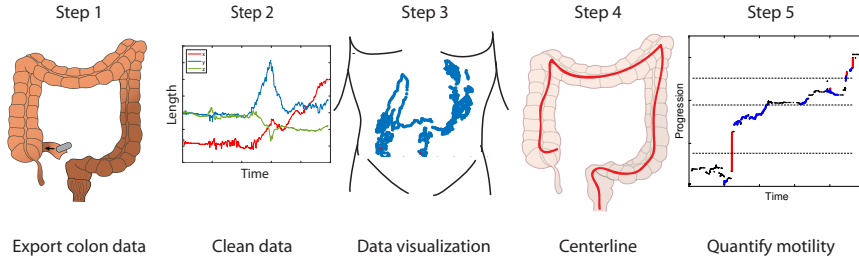


Figure 12: The five steps in the analysis of 3D-Transit data.

Step 1: Locating colonic data

Recordings in the large intestine were located in the native 3D-Transit software using a previous proposed procedure that locates a decline in bowel wall contraction frequency (represented by capsule rotations) from approximately 10 CPM in the ileum to approximately 3 CPM in the cecum, along with the capsule located in the lower left quadrant in the frontal view of the recording (**Figure 13**). This approach has been used in all previous studies using the 3D-Transit system.^{10,70,77,79–81,86,87} Colonic data was then exported for further analysis.

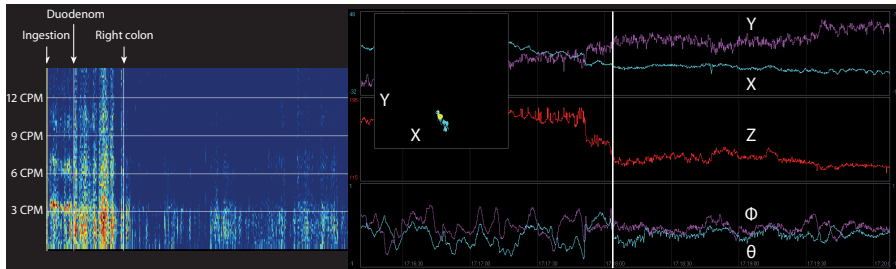


Figure 13: The 3D-Transit software. Capsule passage through the ileocecal valve was located as a drop in contraction frequency (left) and a position in the lower abdomen (middle). The white vertical line (right) marks the capsule passage seen as a change in the capsule rotations (Φ and θ) and position (X , Y , Z). Abbreviations: CPM, contractions per minute.

Step 2: Clean data

The 3D-Transit system records capsule progression in the gut. However, as the system is worn throughout the day at home during normal activities some problems with data quality arises. The detector is placed in a tight belt around the abdomen, but the belt can move itself in relation to the body. Capsule position is calculated in relation to the detector, why movements of the detector can look like capsule movements and potentially will be falsely classified as GI movements. The events causing these problems could be e.g. physical activity like running and fast posture changes.

Furthermore, electronic interference from larger electronic devices could cause data loss. In order to assess data quality and remove artifacts from recordings, a graphical user interface (GUI) was implemented in MATLAB (MathWorks Inc, Natick, MA, USA) version R2016a (**Figure 14** and **Figure 15**). Data was

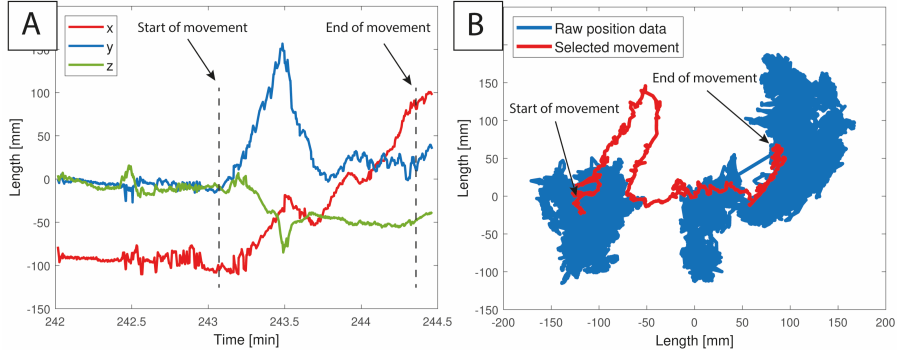


Figure 14. Graphical user interface for data cleaning. An algorithm finds a long movement that moves the capsule from the ascending colon and across the transverse colon. The movement is shown with dashed lines in a time and position plot (A) and with red color in a frontal plot of the X, and Y positional data (B).

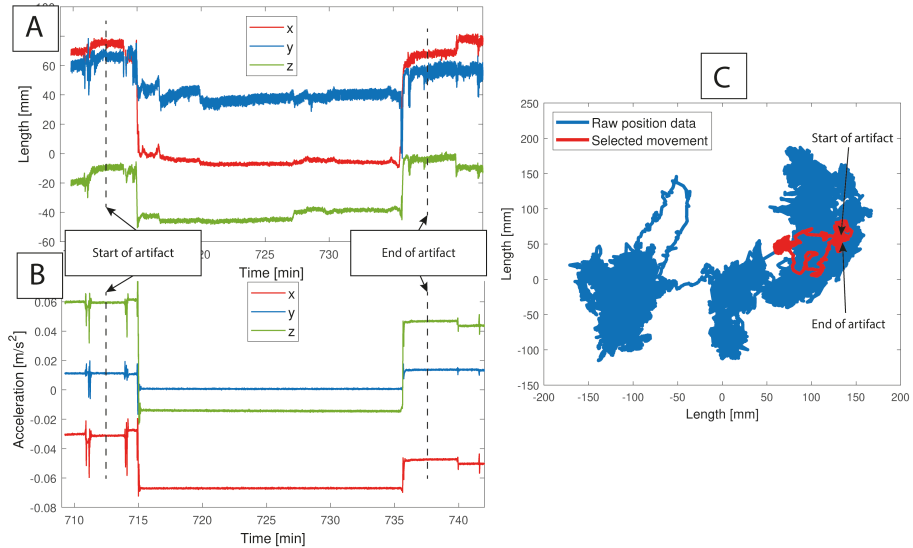


Figure 15. Marking of an artefact. (A) Time and position plot. The artifact is caused by a change in position (from posture changes) during nighttime. (B) Time and acceleration plot. The acceleration of the detector plate helps to separate real capsule movements from movements of the detector plate. The change in acceleration in X, Y and Z direction are aligned with the position data. (C) Frontal plot of X and Y position. The capsule ends up at the same position after the 20 minutes marked artifact. The artifacts can look like real GI movements, and they can be difficult to classify without the acceleration information.

automatically assessed and periods with bad data quality were excluded using the implemented GUI. The parameters used for this task were 1) high variation in capsule position, 2) high acceleration of the detector plate, and 3) low signal strength. Then an algorithm located all movements of the capsule (in relation to the detector) that were more than 4 cm with an average velocity of 4 cm in any direction. Approximately 90% of these located movements are artifacts and in the current analysis pipeline, they need manual assessment of being real GI movement or not. In **Figure 14** and **Figure 15** a GI movement and an artifact are shown. The GUI presents the located movements one at a time, and the observer is prompted to discard the artifacts, a task lasting approximately 20 minutes for a normal length dataset.

Step 3: Visualization of capsule position

After cleaning the capsule position data from artifacts, the data is down-sampled to allow for easier visualization and analysis. Two principles were applied to allow for visualization of both slow and fast capsule movements, 1) the distance from one datapoint to the next should not exceed 5 mm, 2) the time between one datapoint to the next should not exceed 3 minutes (**Figure 16**). These parameters represented data well and were close to what was used in the previous version of the system.³⁶ Changes in the parameters will slightly change the analysis outcome. After visualization of data in the GUI, it is possible to extract the time points for when the capsule was in the hepatic flexure, in the splenic flexure, and in the sigmoid flexure. Thereby, segmental colonic transit times for the cecum/ascending-, transverse-, descending- and rectosigmoid colon are found.

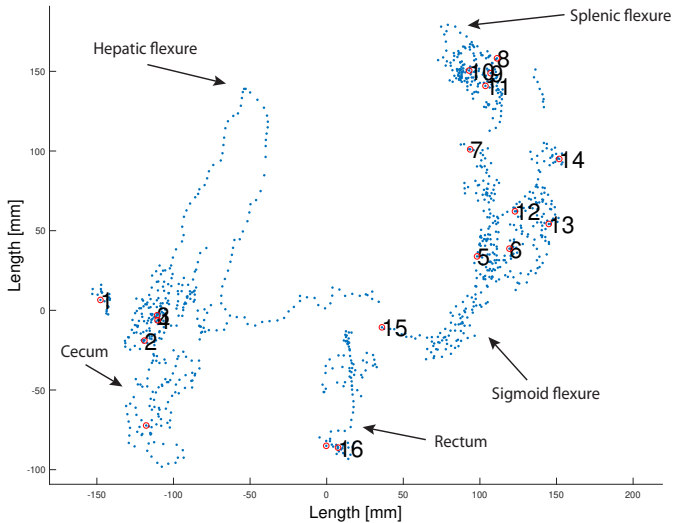


Figure 16. Visualization of the colonic passage. 3D positional data has been down-sampled to show a datapoint for either 5 mm progression or 3 minutes with no movement (blue dots). Each hour of progression is marked with a red circle and an Arabic number. Segmental landmarks are placed at the hepatic flexure, splenic flexure and sigmoid flexure.

Step 4: Centerline of the colon

A centerline through the colon was estimated with the purpose of having an anatomical guidance to compare capsule movement direction with. The line was estimated using an algorithm like the one used in the visualization of data. The principles were: 1) the distance from one datapoint to the next should not exceed 5 mm, 2) the next data point should be nearer the next landmark (i.e. the hepatic flexure, the splenic flexure, sigmoid flexure, end of recording) than the previous. The time between points are not relevant in this estimation. The algorithm needs manual evaluation and adjustments if the dataset includes bad data points that is missed in previous steps. Lastly, the line is low pass filtered (2nd order Butterworth filter with a cut off at 0.05 Hz) to adjust for respiratory artifacts. The length of the estimated centerline now represents the antegrade passage of the capsule through the colon, which is used as the length of the colon in the following calculation of capsule displacements (**Figure 17**). The anatomy of the colon can be reproduced with a high spatial resolution using MRI. In trial 3 the healthy volunteers underwent MRI examinations the same day that 3D-Transit recordings were started. The colonic volume was segmented on each dataset, and a 3D topological skeleton algorithm was applied to the colonic segmentation masks and the medial path of each volume was extracted. The lengths of the estimated colonic centerlines were validated using two approaches (Paper I);⁷¹ 1) compare estimated lengths against MRI segmentations in the same subjects, and 2) compare length between recordings performed on two consecutive days in the same subjects.

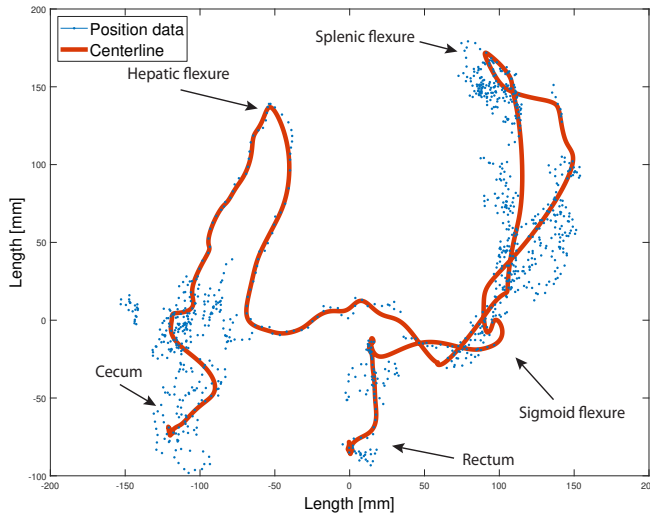


Figure 17. A centerline representing colon anatomy is produced. The shown centerline is 150 cm and it is used in the analysis of capsule movement.

Step 5: Quantify motility

Capsule movements relative to the colonic centerline were calculated by projecting the 3D-position data onto the line (**Figure 18**). Movements were located and classified according to length of displacement, velocity and direction of the movement. The applied parameters were inspired by the study by Hiroz et al., 2009,³⁶ and can be seen in **Table 3**. To validate the proposed method to investigate colonic motility (Paper II), two approaches were used: 1) Compare recordings for the same subjects on two consecutive days, and 2) compare motility measures of a healthy group with patients who had known chronic diarrhea.

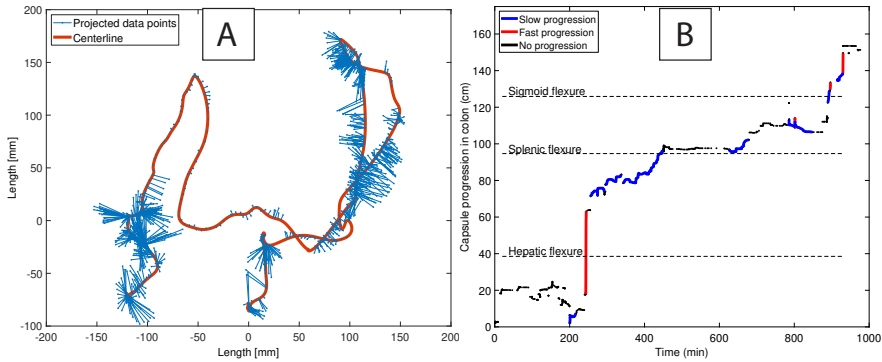


Figure 18. Quantification of colonic motility. A) Positional data are projected onto the colon centerline at the point with lowest 3-dimensional distance between line and data point. B) Capsule movements relative to the centerline are located and visualized as time vs. colonic progression. Red lines represent fast movements and blue lines represent slow movements.

Movement pattern	Displacement upper limit	Displacement lower limit	Mean velocity upper limit	Mean velocity lower limit
Mass movement	-	>10 cm	-	>10 cm/min
Fast antegrade	<10 cm	>4 cm	-	>4 cm/min
Slow antegrade	-	>4 cm	<4 cm/min	>4 cm/hour
Fast retrograde	-	<-4 cm	-	>4 cm/min
Slow retrograde	-	<-4 cm	<4 cm/min	>4 cm/hour

Table 3. The five identified colonic movement patterns.

4.3. MRI-BASED MEASUREMENTS

Colonic content was assessed using an MRI-based method (Paper III) written in MATLAB version R2013b. The method was firstly introduced in the study by Sandberg et al., 2015,⁸⁸ and has previously been used to quantify colonic volumes.^{76–78} The method has been further developed in the current thesis and now allows for analysis of content.

4.3.1. ANALYSIS PIPELINE FOR MRI MEASURES

Fecal volumes and stool dryness were estimated in four steps and will be shortly described in the following sections (*Figure 19*).

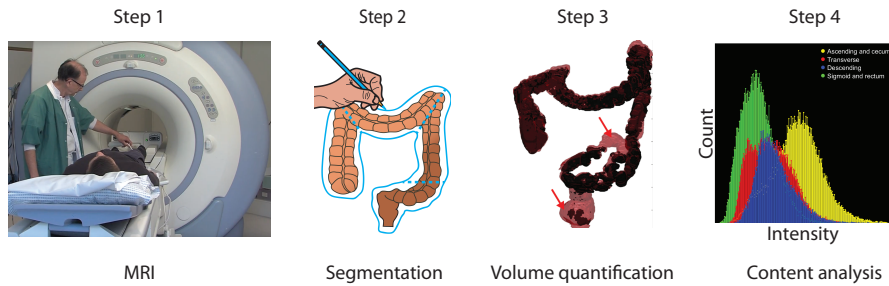


Figure 19. The four analysis steps included for MRI-based analysis of colonic fecal content and stool dryness.

Step 1: Magnetic Resonance Imaging

Subjects were scanned using a 1.5T GE Discovery MR450 System (GE Healthcare, Milwaukee, WI, USA). Experiments included two coronal image series of the abdomen: 1) a T2-weighted single shot fast spin echo scan and 2) a T1-weighted Dixon-type liver accelerated volume acquisition (LAVA-Flex) scan. The T2-weighted sequence shows a good contrast between the colon anatomy and surrounding tissue (e.g. abdominal fat), and in the current analysis method it is used for segmentation of colon volume and assess the amount of water in the colonic content. The segmented volume includes both content and luminal gas. The LAVA-Flex sequence shows good contrast between solid colonic content and luminal gas. In the current analysis method, it is used for segmentation of fecal volume. In Paper III, it was also proposed to include the LAVA-Flex images for analysis of water in the colonic content, however the T2-weighted images proved to perform better, why the LAVA-Flex measured stool dryness is not presented in this thesis. Detailed description of MRI parameters is shown in Paper III.

Step 2: Segmentation

Colonic volumes were subtracted from the T2-weighted images using a segmentation platform which allows the user to draw a line around the colon and divide the volume in colonic segments (**Figure 20**). Segments are separated at the hepatic flexure, the splenic flexure and at the left anterior iliac spine, which divide the colonic volume into the four segments: 1) cecum and ascending colon, 2) transverse colon, 3) descending colon, and 4) rectosigmoid. A trained observer uses approximately 20-30 minutes in the manual segmentation process depending on image quality and individual anatomy.

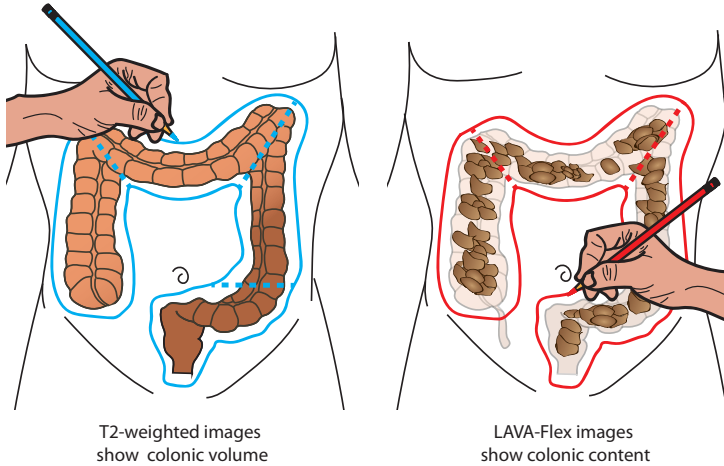


Figure 20. Schematic representation of the manual segmentation of colonic segments on T2-weighted images (left) and LAVA-Flex images (right). Colonic segments are separated by the hepatic flexure, the splenic flexure and at the left anterior iliac spine. Illustration inspired by Alyami et al., 2015.⁸⁹

Step 3: Volume quantification

After manual segmentation on the two MRI image series, the software classifies all voxels according to their signal intensity using the k-means clustering algorithm initiated with three random cluster centers. Non-colon voxels (on T2-weighted images) and non-colon content voxels (on LAVA-Flex images) are discarded by the algorithm (**Figure 21**). Wrongfully classified areas can afterwards be corrected by the observer. Reliability of the colonic fecal volumes were assessed by comparing measurements performed at the two baseline days in trial 3 (Paper III).

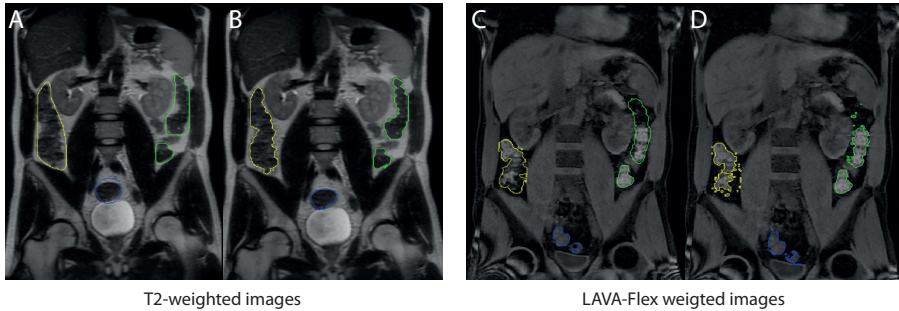


Figure 21. Classification of colonic volume and colonic content using a k-means clustering algorithm. Ascending colon is yellow, descending colon is green, and sigmoid colon is blue. A) Manual drawn region on a T2-weighted image. B) Classified colonic volume on a T2-weighted image. C) Manual drawn region on a LAVA-Flex image. D) Classified colonic content on a LAVA-Flex image.

Step 4: Analysis of colonic content

The median T2-weighted signal intensity of the segmented colonic content was used as a simple measure of colonic stool dryness. On the T2-weighted images, water is represented as very bright (high signal intensity), while dry feces were hypothesized to be represented as dark (low signal intensity). This hypothesis was tested in a simple setup, where the signal intensity of different mixes of oatmeal and amount of water was estimated using the same scanning sequence (Paper III). The luminal gas is however darker than feces, why the volume of gas pockets need to be subtracted before analysis of the MRI signal intensities in order to avoid introducing a bias in results. The difference in volume between colonic content (shown in LAVA-Flex images) and colonic volume (shown in T2-weighted images) is equal to the luminal gas volume.⁹⁰ Voxels representing gas volume in the T2-weighted images were then discarded based upon analysis of signal intensity, and the median T2-weighted signal intensity was computed and used as a proxy for colonic stool dryness (**Figure 22**).

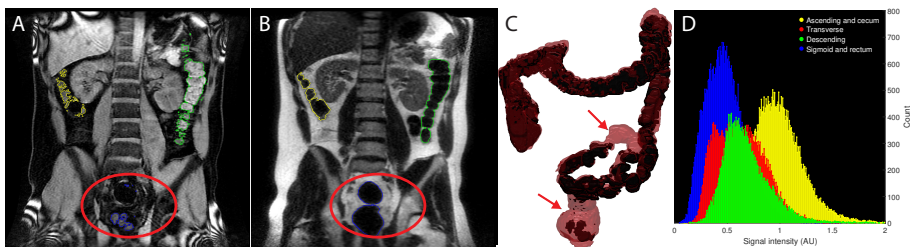


Figure 22. Analysis of colonic content. A) LAVA-Flex image showing area in the rectosigmoid colon with luminal gas. B) T2-weighted image showing area in the rectosigmoid colon with luminal gas. C) 3D-model of the segmented colonic volume and content. Arrows point to luminal gas. D) Histogram representation of segmented colonic content on T2-weighted images in one dataset. High values indicate more water content, where ascending colon content contain most water (yellow) and rectosigmoid colon contains least water (blue).

CHAPTER 5. KEY RESULTS

The key results to answer the six aims are presented in this chapter. Detailed results are reported in the papers. An overview of the main results is illustrated in **Figure 23**.

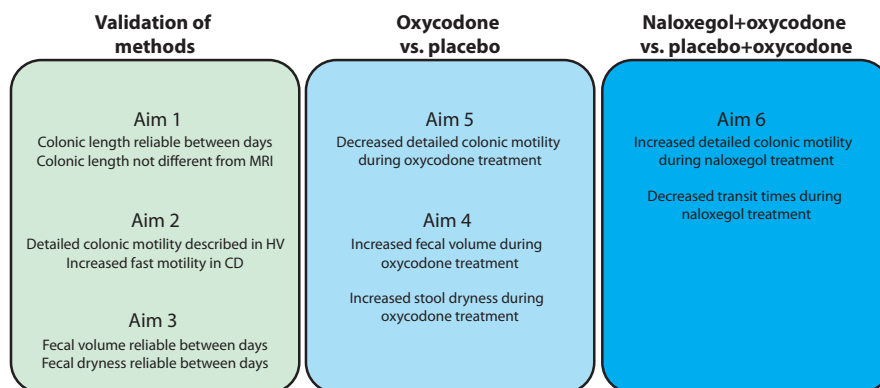


Figure 23: Overview on key results included from the four papers (I-IV). Abbreviations: CD, patients with chronic diarrhea; HV, healthy volunteers

5.1. AIM 1

Aim: To develop, test reliability and validate a method to measure colonic length using the 3D-Transit system (Paper I).

Key results:

- Colonic length measured with 3D-Transit was 95 (75-153) cm and was not different from MRI derived measures ($P = 0.15$).
- The coefficient of variation (CV) between MRI and 3D-Transit measured colonic length was 7.8%.

Interpretation

It was possible to develop a method to measure colonic length using the 3D-Transit system. Colon length estimated with the system was validated against known colon anatomy derived using MRI.

5.2. AIM 2

Aim: To develop, test reliability and validate a method to measure detailed colonic motility using the 3D-Transit system (Paper II).

Key results:

- Total colonic transit and motility measures showed high variation between measurements performed on two consecutive days with a coefficient of variation ranging from 31-61%,
- Propulsive velocity peaked at 0.5 cm/min (retrograde or antegrade) and at 50 cm/min (antegrade).
- The capsule progressed faster during the day than at night (5.9 cm/h vs. 0.8 cm/h; $P < 0.01$).
- Capsule velocity was faster in patients with diarrhea compared to healthy volunteers (20.4 cm/h vs. 4.4 cm/h; $P < 0.01$).

Interpretation

It was possible to develop a method to measure colonic motility. The length of the colon was used as a guidance for tracking 3D-Transit capsule movement length, velocity and direction. Measurements of colonic motility in healthy volunteers showed that the capsule was moved in five different types of movements of varying length, velocity and direction. Patients with diarrhea had an faster movement pattern.

5.3. AIM 3

Aim: To develop and test reliability of a method to measure colonic fecal volume and colonic fecal dryness using MRI (Paper III).

Key results:

- Segmental and colonic fecal volumes showed moderate to good reliability between week-to-week measurements (all $P < 0.005$, all ICC > 0.52).
- Segmental and colonic stool dryness assessed with T2-weighted MRI showed poor reliability between week-to-week measurements of the ascending-, descending-, and sigmoid colon (all $P < 0.01$); measurement of the transverse- and total colon showed moderate to strong reliability (both $P < 0.002$).

Interpretation

It was possible to develop a method to estimate colonic fecal volume and stool dryness. Measures of colonic fecal volume was consistent between measurements separated by weeks, and variation can partly be explained by physiological factors and diets.

5.4. AIM 4

Aim: To evaluate how oxycodone treatment, compared to placebo, affects colonic fecal volume and colonic fecal dryness (Paper III).

Key results:

- Oxycodone increased total colonic fecal volume ($P = 0.001$) with largest volume increase during treatment observed in the ascending colon ($P = 0.004$).
- Colonic stool dryness assessed with T2-weighted images increased during oxycodone treatment compared to placebo ($P = 0.002$) with highest difference in the descending colon ($P = 0.03$).

Interpretation

Five days of oxycodone treatment increases colonic fecal volumes and reduces the amount of water in the colonic content.

5.5. AIM 5

Aim: To evaluate how oxycodone treatment, compared to placebo, affects detailed colonic motility (Paper IV).

Key results:

- Colonic transit time increased during oxycodone treatment compared to placebo ($P < 0.01$); with slowest transit in the ascending colon ($P = 0.03$).
- Oxycodone treatment impaired the number of long fast antegrade movements ($P < 0.001$), with most difference in the descending colon ($P < 0.04$).
- Oxycodone increased the number of slow antegrade movements compared to placebo ($P = 0.002$).

Interpretation

Oxycodone treatment slows colonic transit, mostly caused by a reduced number of the long fast antegrade movements (mass movements), and an increased number of slower movements.

5.6. AIM 6

Aim: To evaluate how the opioid antagonist naloxegol co-administered with oxycodone, compared to placebo co-administered with oxycodone, affects detailed colonic motility (Paper IV).

Key results:

- Colonic transit time was faster during oxycodone+naloxegol compared to oxycodone+placebo ($P = 0.049$); with most difference seen in the sigmoid colon ($P < 0.001$).
- The number of slow antegrade movements was higher during oxycodone+placebo than during oxycodone+naloxegol ($P = 0.03$).
- More distance was covered in fast antegrade movements during oxycodone+naloxegol than during oxycodone+placebo ($P = 0.04$).

Interpretation

Naloxegol (combined with oxycodone) returns transit time and colonic motor activity towards normality, but not entirely.

CHAPTER 6. DISCUSSION

The overall objective of the present PhD thesis was to develop and apply methods to assess the effect of opioids on colonic motility, fecal volume and fecal dryness, and to assess the effect of opioid antagonists co-administered with opioids on colonic motility. The discussion is divided in two parts. The first part focuses on the methodological considerations of the applied methods, after which the advantages and drawbacks of the experimental settings will be discussed.

6.1. METHODOLOGICAL CONSIDERATIONS

6.1.1. 3D-TRANSIT

The 3D-Transit system offers many possibilities in regarding to analysis of GI function and motility and provide information that cannot be obtained with other measurement techniques. The system tracks electromagnetic capsules through the GI passage and allows for assessment of capsule movement in real time with a high temporal resolution. The ‘novelty’ of the system is that it accurately describes intraluminal movement (at least of an indigestible capsule), which is the functional consequence of contractile events. The first schematic representations of colonic motor patterns were obtained in the studies by Ritchie in the 1960’s using radiological methods.^{91,92} A lot have happened since then in regards to safe measurement techniques. Now we can describe contractile activity using the WMC, but unfortunately, this capsule cannot be accurately tracked through colonic transit. Together with high-resolution colonic manometry, which has added most of the current knowledge of colonic motor patterns, the 3D-Transit system is a complementary assessment tool enabling insight into the various colonic movements, despite the limitations of the system. In the current thesis, the 3D-Transit system was used to analyze both colonic length and motor patterns including segmental colonic transit times. Algorithms, parameters and settings were inspired by the study by Hiroz et al., 2009.³⁶ A new analysis platform was implemented to clean data and classify motor patterns.

Colonic length

Estimations of colonic length were performed as a step on the way to describe colonic motility patterns. The proposed method was found to produce overall good reliability between estimations performed on two consecutive days, and between 3D-Transit and MRI-derived measurements.⁷¹ The estimations in the ascending colon proved to be most problematic, as in some recordings, the capsule either stayed in the cecum for a long period, or it progressed fast after it entered the colon and would never fall into the cecum pouch. The anatomy of the ascending colon shown on the MRI images (used for comparison) also differed, which may be caused by contractions and

relaxations that affects colonic length,⁴³ and diets and bowel movements also have an impact on the volume of the colon.^{78,90} Colonic length is not a clinical used parameter, why it can be difficult to validate the method against any gold standard. Several methods to measure colonic length have been proposed e.g. using swallowed tubes or measure the inserted length of a colonoscope during colonoscopy.^{21,93} These approaches may however underestimate true colonic length due to the confounding ‘concertina’ effect when inserting the catheter.⁹⁴ Imaging techniques can be used without this limitation (depending on the type of bowel preparation), why MRI was chosen as validation method in this thesis. Measurements of colonic length alone have also been performed using a manual approach by drawing on abdominal radiographs after bowel preparation with rectal injected barium.⁹⁵ The method used to extract colonic length from MRI images was, however, not a validated method, which of course limits the validity of findings (Paper I). The same analysis approach was used for all images, and due to the good contrast between colon and surrounding tissue in the T2-weighted images, it was easy to inspect the centerline produced by the algorithm (and redo if failed). Measures of colonic length may have clinical applications as an elongated colon is associated with prolonged transit in both children and adults.^{96,97} The 3D-Transit system is however an unpractical approach to measure colonic length, while imaging of the colon can be performed much faster (20 seconds MRI vs. approximately 24 hours normal GI transit time), and the imaging data is easier and faster to interpret. The length measure proposed in this thesis is used in the further progress to calculate capsule movements; hence, it will be calculated as part of the full colonic motility analysis, and estimation of the length alone does not make much practical sense.

Detailed colonic motility

There exist only few other methods to investigate colonic motility, where HRM has introduced much of the current knowledge on colonic motor patterns in health and GI disease.^{32,33} HRM measures luminal pressure waves unlike the 3D-Transit system that provides insight into how luminal content progresses (and stands still) through the colonic transit. Two recordings of similar transit time can have very different progression patterns as shown in Paper II, where one pattern shows slow progression through the colon, and another shows that capsule progression is mainly caused by two very long and fast mass movements.²⁰ This information cannot be obtained with other motility capsules. Motility capsule systems do, however, include other limitations, where one of the most significant is the very high variation in colonic motility that is difficult to interpret using a single capsule. The anatomical location of radiopaque markers often differs between colonic segments, why it is normal to track 10 markers during an examination, and calculate a colonic transit time based on a scoring system.⁹⁸ The 3D-Transit system offers possibility to track 3 capsules simultaneously, although interpretation of results may be more complicated. Paper II included analysis of healthy volunteers that ingested three capsules over two days (morning day 1, evening day 1, and morning day 2). Variation in colonic motility during normal days, even with standardized diets was very high. In fact, total colonic

transit and motility measurements in the healthy volunteers all had coefficient of variation ranging from 31-61%, which must be regarded as high intra-subject variation.²⁰ Colonic activity was higher during daytime compared to nighttime. A peak in colonic activity was also observed during mornings, however, it was not possible to show a significant effect of meals, which has been shown previously.^{32,36,37} Colonic transit times was longer in recordings, where the capsule was ingested in the evening.²⁰ This is not surprising as defecation is normally performed in the mornings, and the evening-ingested capsule would often be located in the proximal colon the following morning, why it stayed in the colon and awaited toilet visit next morning 36 hours after ingestion. This specific finding was also reported in a WMC study of 215 healthy volunteers made by Wang et al.⁷² They discovered that the WMC was often expelled in the mornings, and when it was not, the capsule was often expelled 24 hours later. This makes a bimodal distribution in normal transit times with 1 day between peaks. The capsule would most likely await expulsion in the sigmoid or rectum, which cannot be known using the WMC, but easily investigated using the 3D-Transit system.

Motility analysis in healthy volunteers showed that the capsule traversed both at fast and slow velocities, at differing length and mostly antegrade, but also retrograde. The velocity of capsule movements in especially the long fast antegrade movements could be compared to the motor patterns described using HRM. Dinning et al. examined 10 healthy volunteers with HRM, and they found that high-amplitude propagating sequences (HAPS) propagated a mean 33 ± 12 cm (range 11-50 cm), with a mean velocity of 0.4 ± 0.1 cm/s.³² Furthermore, they reported another motor pattern called 'long single propagating motor pattern' with even faster progression velocity than HAPS. These movements propagated a mean 41 ± 8 cm, with a mean velocity of 1.8 ± 1.2 cm/s. The healthy 3D-Transit recordings reported in Paper II, did also include movements at high velocity, where most fast antegrade activity displaced the capsule at approximately 0.2-2.5 cm/s),²⁰ which implies that our classification most likely include more than one previous identified motor pattern. The 3D-Transit capsules do not include a pressure sensor, why it cannot be determined if the classified long and fast movements have high amplitude pressure events like in the HRM recorded HAPS. Future improvement of analysis may allow the system to distinguish between more types of motor patterns as reported by Dinning and colleagues, but a validation study between methods is needed before further conclusions on the relation between motor patterns can be made.

Motility analysis in healthy volunteers during oxycodone treatment (Paper IV) showed that colonic transit time was increased due to reduced efficacy and number of long fast antegrade movements that contributed to a slower capsule progression velocity. Moreover, the oxycodone treatment increased the number of short and slow antegrade movements and did not affect retrograde activity. This means that the opioids slowed propulsion but did not cause any dyscoordinated peristalsis; at least not enough to be found with the current analysis methods. Dyscoordinated peristalsis is however believed to contribute to the pathophysiology underlying OIC,⁹⁹ why it was also hypothesized that oxycodone would cause this phenomenon. Naloxegol in

co-administration with oxycodone did not normalize colonic transit entirely nor did it return the number of long fast movements to the levels reported in the placebo-arm in Paper IV and the healthy population in Paper II. However, when naloxegol was combined with oxycodone, transit time was significantly reduced, especially in the rectosigmoid colon, compared to oxycodone treatment alone. This may be due to the change in motor patterns between the two treatments, where the capsule was moved significantly longer in the short fast movements during naloxegol and there was less of the slow antegrade movements that was found to be caused by oxycodone treatment (Paper IV). The increase in fast movements during naloxegol was mainly in the distal colon, which could coincide with the decreased transit time in the rectosigmoid.

Previous, the system has mostly been used to report regional transit times,^{10,80,81} however, manual assessments of ‘pansegmental colonic movements’ have also been included in a study by Gregersen et al.⁷⁹ Furthermore, analysis of GI motility in healthy volunteers during sleep has also been reported in a study by Haase et al. using another approach than the one used in the current thesis.⁸⁶ They assessed gastric contraction frequency using power spectral analysis, and estimated small bowel and colonic propagating sequences (like the ones presented in the current thesis) and colonic activity for short movement periods. Their approach inspired the analysis methods implemented to estimate colonic motility in the current thesis, and the authors in that study also contributed to Paper I, II and IV. The study by Hiroz et al., 2009 compared colonic transit times measured with the previous version of the motility capsule system with standard radiopaque markers,³⁶ where about 60% of the markers were clustered in the zone of the capsule. Worsøe et al. measured gastric and small bowel transit times with the PillCam and compared with the previous capsule system and found a good agreement between measurements.⁸² Total transit time measured with the current system was in the study by Haase et al. compared with radiopaque markers, and they found a positive correlation (Spearman’s $\rho = 0.7$).⁷⁰ However, it is also important to test how results vary among different observers. Haase et al. also found that the inter-rater reliability of assessed transit times was very good, although the observers helped each other during analysis, and they were not blinded to previous analysis of the same data. Kalsi et al. tested both intra- and inter-rater reliability in a blinded setup, with three observers with varying experience in analysis.⁸⁷ They found that the level of experience had an impact on results, and the observer with the lowest level of experience reported regional transit times with very low reliability. All colonic motility measurements presented in this thesis have been performed by a single trained observer. All steps in the analysis may potentially impact the reported results, why reliability studies of the proposed colonic motility measurements are warranted. It would also be very interesting to compare the new motility measures with motor patterns obtained during simultaneous recordings with high-resolution colonic manometry.

6.1.2. MAGNETIC RESONANCE IMAGING

Fecal volume and stool dryness data were obtained with MRI to provide additional insight into the functional state of the colon. The 3D-Transit capsule offers measures of motor function through estimations of motility and transit times, while MRI offers indirect measures of gut secretion and absorption. However, a single measurement of volume does not provide much useful information, because individual measures of colonic volume have high variation,⁷⁸ which makes it difficult to determine abnormal values. The measure is more useful if performed several times during a time period to e.g. assess treatment effects (Paper IV). Insight into the luminal content and its water amount would provide another useful layer of information. In the current thesis, analysis methods to extract this information was proposed. In Paper III, MRI was used to detect the effect of oxycodone on colonic fecal volume and stool dryness. The used MRI methods allow for a more detailed description of colonic physiology than colonic volume alone. The method can detect fecal composition, and dry feces may itself lead to constipation symptoms.

Colonic fecal volume and stool dryness during treatment with oxycodone and naloxegol

A five-day treatment of oxycodone increased total colonic fecal volume with the highest increase in the proximal colon and surprisingly no change in the rectosigmoid. The 3D-Transit system detected increased transit times during the oxycodone treatment (most pronounced proximal), why the stable fecal volume in the distal colon may be explained by the increased time of passive fluid absorption during colonic passage. This phenomenon is further supported by the measure of stool dryness that detected a change in chyme signal intensity between treatments. Lastly, the subjects also reported their stool to be drier and harder during oxycodone treatment (not part of this thesis, but reported in a study by Nilsson et al.).⁷⁶ Investigations of evacuation function would furthermore be very useful to help us understand why subjects accumulated more feces in the colon during oxycodone treatment compared to placebo. Although, no change was observed in the sigmoid colon, why it can only be speculated how much the mechano-sensitive reflex (that promotes the urge of defecation) is affected by the treatment. Morphine has although previously been found to increase the elicitation threshold for the recto-anal inhibitory reflex.¹⁰⁰ The accumulation of feces in the proximal colon during oxycodone treatment may be further explained by the insight into colonic motility obtained with the 3D-Transit capsule. The system detects long propagating movements that include the powerful HAPSs (normally detected using HRM). These are believed to originate in the ascending colon and propagate through most of the colon a few times each day.³² During oxycodone treatment, much less long fast movements were detected, which could explain the increase in fecal volume in the ascending colon, when the long movements do not propagate the feces as often due to the opioid-induced GI symptoms. This is also the case in slow transit constipation,³³ why the pathophysiology underlying OIC may mirror other GI disease. Variation between

volumes and stool dryness of colonic fecal content measured at the baseline days in Paper III (separated by a mean of 52 days) could partly be explained by diets and normal variation.⁹⁰ Measurements might have shown higher reliability if they were performed on two following days and if subjects were on standardized diets through the study. Analysis was performed by a single observer, however the segmentation method has previously been tested with two observers with low inter-observer variation, why further testing of the methods was not performed.⁷⁸ A recent study by Major et al., 2018 also used MRI to assess water content in the colon content, and their results correlated well with the actual amount of water in feces (using a freeze drying procedure).¹⁰¹ It is a great limitation of the method applied in Paper III that no actual validation against known water amount was made. The method did show an effect of the oxycodone treatment on the appearance of the luminal content; however, it may be speculated if this change is due to reduced amount of water as it may as well be caused by increased fermentation or something entirely else.

6.2. EXPERIMENTAL SETTINGS

Pharmacological treatments

The administered treatment doses of oxycodone in trial 3 were chosen based upon what was hypothesized to induce OIC and still be ethically justifiable. Chronic pain patients may experience other opioid-induced symptoms due to longer treatments or higher doses, however the included healthy volunteers in trial 3 doubled colonic transit times (Paper IV), increased colonic fecal volume (Paper III), reported increased GI symptoms (not part of the current thesis, but investigated in a study by Nilsson et al.).⁷⁶ In trial 3, the 3D-Transit capsule was ingested before oxycodone was administered, why the opioid-induced GI symptoms would not be present in the first part of recordings. The colonic recordings included in this thesis may however not be affected of the ingestion time of the capsule, but it influenced the transit times recorded in the stomach.¹⁰ In order to avoid this effect in trial 4, the capsule ingestion time was changed to be one day after first treatment dose. Furthermore, the oxycodone dose was increased compared to trial 3 resulting in an increased transit time. The dose of naloxegol in trial 4 was chosen as the recommended dose to treat OIC, however it may have been too low when administered in opioid-naïve healthy volunteers. Hence, in a recent healthy volunteer study by Halawi et al., 2018 it was found that the same dose (25 mg naloxegol) did not normalize transit times during treatment with codeine.¹⁰² Furthermore, Van Malderan et al. showed that chronic opioid-treated patients needed a lower dose of naloxegol to reduce GI symptoms than opioid-naïve healthy volunteers.¹⁰³ Therefore, the dose of naloxegol used in trial 4 may lead to an underestimated treatment effect.

Experimental OIBD models in healthy volunteers

In trial 3 and 4 the effect of pharmacological treatments on the GI tract was studied in healthy volunteers. The included number of subjects and duration of treatments were limited to what was ethical reasonable. Patients with OIC have often been treated with

opioids for a long period, why the chosen study design may not reflect clinical OIC. Healthy volunteers do, however, not have co-morbidities, psychiatric disorders or use concomitant medication.⁷⁶ Hence, the confounding factors are limited and it may be easier to identify underlying mechanisms involved in the pathophysiology of OIC. The findings in this thesis may have shown even higher variation if examinations were performed in a heterogeneous patient group instead of the investigated population of healthy young males.

CHAPTER 7. CONCLUSION

This PhD thesis had six aims investigated in four clinical trials. We can conclude that it was possible to develop reliable methods to measure colonic length and colonic motility using the 3D-Transit system (Aims 1 and 2). Furthermore, MRI-methods to investigate colonic fecal volume and stool dryness were also tested to be reliable within normal physiological variation (Aim 3). Five-days treatment with oxycodone lead to constipation-related symptoms in healthy volunteers including increased colonic fecal volume and stool dryness (Aim 4). During oxycodone treatment, colonic motility decreased shown by increased colonic transit times and changed motor patterns, mainly caused by decreased length and velocity of contractile movements (Aim 5). Co-administration of naloxegol during oxycodone treatment reversed colonic motility towards normality in regards of transit times and fast contractile activity (Aim 6).

All included measures were sensitive to detect GI changes after experimentally-induced OIC. Especially, the 3D-Transit system offers novel and interesting insights into GI motility that cannot be obtained with other ambulatory measurement techniques. MRI measurements of fecal volume and stool dryness are easily obtained, and they proved useful in investigating treatment effects. Moreover, the methods are faster and less observer dependent than manual investigations.

7.1. FUTURE PERSPECTIVES & CLINICAL IMPLICATIONS

The analysis framework proposed in this PhD thesis provide useful information for future improvement and development of methods to asses GI function and symptoms related to OIC or other GI diseases. The thesis was limited to investigate physiology in the colon, however the 3D-Transit may have potential for detailed investigations of the stomach and small bowel. Currently, an analysis method for assessment of contractile activity in the stomach is being developed (Sutter et al., unpublished). This method may be particularly interesting in patients with gastroparesis, where transit time can be assisted by motility measures. Furthermore, the 3D-Transit system is at this time being used to investigate different patient groups including patients with diabetes and constipation. It will be interesting to see, if detailed information of colonic motility can help in treatment of GI symptoms. MRI has recently been used in pan-intestinal studies of GI motility as shown in the study by Khalaf et al., 2018.¹⁰⁴ When designing a new experimental study that includes investigation of the GI tract, it should be investigated if additional MRI measurements could be included in the protocol. Refinement and further validation of the MRI method to assess colonic water content would add more insights into the colonic absorption and secretion of fluids and how they are affected by opioid treatment. Additionally, inclusion of an imaging-based method to assess the recto-anal inhibitory reflex would provide insight into another important aspect of the pathophysiology underlying OIC.

LITERATURE LIST

1. Gilson AM, Maurer MA, Ryan KM, Rathouz PJ, Cleary JF. Using a morphine equivalence metric to quantify opioid consumption: Examining the capacity to provide effective treatment of debilitating pain at the global, regional, and country levels. *J Pain Symptom Manage*. 2013;45(4):681-700.
2. Sundhedsstyrelsen. *Kortlægning Af Opioidforbruget i Danmark: Med Focus På Patienter Med Kroniske Non-Maligne Smerter*.; 2016.
3. Leppert W. The impact of opioid analgesics on the gastrointestinal tract function and the current management possibilities. *Wspolczesna Onkol*. 2012;16(2):125-131.
4. Lee AA, Hasler WL. Opioids and GI Motility-Friend or Foe? *Curr Treat Options Gastroenterol*. 2016;14(4):478-494.
5. De Schepper HU, Cremonini F, Park MI, Camilleri M. Opioids and the gut: Pharmacology and current clinical experience. *Neurogastroenterol Motil*. 2004;16(4):383-394.
6. Ricardo Buenaventura M, Rajive Adlaka M, Nalini Sehgal M. Opioid complications and side effects. *Pain Physician*. 2008;11:S105--S120.
7. Moylan S, Armstrong J, Diaz-Saldano D, Saker M, Yerkes EB, Lindgren BW. Are abdominal x-rays a reliable way to assess for constipation? *J Urol*. 2010;184(4 SUPPL.):1692-1697.
8. Christensen HN, Olsson U, From J, Breivik H. Opioid-induced constipation, use of laxatives, and health-related quality of life. *Scand J Pain*. 2016;11(1):104-110.
9. Kumar L, Barker C, Emmanuel A. Opioid-Induced Constipation : Pathophysiology , Clinical Consequences , and Management. 2014;2014.
10. Poulsen JL, Nilsson M, Brock C, Sandberg TH, Krogh K, Drewes AM. The impact of opioid treatment on regional gastrointestinal transit. *J Neurogastroenterol Motil*. 2016;22(2):282-291.
11. Brock C, Olesen SS, Olesen AE, Frøkjær JB, Andresen T, Drewes AM. Opioid-induced bowel dysfunction: pathophysiology and management. *Drugs*. 2012;72(14):1847-1865.
12. Waterman KC, Sutton SC. A computational model for particle size influence

- on drug absorption during controlled-release colonic delivery. 2003;86:293-304.
13. Manchikanti L, Abdi S, Atluri S, et al. American Society of Interventional Pain Physicians (ASIPP) guidelines for responsible opioid prescribing in chronic non-cancer pain: Part I--evidence assessment. *Pain Physician*. 2012;15(3 Suppl):S1-65.
 14. Caraceni A, Hanks G, Kaasa S, et al. Use of opioid analgesics in the treatment of cancer pain: Evidence-based recommendations from the EAPC. *Lancet Oncol*. 2012;13(2):58-68.
 15. Gonenne J, Camilleri M, Ferber I, et al. Effect of alvimopan and codeine on gastrointestinal transit: A randomized controlled study. *Clin Gastroenterol Hepatol*. 2005;3(8):784-791.
 16. Nelson AD, Camilleri M. Opioid-induced constipation: advances and clinical guidance. *Ther Adv Chronic Dis*. 2016;7(2):121-134.
 17. Camilleri M, Drossman DA, Becker G, Webster LR, Davies AN, Mawe GM. Emerging treatments in neurogastroenterology: a multidisciplinary working group consensus statement on opioid-induced constipation. *Neurogastroenterol Motil*. 2014;26(10):1386-1395.
 18. Galligan JJ, Akbarali HI. Molecular Physiology of Enteric Opioid Receptors. *Am J Gastroenterol Suppl*. 2014;2(1):17-21.
 19. Holzer P. Pharmacology of Opioids and their Effects on Gastrointestinal Function. *Am J Gastroenterol Suppl*. 2014;2(1):9-16.
 20. Mark EB, Poulsen JL, Haase A-M, et al. Ambulatory assessment of colonic motility using the electromagnetic capsule tracking system. *Neurogastroenterol Motil*. 2018;(February):e13451.
 21. Ahrens Jr EH, Blankenhorn DH, Hirsch J. Measurement of the human intestinal length in vivo and some causes of variation. *Gastroenterology*. 1956;31(3):274.
 22. Hounnou G, Destrieux C, Desm?? J, Bertrand P, Velut S. Anatomical study of the length of the human intestine. *Surg Radiol Anat*. 2002;24(5):290-294.
 23. Martini FH, Nath JL, Bartholomew EF. *Anatomy and Physiology*. New York: Prentice Hall; 2005.

24. Dinning PG, Sia TC, Kumar R, et al. High-resolution colonic motility recordings in vivo compared with ex vivo recordings after colectomy, in patients with slow transit constipation. *Neurogastroenterol Motil.* 2016;28(12):1824-1835.
25. Furness JB, Callaghan BP, Rivera LR, Cho H-J. The Enteric Nervous System and Gastrointestinal Innervation: Integrated Local and Central Control. In: Lyte M, Cryan JF, eds. *Microbial Endocrinology: The Microbiota-Gut-Brain Axis in Health and Disease*. New York, NY: Springer New York; 2014:39-71.
26. Greenwood-Van Meerveld B, Gardner CJ, Little PJ, Hicks GA, Dehaven-Hudkins DL. Preclinical studies of opioids and opioid antagonists on gastrointestinal function. *Neurogastroenterol Motil.* 2004;16(s2):46-53.
27. Dorn S, Lembo A, Cremonini F. Opioid-Induced Bowel Dysfunction: Epidemiology, Pathophysiology, Diagnosis, and Initial Therapeutic Approach. *Am J Gastroenterol Suppl.* 2014;2:31.
28. Galligan JJ, Akbarali HI. Molecular Physiology of Enteric Opioid Receptors. *Am J Gastroenterol Suppl.* 2014;2:17.
29. Sarna SK. *Colonic Motility: From Bench Side to Bedside*. Morgan & Claypool Life Sciences; 2010.
30. Camilleri M, Ford AC, Mawe GM, et al. Chronic constipation. *Nat Rev Dis Prim.* 2017;3:1-19.
31. Bassotti G, Gaburri M, Imbimbo BP, et al. Colonic mass movements in idiopathic chronic constipation. *Gut.* 1988;29(9):1173-1179.
32. Dinning PG, Wiklendt L, Maslen L, et al. Quantification of in vivo colonic motor patterns in healthy humans before and after a meal revealed by high-resolution fiber-optic manometry. *Neurogastroenterol Motil.* 2014;26(10):1443-1457.
33. Dinning PG, Wiklendt L, Maslen L, et al. Colonic motor abnormalities in slow transit constipation defined by high resolution, fibre-optic manometry. *Neurogastroenterol Motil.* 2015;27(3):379-388.
34. Sanders KM, Ward SM, Koh SD. Interstitial Cells: Regulators of Smooth Muscle Function. *Physiol Rev.* 2014;94(3):859-907.
35. Spencer NJ, Dinning PG, Brookes SJ, Costa M. Insights into the mechanisms

- underlying colonic motor patterns. *J Physiol*. 2016;594(15):4099-4116.
36. Hiroz P, Schlageter V, Givel JC, Kucera P. Colonic movements in healthy subjects as monitored by a magnet tracking system. *Neurogastroenterol Motil*. 2009;21(8):1-10.
 37. Narducci F, Bassotti G, Gaburri M, Morelli A. Twenty four hour manometric recording of colonic motor activity in healthy man. *Gut*. 1987;28(1):17-25.
 38. Coyne KS, Margolis MK, Yeomans K, et al. Opioid-Induced Constipation Among Patients with Chronic Noncancer Pain in the United States, Canada, Germany, and the United Kingdom: Laxative Use, Response, and Symptom Burden Over Time. *Pain Med*. 2015;16(8):1551-1565.
 39. Rauck RL, Hong KJ, North J. Opioid-Induced Constipation Survey in Patients with Chronic Noncancer Pain. *Pain Pract*. 2017;17(3):329-335.
 40. Bell TJ, Panchal SJ, Miaskowski C, Bolge SC, Milanova T, Williamson R. The Prevalence, Severity, and Impact of Opioid-Induced Bowel Dysfunction: Results of a US and European Patient Survey (PROBE 1). *Pain Med*. 2009;10(1):35-42.
 41. Holzer P, Ahmedzai SH, Niederle N, et al. Opioid-induced bowel dysfunction in cancer-related pain: causes, consequences, and a novel approach for its management. *J Opioid Manag*. 2009;5(3):145-151.
 42. Frantzides CT, Cowles V, Salaymeh B, Tekin E, Condon RE. Morphine effects on human colonic myoelectric activity in the postoperative period. *Am J Surg*. 1992;163(1):144-149.
 43. Sarna SK, Shi X-Z. Function and Regulation of Colonic Contractions in Health and Disease. In: Johnson LR, ed. *Physiology of the Gastrointestinal Tract*. 4th ed. Burlington: Academic Press; 2006:966.
 44. Thomas J. Opioid-Induced Bowel Dysfunction. *J Pain Symptom Manage*. 2008;35(1):103-113.
 45. De Luca A, Coupar IM. Insights into opioid action in the intestinal tract. *Pharmacol Ther*. 1996;69(2):103-115.
 46. Jeong ID, Camilleri M, Shin A, et al. A randomised, placebo-controlled trial comparing the effects of tapentadol and oxycodone on gastrointestinal and colonic transit in healthy humans. *Aliment Pharmacol Ther*. 2012;35(9):1088-1096.

47. Candy B, Jones L, Goodman ML, Drake R, Tookman A. Laxatives or methylnaltrexone for the management of constipation in palliative care patients. *Cochrane database Syst Rev.* 2011;(1):CD003448.
48. Xing JH, Soffer EE. Adverse effects of laxatives. *Dis Colon Rectum.* 2001;44(8):1201-1209.
49. Mozaffari S, Nikfar S, Abdollahi M. Investigational opioid antagonists for treating opioid-induced bowel dysfunction. *Expert Opin Investig Drugs.* 2018;27(3):235-242.
50. Webster L, Dhar S, Eldon M, Masuoka L, Lappalainen J, Sostek M. A phase 2, double-blind, randomized, placebo-controlled, dose-escalation study to evaluate the efficacy, safety, and tolerability of naloxegol in patients with opioid-induced constipation. *Pain.* 2013;154(9):1542-1550.
51. Tack J, Lappalainen J, Diva U, Tummala R, Sostek M. Efficacy and safety of naloxegol in patients with opioid-induced constipation and laxative-inadequate response. *United Eur Gastroenterol J.* 2015;3(5):471-480.
52. Hoad CL, Menys A, Garsed K, et al. Colon wall motility: Comparison of novel quantitative semi-automatic measurements using cine MRI. *Neurogastroenterol Motil.* 2016;28(3):327-335.
53. Dinning PG. A new understanding of the physiology and pathophysiology of colonic motility? *Neurogastroenterol Motil.* 2018;(February):e13395.
54. Dinning PG, Szczesniak MM, Cook IJ. Proximal colonic propagating pressure waves sequences and their relationship with movements of content in the proximal human colon. *Neurogastroenterol Motil.* 2008;20(5):512-520.
55. Dinning PG, Zarate N, Hunt LM, et al. Pancolonic spatiotemporal mapping reveals regional deficiencies in, and disorganization of colonic propagating pressure waves in severe constipation. *Neurogastroenterol Motil.* 2010;22(12):340-349.
56. Dinning PG, Smith TK, Scott SM. Pathophysiology of colonic causes of chronic constipation. *Neurogastroenterol Motil.* 2009;21(SUPPL. 2):20-30.
57. Dinning PG, Di Lorenzo C. Colonic dysmotility in constipation. *Best Pract Res Clin Gastroenterol.* 2011;25(1):89-101.
58. Dinning P, Scott S. Novel diagnostics and therapy of colonic motor disorders. *Curr Opin Pharmacol.* 2011;11(6):624-629.

59. Dinning PG, Zarate N, Szczesniak MM, et al. Bowel preparation affects the amplitude and spatiotemporal organization of colonic propagating sequences. *Neurogastroenterol Motil.* 2010;22(6).
60. Lin AY, Du P, Dinning PG, et al. High-resolution anatomic correlation of cyclic motor patterns in the human colon: Evidence of a rectosigmoid brake. *Am J Physiol - Gastrointest Liver Physiol.* 2017;312(5):G508-G515.
61. Scott SM. Manometric techniques for the evaluation of colonic motor activity: Current status. *Neurogastroenterol Motil.* 2003;15(5):483-513.
62. Parkman HP. Scintigraphy for Evaluation of Patients for GI Motility Disorders — The Referring Physician’s Perspective. *Ysnuc.* 2012;42(2):76-78.
63. Metcalf AM, Phillips SF, Zinsmeister AR, MacCarty RL, Beart RW, Wolff BG. Simplified assessment of segmental colonic transit. *Gastroenterology.* 1987;92(1):40-47.
64. Marciani L, Garsed KC, Hoad CL, et al. Stimulation of colonic motility by oral PEG electrolyte bowel preparation assessed by MRI: Comparison of split vs single dose. *Neurogastroenterol Motil.* 2014;26(10):1426-1436.
65. Pritchard SE, Paul J, Major G, et al. Assessment of motion of colonic contents in the human colon using MRI tagging. *Neurogastroenterol Motil.* 2017;(September 2016):e13091.
66. Murray K, Hoad CL, Mudie DM, et al. Magnetic Resonance Imaging Quantification of Fasted State Colonic Liquid Pockets in Healthy Humans. *Mol Pharm.* 2017;14(8):2629-2638.
67. Lam C, Chaddock G, Marciani L, et al. Colonic response to laxative ingestion as assessed by MRI differs in constipated irritable bowel syndrome compared to functional constipation. *Neurogastroenterol Motil.* 2016;28(6):861-870.
68. Saad RJ, Hasler WL. A technical review and clinical assessment of the wireless motility capsule. *Gastroenterol Hepatol.* 2011;7(12):795-804.
69. Wang YT, Mohammed SD, Farmer AD, et al. Regional gastrointestinal transit and pH studied in 215 healthy volunteers using the wireless motility capsule: Influence of age, gender, study country and testing protocol. *Aliment Pharmacol Ther.* 2015;42(6):761-772.
70. Haase a. M, Gregersen T, Schlageter V, et al. Pilot study trialling a new

- ambulatory method for the clinical assessment of regional gastrointestinal transit using multiple electromagnetic capsules. *Neurogastroenterol Motil.* 2014;26(12):1783-1791.
71. Mark EB, Poulsen JL, Haase AM, et al. Assessment of colorectal length using the electromagnetic capsule tracking system: a comparative validation study in healthy subjects. *Color Dis.* 2017;19(9):O350-O357.
 72. Wang YT, Mohammed SD, Farmer AD, et al. Regional gastrointestinal transit and pH studied in 215 healthy volunteers using the wireless motility capsule: Influence of age, gender, study country and testing protocol. *Aliment Pharmacol Ther.* 2015;42(6):761-772.
 73. Farmer A, Wegeberg A-ML, Brock B, et al. Regional gastrointestinal contractility measures using the wireless motility capsule: reproducibility and influence of age, gender and study country. *Aliment Pharm Ther.* 2017;in press.
 74. Hoed CL, Menys A, Garsed K, et al. Colon wall motility: comparison of novel quantitative semi-automatic measurements using cine MRI. *Neurogastroenterol Motil.* 2016;28(3):327-335.
 75. Grønlund D, Poulsen JL, Sandberg TH, et al. Established and emerging methods for assessment of small and large intestinal motility. *Neurogastroenterol Motil.* 2017;29(7):e13008.
 76. Nilsson M, Poulsen JL, Brock C, et al. Opioid-induced bowel dysfunction in healthy volunteers assessed with questionnaires and MRI. *Eur J Gastroenterol Hepatol.* 2016:514-524.
 77. Poulsen JL, Mark EB, Brock C, Frøkjær JB, Krogh K, Drewes AM. Colorectal transit and volume during treatment with prolonged-release oxycodone/naloxone versus oxycodone plus macrogol 3350. *J Neurogastroenterol Motil.* 2018;24(1):119-127.
 78. Nilsson M, Sandberg TH, Poulsen JL, et al. Quantification and variability in colonic volume with a novel magnetic resonance imaging method. *Neurogastroenterol Motil.* 2015;27(12):1755-1763.
 79. Gregersen T, Haase A-M, Schlageter V, Gronbaek H, Krogh K. Regional Gastrointestinal Transit Times in Patients With Carcinoid Diarrhea: Assessment With the Novel 3D-Transit System. *J Neurogastroenterol Motil.* 2015;21(3):423-432.

80. Haase AM, Gregersen T, Christensen LA, et al. Regional gastrointestinal transit times in severe ulcerative colitis. *Neurogastroenterol Motil.* 2016;28(2):217-224.
81. Knudsen K, Haase A-M, Fedorova TD, et al. Gastrointestinal Transit Time in Parkinson's Disease Using a Magnetic Tracking System. *J Parkinsons Dis.* 2017;7(3):471-479.
82. Worsøe J, Fynne L, Gregersen T, et al. Gastric transit and small intestinal transit time and motility assessed by a magnet tracking system. *BMC Gastroenterol.* 2011;11(1):145.
83. Hedsund C, Gregersen T, Joensson IM, Olesen H V, Krogh K. Gastrointestinal transit times and motility in patients with cystic fibrosis. *Scand J Gastroenterol.* 2012;47(8-9):920-926.
84. Fynne L, Worsøe J, Gregersen T, Schlageter V, Laurberg S, Krogh K. Gastrointestinal transit in patients with systemic sclerosis. *Scand J Gastroenterol.* 2011;46:1187-1193.
85. Fassov J, Lundby L, Worsøe J, Buntzen S, Laurberg S, Krogh K. A randomised, controlled study of small intestinal motility in patients treated with sacral nerve stimulation for irritable bowel syndrome. *BMC Gastroenterol.* 2014;14:111.
86. Haase AM, Fallet S, Otto M, Scott SM, Schlageter V, Krogh K. Gastrointestinal motility during sleep assessed by tracking of telemetric capsules combined with polysomnography - a pilot study. *Clin Exp Gastroenterol.* 2015;8:327-332.
87. Kalsi GK, Grønlund D, Martin J, Drewes AM, Scott SM, Birch MJ. Technical report: Inter- and intra-rater reliability of regional gastrointestinal transit times measured using the 3D-Transit electromagnet tracking system. *Neurogastroenterol Motil.* 2018;(March):e13396.
88. Sandberg TH, Nilsson M, Poulsen JL, et al. A novel semi-automatic segmentation method for volumetric assessment of the colon based on magnetic resonance imaging. *Abdom Imaging.* 2015;40:2232-2241.
89. Alyami J, Spiller RC, Marciani L. Magnetic resonance imaging to evaluate gastrointestinal function. 2015;44(October):1687-1692.
90. Bendezú RA, Mego M, Monclus E, et al. Colonic content: effect of diet, meals, and defecation. *Neurogastroenterol Motil.* 2017;29(2):e12930.

91. Ritchie JA, Infirmiry TR. Colonic motor activity and bowel function. 1968;(1964):502-511.
92. Ritchie JA. Colonic motor activity and bowel function Normal movement of contents. 1968;(1912):442-456.
93. Duncan JE, McNally MP, Sweeney WB, et al. CT colonography predictably overestimates colonic length and distance to polyps compared with optical colonoscopy. *Am J Roentgenol*. 2009;193(5):1291-1295.
94. Williams C, Teague R. Colonoscopy. *Gut*. 1973;14:990-1003.
95. Sadahiro S, Ohmura T, Saito T, Suzuki S. Relationship between length and surface area of each segment of the large intestine and the incidence of colorectal cancer. *Cancer*. 1991;68(1):84-87.
96. Yik YI, Cook DJ, Veysey DM, et al. How common is colonic elongation in children with slow-transit constipation or anorectal retention? *J Pediatr Surg*. 2012;47(7):1414-1420.
97. Raahave D, Christensen E, Loud FB, Knudsen LL. Correlation of bowel symptoms with colonic transit, length, and faecal load in functional faecal retention. *Dan Med Bull*. 2009;56(2):83-88.
98. Abrahamsson H, Antov S, Bosaeus I. Gastrointestinal and Colonic Segmental Transit Time Evaluated by a Single Abdominal X-ray in Healthy Subjects and Constipated Patients. *Scand J Gastroenterol*. 1988;23(sup152):72-80.
99. Farmer AD, Holt CB, Downes TJ, Ruggeri E, Del Vecchio S, De Giorgio R. Pathophysiology, diagnosis, and management of opioid-induced constipation. *Lancet Gastroenterol Hepatol*. 2018;3(3):203-212.
100. Musial F, Enck P, Kalveram K-T, Erckenbrecht JF. The effect of loperamide on anorectal function in normal healthy men. *J Clin Gastroenterol*. 1992;15(4):321-324.
101. Major G, Murray K, Singh G, et al. Demonstration of differences in colonic volumes, transit, chyme consistency, and response to psyllium between healthy and constipated subjects using magnetic resonance imaging. *Neurogastroenterol Motil*. 2018;(December 2017):1-11.
102. Halawi H, Vijayvargiya P, Busciglio I, et al. Effects of naloxegol on whole gut transit in opioid-naïve healthy subjects receiving codeine: A randomized, controlled trial. *Neurogastroenterol Motil*. 2018;30(5):1-9.

LITERATURE LIST

103. van Malderen K, Halawi H, Camilleri M. Insights on efficacious doses of PAMORAs for patients on chronic opioid therapy or opioid-naïve patients. *Neurogastroenterol Motil.* 2018;30(5):e13250.
104. Khalaf A, Hoad CL, Menys A, et al. MRI assessment of the postprandial gastrointestinal motility and peptide response in healthy humans. *Neurogastroenterol Motil.* 2018;30(1):e13182.

ISSN (online): 2246-1302
ISBN (online): 978-87-7210-377-8

AALBORG UNIVERSITY PRESS