



AALBORG UNIVERSITY
DENMARK

Aalborg Universitet

Acute Ischemic Stroke in Late Pregnancy Treated with Intravenous Thrombolysis and Endovascular Therapy

Szuchy Kristiansen, E.; Holm Vestergaard, H.; Modrau, B.; Oppel, L.M.

Published in:
Case Reports in Neurology

DOI (link to publication from Publisher):
[10.1159/000496084](https://doi.org/10.1159/000496084)

Creative Commons License
CC BY-NC 4.0

Publication date:
2019

Document Version
Publisher's PDF, also known as Version of record

[Link to publication from Aalborg University](#)

Citation for published version (APA):
Szuchy Kristiansen, E., Holm Vestergaard, H., Modrau, B., & Oppel, L. M. (2019). Acute Ischemic Stroke in Late Pregnancy Treated with Intravenous Thrombolysis and Endovascular Therapy. *Case Reports in Neurology*, 11(1), 41-46. <https://doi.org/10.1159/000496084>

General rights

Copyright and moral rights for the publications made accessible in the public portal are retained by the authors and/or other copyright owners and it is a condition of accessing publications that users recognise and abide by the legal requirements associated with these rights.

- Users may download and print one copy of any publication from the public portal for the purpose of private study or research.
- You may not further distribute the material or use it for any profit-making activity or commercial gain
- You may freely distribute the URL identifying the publication in the public portal -

Take down policy

If you believe that this document breaches copyright please contact us at vbn@aub.aau.dk providing details, and we will remove access to the work immediately and investigate your claim.

Case Report

Acute Ischemic Stroke in Late Pregnancy Treated with Intravenous Thrombolysis and Endovascular Therapy

Eva Szuchy Kristiansen^{a, b} Hannah Holm Vestergaard^a Boris Modrau^b
Lorenz Martin Oppel^b

^aFaculty of Medicine, Aalborg University, Aalborg, Denmark; ^bDepartment of Neurology, University Hospital, Aalborg, Denmark

Keywords

Acute stroke · Pregnancy · Thrombolysis · Endovascular therapy

Abstract

Pregnancy has usually been an exclusion criterion in clinical trials with thrombolysis and endovascular therapy in acute ischemic stroke. For that reason, these therapies are not recommended causing lack of evidence and vice versa. In this case report, we describe a pregnant woman in week 33 + 3 presenting with acute ischemic stroke, which was successfully treated with systemic thrombolysis and endovascular therapy, resulting in a good clinical outcome for both mother and child. The altered fibrinolytic system and the risk factors related to pregnancy constitute a challenge for clinicians when choosing the most suitable treatment modality for treating acute ischemic stroke in pregnancy. It is still uncertain whether thrombolysis in combination with endovascular therapy or endovascular therapy alone is the most appropriate treatment option. However, there is slowly growing evidence that thrombolysis and thrombectomy in pregnancy are feasible and safe with a good clinical outcome for both the mother and the child.

© 2019 The Author(s)
Published by S. Karger AG, Basel

Introduction

The benefit of systemic thrombolysis with tissue plasminogen activator as well as endovascular therapy in acute ischemic stroke is well documented [1]. Furthermore, recent studies have documented that thrombolysis followed by thrombectomy using a stent retriever in patients with acute ischemic stroke in the proximal anterior intracranial circulation is superior to thrombolysis alone [2]. Pregnancy is a procoagulant state and the risk of stroke, and deep venous thrombosis and pulmonary embolism, is increased [3, 4]. However, to date, pregnant women with acute ischemic stroke have been excluded from reperfusion trials, resulting in paucity of evidence within this area [5]. The concerns regarding the use of thrombolysis during pregnancy include the risk of placental abruption, retroplacental hemorrhage, abortion, peripartum uterine bleeding and postpartum hemorrhage, as well as possible teratogenicity of thrombolysis treatment [1, 6, 7]. The use of thrombectomy during pregnancy raises concerns regarding radiation, anesthesia related complications, and the use of contrast during the procedure [8, 9]. The lack of data from reperfusion trials in this subgroup of patients makes case reports an important source of information that could shed light on this issue. In the recent years, a growing number of case reports demonstrating the beneficial use of thrombolysis in pregnant women with acute ischemic stroke have emerged. However, only 3 reports regarding thrombolysis in combination with endovascular therapy in stroke have been published [10–12].

In the following, we are presenting a case of stroke in a pregnant patient in week 33 + 3 that was successfully treated with thrombolysis followed by endovascular therapy with a Trevo retriever.

Case Report

A 26-year-old right-handed, unigravida in week 33 + 3 with an uncomplicated pregnancy, was admitted to the local stroke department 2 h after onset of symptoms. On admission, the patient presented with a left-sided paralysis of the arm and leg, left-sided facial weakness, inattention, dysarthria, and incomplete left vertical gaze palsy. The National Institute of Health Stroke Scale (NIHSS) score was 14, indicating a major stroke. Before stroke, the patient was healthy besides headache episodes, including migraine for many years, which was treated with mild analgesics. The patient also had depression, treated with citalopram (SSRI); however, this was terminated in early pregnancy. The patient was a non-smoker and her BMI was above 35 throughout the pregnancy. The patient had a grandfather with stroke at the age of 60, but no other stroke history in the family. At admission, an acute magnetic resonance imaging (MRI) confirmed acute ischemic stroke on diffusion-weighted imaging placed in the right basal ganglia area congruous for occlusion of the lenticular striate arteries (Fig. 1a). As expected, the MRI angiography showed occlusion of the main stem in the right middle cerebral artery (M1 branch) (Fig. 2a).

Intravenous thrombolysis of 90 mg Actilyse® was initiated 3 h after onset of symptoms. The patient was transferred to the nearest comprehensive stroke center while continuing Actilyse® infusion. No clinical improvement or worsening was seen after the complete infusion was finished. The patient arrived at the comprehensive stroke center approximately 5 h after symptom onset. Digital subtraction angiography in local and twilight anesthesia confirmed unchanged occlusion of the left middle cerebral artery (angiography before thrombectomy, Fig. 2a). There was no sign of dissection or arteriosclerotic plaques of the neck arteries. A

Trevo stent retriever inserted through the right femoral artery was used, and recanalization (thrombolysis in cerebral infarction (TICI) grad 3) was achieved after the first attempt 6 h after symptom onset (angiography after cloth removal, Fig. 2b). The NIHSS was 7 immediately after thrombectomy, and 5 at 24 h follow-up, with remaining symptoms such as dysarthria, left-sided slight inattention, central facial palsy, and affected coordination on the left side. The cardiotocography of the fetus after the event was normal. A follow-up MRI at 24 h showed a small infarct in the right basal ganglia with hemorrhagic transformation in the nucleus lenticularis. The MRI angiography showed recanalization of the right M1-branch, but an upstream thrombosis of the M3-branch was detected. Secondary stroke prophylaxis with aspirin 75 mg/day was started. The patient was discharged from the hospital to rehabilitation 8 days after the stroke onset. At the time of transfer, the patient had regained ambulatory function. One week later, only a slight facial palsy, reduced fine motor skills of the left arm, and slight cognitive deficits were found. Aspirin was paused 5 days before a planned caesarian section in week 38 + 5. A healthy boy was delivered without any complications. Aspirin was restarted the following day and later, anti-depressive treatment (mirtazapine and later citalopram) was given for postpartum depression. At a follow-up 6 months after the stroke, the patient was independent in daily activities. A slight spasticity in the left foot as well as in the left hand was present, and both were treated successfully with botulinum toxin. The patient was followed in the botulinum toxin outpatient department over the years. The child is now 5 years old, healthy and reached all milestones as expected.

The initial cerebrovascular workup for stroke was added by electrocardiography, 24 h Holter monitoring, transthoracic and transesophageal echocardiography, and blood tests for thrombophilia. The patient was diagnosed with hypercholesterolemia, and therapy with statins was started. Furthermore, the tests confirmed a heterozygote factor V Leiden mutation, while the remaining tests were normal. Heterozygote factor V Leiden mutation, in combination with a change of the coagulation status during pregnancy, might increase the risk of hypercoagulation. However, the risk of thrombosis will typically be more increased in the venous than in the arterial system, and a persistent foramen oval as reason for a paradoxical embolism was not found. Thus, the cause of stroke is still uncertain.

Discussion/Conclusion

Acute ischemic stroke during pregnancy is rare; yet, when it occurs it can be catastrophic for the mother as well as for the fetus. In current guidelines, pregnancy is considered a relative contraindication for acute stroke treatment [13]. Currently, there are only a few case reports and no data from controlled randomized trials concerning thrombolysis in combination with thrombectomy for stroke during pregnancy [10–12]. However, in a recent large stroke registry, pregnant or postpartum women were reported to have similarly favorable short-term outcome after reperfusion therapy (defined as thrombolysis, catheter-based thrombolysis, or thrombectomy either alone or in combination) as compared to nonpregnant women [5].

Serious bleeding complications are rare during thrombolysis and seem to be equivalent to nonpregnant women, and child outcome appears not to be affected when using thrombolysis [14]. This is supported by animal studies that show no signs of teratogenicity as Actilyse® does not cross the placenta due to the large molecular size [3, 5]. However, in patients with increased risk of bleeding such as placenta previa, late pregnancy close to delivery, or patients with acute caesarean section, Actilyse® remains contraindicated due to increased risk of hemorrhagic complications. For this group of patients, thrombectomy is a possible treatment

option in case of large vessel occlusion [5]. To the best of our knowledge, there are only 3 published case reports, presenting the use of thrombolysis in combination with stent retrievers in pregnancy [10–12]. The 3 case reports demonstrated successful thrombectomy in all 3 cases without any serious complications of the procedure and beneficial outcome for the mother and child. Concurrently, our case showed that recanalization was only achieved by the combination of thrombolysis and thrombectomy. Nevertheless, it is still unknown whether thrombectomy alone could have been just as effective and whether the combination of systemic thrombolysis followed by thrombectomy has a synergetic effect. However, in case of contraindications for thrombolysis, thrombectomy as first line might be a considerable treatment option.

The downside of thrombectomy might be the radiation during the procedure and its possible side effect on the fetus. Several studies have demonstrated that conventional endovascular procedures do not cause serious radiation exposure that could exceed the threshold of safety for the fetus [12]. Therefore, endovascular therapy can be safely performed in pregnancy with adequate attention to pharmaceutical agents and shielding from radiation [15]. In our case, appropriate shielding of the abdomen during the procedure provided protection from radiation. Furthermore, it is important to be aware that the damage of radiation is not only related to the total dose of absorbed radiation, but also to the gestational age of the fetus [12]. Like our case, the previous 3 case reports illustrate successful outcome with thrombolysis and thrombectomy in patients in the late second or third trimester. Thus, information regarding treatment outcome in early pregnancy is still lacking.

Currently, there is only little evidence to guide clinicians to choose the right treatment for pregnant patients with acute ischemic stroke. However, our case adds the slowly growing evidence that thrombolysis and thrombectomy in pregnancy are feasible and safe with good clinical outcome for both the mother and the child even though caution must be taken for publication bias in favor of good clinical outcome. As in all cases of acute stroke treatment, an individual risk/benefit assessment should be made. Especially in therapeutic options with limited evidence, the pros and cons should always be carefully weighted.

Acknowledgement

We would like to thank the Department of Neuroradiology, Aarhus University Hospital for contributing with the angiography scans.

Statement of Ethics

The authors have no ethical conflicts to disclose.

Disclosure Statement

The authors have no conflicts of interest to declare.

Funding Sources

The authors have no funding sources to disclose.

Author Contributions

There is equal contribution from all authors.

References

- 1 Aaron S, Shyamkumar NK, Alexander S, Babu PS, Prabhakar AT, Moses V, et al. Mechanical thrombectomy for acute ischemic stroke in pregnancy using the penumbra system. *Ann Indian Acad Neurol*. 2016 Apr-Jun;19(2):261–3.
- 2 Saver JL, Goyal M, Bonafe A, Diener HC, Levy EI, Pereira VM, et al.; SWIFT PRIME Investigators. Stent-retriever thrombectomy after intravenous t-PA vs. t-PA alone in stroke. *N Engl J Med*. 2015 Jun;372(24):2285–95.
- 3 Leonhardt G, Gaul C, Nietsch HH, Buerke M, Schleussner E. Thrombolytic therapy in pregnancy. *J Thromb Thrombolysis*. 2006 Jun;21(3):271–6.
- 4 Tate J, Bushnell C. Pregnancy and stroke risk in women. *Womens Health (Lond)*. 2011 May;7(3):363–74.
- 5 Leffert LR, Clancy CR, Bateman BT, Cox M, Schulte PJ, Smith EE, et al. Treatment patterns and short-term outcomes in ischemic stroke in pregnancy or postpartum period. *Am J Obstet Gynecol* 2016;214:723.e 1–11.
- 6 De Keyser J, Gdovinová Z, Uyttenboogaart M, Vroomen PC, Luijckx GJ. Intravenous alteplase for stroke: beyond the guidelines and in particular clinical situations. *Stroke*. 2007 Sep;38(9):2612–8.
- 7 Chua WL, Wang J, Loh SF, Chan KY, Brent LR. Thrombotic stroke in association with ovarian hyperstimulation and early pregnancy rescued by thrombectomy. *Case Rep Perinat Med* 2012;1(1-2):43–5.
- 8 Webb JA, Thomsen HS, Morcos SK; Members of Contrast Media Safety Committee of European Society of Urogenital Radiology (ESUR). The use of iodinated and gadolinium contrast media during pregnancy and lactation. *Eur Radiol*. 2005 Jun;15(6):1234–40.
- 9 Bajwa SJ, Bajwa SK. Anaesthetic challenges and management during pregnancy: strategies revisited. *Anesth Essays Res*. 2013 May-Aug;7(2):160–7.
- 10 Boyko M, Iancu D, Lesiuk H, Dowlathshahi D, Shamy MC. Decision Making and the Limits of Evidence: A Case Study of Acute Stroke in Pregnancy. *Neurohospitalist*. 2016 Apr;6(2):70–5.
- 11 Watanabe T, Kawaguchi T, Itaya S, Ichijo M, Amino T, Kamata T. Acute ischemic stroke in a 37-year-old pregnant woman successfully treated with recombinant tissue plasminogen activator and endovascular mechanical thrombectomy: A case report. *J Neurol Sci*. 2017;381:945–1128.
- 12 Bhogal P, Aguilar M, AlMatter M, Karck U, Bätzner H, Henkes H. Mechanical Thrombectomy in Pregnancy: Report of 2 Cases and Review of the Literature. *Intervent Neurol*. 2017 Mar;6(1-2):49–56.
- 13 Jauch EC, Saver JL, Adams HP Jr, Bruno A, Connors JJ, Demaerschalk BM, et al.; American Heart Association Stroke Council; Council on Cardiovascular Nursing; Council on Peripheral Vascular Disease; Council on Clinical Cardiology. Guidelines for the early management of patients with acute ischemic stroke: a guideline for healthcare professionals from the American Heart Association/American Stroke Association. *Stroke*. 2013 Mar;44(3):870–947.
- 14 Steinberg A, Moreira TP. Neuroendocrinal, Neurodevelopmental, and Embryotoxic Effects of Recombinant Tissue Plasminogen Activator Treatment for Pregnant Women with Acute Ischemic Stroke. *Front Neurosci*. 2016 Feb;10:51.
- 15 Khan A, Hosseini P, Nevajda B, Khan S. Lesson of the month 2: use of thrombolysis for ischaemic stroke in pregnancy - a case report and review of literature. *Clin Med (Lond)*. 2017 Dec;17(6):581–3.

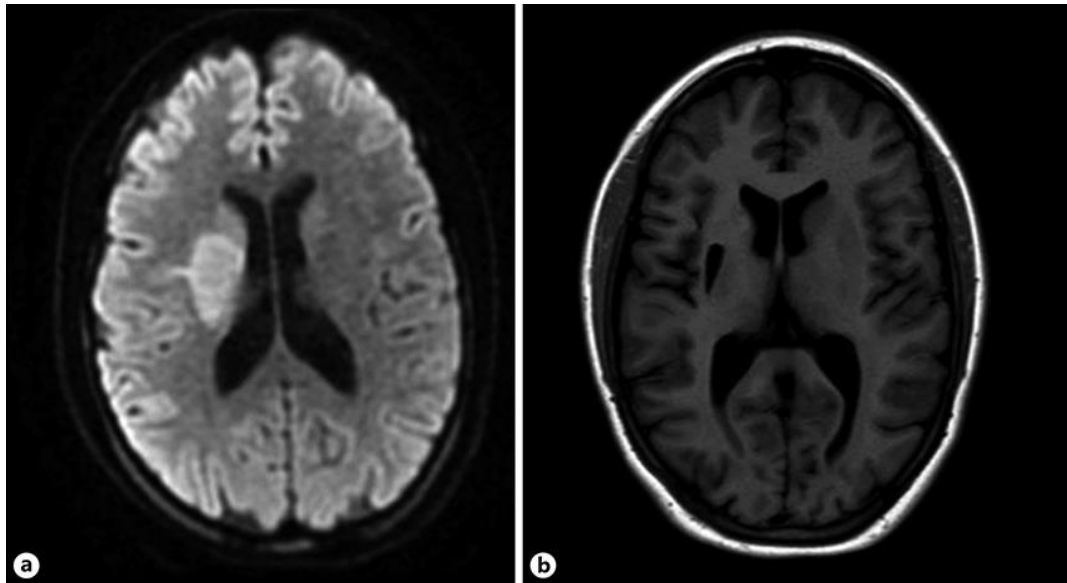


Fig. 1. **a** Initial diffusion-weighted magnetic resonance imaging showed acute infarction in the right basal ganglia. **b** Follow-up magnetic resonance imaging (T2 sequence) at 5 months showed sequelae with substantial loss in the right basal ganglia.

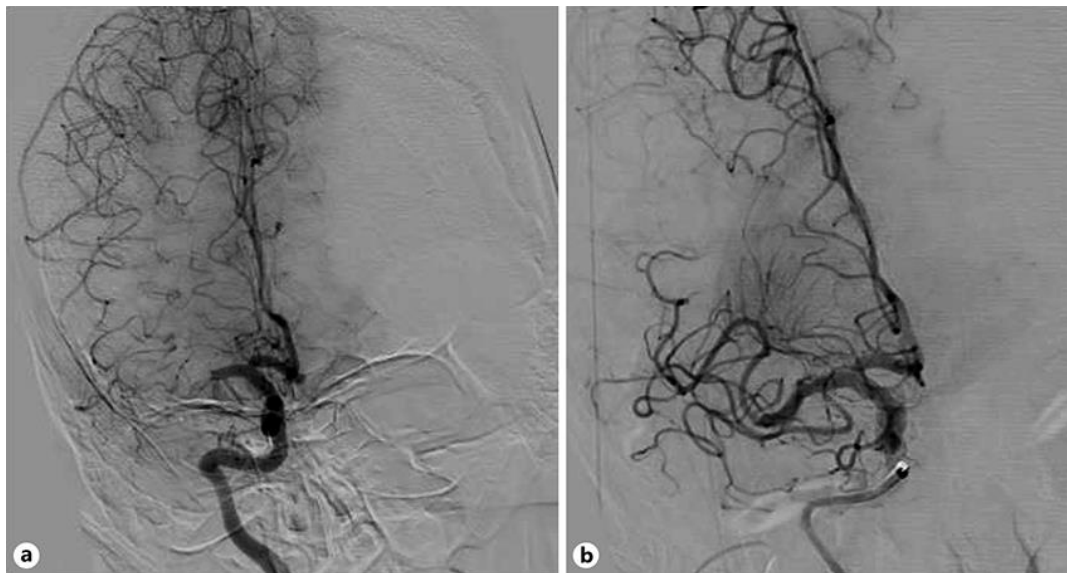


Fig. 2. **a** Digital subtraction angiography of the right internal carotid artery before thrombectomy showed occlusion of the right M1 (main) medial cerebral artery. **b** Successful thrombectomy with complete recanalization (TICI grade 3) of the right medial cerebral artery.