



AALBORG UNIVERSITY
DENMARK

Aalborg Universitet

Animal Models Used to Simulate Retinal Artery Occlusion

A Comprehensive Review

Vestergaard, Nanna; Cehofski, Lasse Jørgensen; Honoré, Bent; Aasbjerg, Kristian; Vorum, Henrik

Published in:
Translational vision science & technology

DOI (link to publication from Publisher):
[10.1167/tvst.8.4.23](https://doi.org/10.1167/tvst.8.4.23)

Creative Commons License
CC BY-NC-ND 4.0

Publication date:
2019

Document Version
Publisher's PDF, also known as Version of record

[Link to publication from Aalborg University](#)

Citation for published version (APA):
Vestergaard, N., Cehofski, L. J., Honoré, B., Aasbjerg, K., & Vorum, H. (2019). Animal Models Used to Simulate Retinal Artery Occlusion: A Comprehensive Review. *Translational vision science & technology*, 8(4), 1-14. [23]. <https://doi.org/10.1167/tvst.8.4.23>

General rights

Copyright and moral rights for the publications made accessible in the public portal are retained by the authors and/or other copyright owners and it is a condition of accessing publications that users recognise and abide by the legal requirements associated with these rights.

- ? Users may download and print one copy of any publication from the public portal for the purpose of private study or research.
- ? You may not further distribute the material or use it for any profit-making activity or commercial gain
- ? You may freely distribute the URL identifying the publication in the public portal ?

Take down policy

If you believe that this document breaches copyright please contact us at vbn@aub.aau.dk providing details, and we will remove access to the work immediately and investigate your claim.

Animal Models Used to Simulate Retinal Artery Occlusion: A Comprehensive Review

Nanna Vestergaard¹, Lasse Jørgensen Cehofski²⁻⁴, Bent Honoré^{5,6}, Kristian Aasbjerg^{7,8}, and Henrik Vorum^{1,6}

¹ Department of Ophthalmology, Aalborg University Hospital, Aalborg, Denmark

² Department of Ophthalmology, Odense University Hospital, Odense, Denmark

³ Department of Ophthalmology, Vejle Hospital - part of Lillebaelt Hospital, Vejle, Denmark

⁴ Department of Clinical Research, University of Southern Denmark, Odense, Denmark

⁵ Department of Biomedicine, Aarhus University, Aarhus, Denmark

⁶ Department of Clinical Medicine, Aalborg University Hospital, Aalborg, Denmark

⁷ Department of Ophthalmology, Aarhus University Hospital, Aarhus, Denmark

⁸ Department of Epidemiology, Aalborg University Hospital, Aalborg, Denmark

Correspondence: Nanna Vestergaard, Department of Ophthalmology, Aalborg University Hospital, Hobrovej 18-22, 9000 Aalborg, Denmark. e-mail: nanna.vestergaard@rn.dk

Received: 2 April 2019

Accepted: 10 June 2019

Published: 15 August 2019

Keywords: retinal artery occlusion; experimental models; animal models; retinal ischemia; in vivo models

Citation: Vestergaard N, Cehofski LJ, Honoré B, Aasbjerg K, Vorum H. Animal models used to simulate retinal artery occlusion: a comprehensive review. *Trans Vis Sci Tech.* 2019;8(4):23, <https://doi.org/10.1167/tvst.8.4.23>
Copyright 2019 The Authors

Purpose: To present an overview of animal models of retinal artery occlusion (RAO).

Methods: Through a systematic literature search in PubMed and Embase, papers describing methods of inducing RAO in animal models were included. The identified methodologic approaches were presented in a narrative synthesis and compared with RAO in humans.

Results: In total, 83 papers reporting on 88 experiments were included. Six different species were used with rodents and monkeys being the most common, and a minority were performed using cats, dogs, rabbits, or pigs. The anatomy of pigs and monkeys resemble that of humans most closely. The two most frequently used methods were laser-induced occlusion or ligation of the arteries. Other methods included raised intraocular pressure, arterial clamping, administration of vasoconstricting agents, the use of an occluder, embolization, and endovascular approaches to induce occlusion. In general, occlusions lasted for only 30 to 90 minutes, often followed by reperfusion.

Conclusions: Although a broad range of methods have previously been used, they all have limitations. Preferably, the methods should imitate the human disease as closely as possible and avoid damaging other structures. Therefore, monkeys followed by pigs are to be preferred and ligation or clamping may be a suitable model in larger animals as there is a potential to isolate and occlude the retinal artery only. Being less invasive, laser-induced occlusion is another suitable approach.

Translational Relevance: This review aims at assisting researchers in deciding on the most ideal experimental setting, and thereby increase the translational value to human disease.

Introduction

Retinal artery occlusion (RAO) can cause severe and irreversible vision loss. RAO is divided into branch retinal artery occlusion (BRAO) and central retinal artery occlusion (CRAO) based on the site of arterial occlusion. It is most often caused by an embolism resulting in infarction of the inner retina and may be regarded as the ocular analogue to

cerebral stroke.^{1,2} Various treatment strategies for the acute management have been explored, such as ocular massage and thrombolysis; however, no treatment has yet been shown to be effective.³ In order to develop treatment that can limit the extent and severity of ischemic injury, a deeper understanding of the pathophysiology and biochemical processes is needed. Experimental animal models of RAO have the potential to broaden our knowledge of the disease in general and lead to the development of new

treatments in particular. Also, retinal tissue is accessible in animal models allowing for advanced analyses directly at the retinal level where RAO is located.

Numerous experimental animal studies of RAO have previously been performed using a variety of different methodologic approaches with varying similarities to human conditions. However, the use of different models for inducing illness and disparate animal species, among other factors, makes it difficult to compare and extrapolate findings with humans.⁴ Indeed, criticism has been raised against several of the previously employed methods.^{5,6} Improvement and standardizations of the scientific method followed by systematic review may increase the translational value to human disease.⁴

Therefore, the aim of the present paper was to present a comprehensive overview of previously applied methodologic approaches that can be used for conducting animal models of RAO in order to assist future researchers in deciding on the most ideal experimental setting.

Methods

For this review, a systematic literature search was conducted in PubMed and Embase ([Supplementary Tables S1 and S2](#)). Prior to the search, a protocol was written. Studies were included if their experimental method induced occlusion of the retinal artery, regardless if their primary aim was to set up a model for RAO or not. The retrieved studies were examined to exclude overlapping or duplicated data. Experimental models of occlusion of vessels more proximal than the ophthalmic artery were excluded, as these more closely resembled manifestations of other diseases, such as ocular ischemic syndrome.

For each included study, the species used in the study was noted, method of inducing the occlusion, time of occlusion, and reperfusion if applicable, as well as validation of the occlusion. Results were presented using narrative synthesis, including discussion of the advantages and challenges in the various methodologic approaches.

Results

In all, 268 studies were identified after duplicates were removed, and a total of 83 studies were included ([Fig. 1](#)). Five of the included studies had used more than one method of inducing RAO and therefore each

method was included separately in the synthesis. Hence, a total of 88 reports were included.

The majority of the included studies most closely resembled CRAO. However, 23 induced one or more BRAO. Of these, 13 used lasers,⁷⁻¹⁸ five used embolization,¹⁹⁻²³ one used heat coagulation by the use of a probe,²⁴ and four used a probe or an occluder.²⁴⁻²⁷

Species

A number of different species have been used ([Table 1](#)). Rodents are the most commonly used species in the experimental animal models, the second most frequently used species being monkeys. A smaller number of experimental setups included cats, dogs, rabbits, or pigs. Especially, dogs, cats, and pigs were used in studies using methods requiring larger animals (occluder/probe, endovascular techniques, or embolization).

The resemblance to human anatomy varies widely among the species. In monkeys, the vascular architecture is very similar to humans.⁸⁹ Furthermore, monkeys have a macula as in humans, as opposed to the other species included. Overall, the structure of the retinal vascular system of the pig is similar to that of humans too.^{90,91} Diverging results exist regarding the presence of a central retinal artery (CRA) in the pig. Some authors report of a single retinal artery giving rise to several branches,⁸⁶ while others report of no formation of a CRA.⁹² The findings suggest that the retinal arteries may either arise from the ciliary artery as several branches, or as a single branch, which quickly divides. Once the nerve head is reached, only branches are visualized, typically four.⁹⁰

In contrast to humans and the other species used, both cats and dogs have a tapetum lucidum, which is a reflective layer improving vision in dim light.^{93,94} In the cat, three major arteries and two to six smaller arteries run from the optic disc to the periphery.⁹⁵ In the dog, there is no CRA. Instead, multiple vessels pierce the sclera, branching off usually three or four retinal arteries. As opposed to humans, the arteries show tortuosity.⁸⁹

The retinal vascular system of the rabbit eye is distinctly different from the human eye and the other species used in the identified studies as the rabbit retina is merangiotic (presence of blood vessels in a limited part of the retina leaving the rest of the retina avascular).^{95,96} Furthermore, the retinal circulation of the rabbit may play little role in maintaining retinal function as monitored by the electroretinogram (ERG), as suggested by Ciulla et al.³⁸

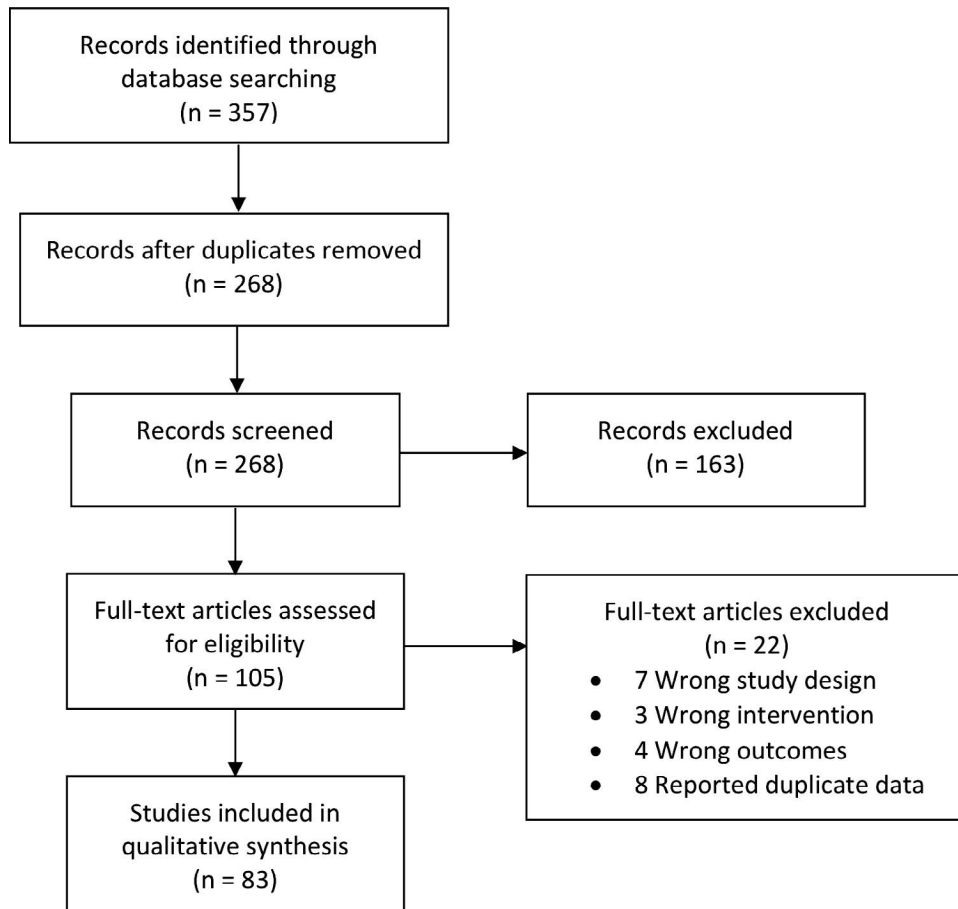


Figure 1. Flow chart of study selection procedure.

Method of Inducing RAO

Overall, RAO was induced by several methods, including laser, vasoconstriction by injection of chemical substances, increased intraocular pressure (IOP), embolization, or arterial occlusion by using a clamp or suture mainly, or by using an occluder (Table 1 and Fig. 2).

Laser

Sixteen studies used laser photocoagulation (Table 2). It was most often performed using an argon laser with wavelengths varying between 514 to 577 nm. Often, a photosensitizing agent was used to increase laser absorption and minimize the amount of laser required to produce occlusion. Hence, nine studies

Table 1. Animal Species and Techniques Used to Produce Occlusion

	Rodents, <i>n</i>	Rabbits, <i>n</i>	Cat, <i>n</i>	Dog, <i>n</i>	Pig, <i>n</i>	Monkey, <i>n</i>	Combination, <i>n</i>	Total, <i>n</i>	References
Laser, <i>n</i>	14	4	0	0	0	4	1	23	7–18,28–37
Vasoconstriction, <i>n</i>	2	3	0	0	0	1	0	6	16,38–42
Raised IOP, <i>n</i>	9	1	0	0	0	1	0	11	43–53
Clamp, <i>n</i>	0	0	0	0	0	9	0	9	5,18,54–60
Ligation, <i>n</i>	20	1	0	0	0	3	0	24	38,61–83
Occluder, probe, <i>n</i>	0	0	5	0	0	0	1	6	24–27,84
Embolization, <i>n</i>	0	1	0	2	3	0	0	6	19–23,85
Endovascular technique, <i>n</i>	0	0	0	0	3	0	0	3	86–88
Total, <i>n</i>	45	10	5	2	6	18	2	88	

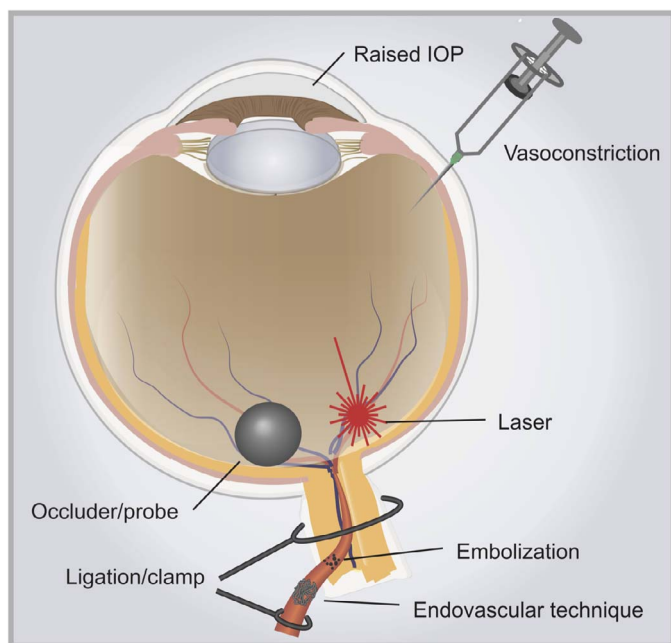


Figure 2. Methods used to induce RAO in the included studies.

used rose bengal and seven studies used no photosensitizer.

Six studies used photodynamic therapy or a photodynamic therapy-like method.^{7-9,11,13,28} In these studies, a photosensitizing agent was administered intravenously or, in one study, intraperitoneally¹³ followed by application of laser or another light source for a duration varying from 2 to 45 minutes.

One study used laser to induce targeted delivery of a platelet-activating agent, in this case adenosine diphosphate.¹²

If a CRAO was induced by laser, the laser beam was oriented at the optic disc. If one or more BRAO was aimed for, then the laser beam was targeted at one or more arterioles, typically near the optic disc.

Vasoconstriction

Apart from one study using serotonin, vasoconstriction was induced by administration of endothelin-1, which is a potent vasoconstrictor produced by vascular endothelial cells.³⁹ Generally, endothelin-1 was either injected in the posterior vitreous body over the optic disc, which causes constriction of all retinal vessels, including both veins and arteries,^{16,38,39,40} or it was injected in the subconjunctival space in the posterior part of the eyeball causing constriction of the CRA.⁴¹ It is not evident if this last method causes constriction of other vessels too.

Serotonin was used in one study to test the hypothesis that serotonin may cause vasospasm in

atherosclerotic monkeys. In total, nine monkey eyes were used, and in four of these an occlusion of the CRA was evident, an additional two showed slight filling delay.⁴²

Raised IOP

Most frequently, occlusion or ischemia was produced by cannulating the anterior chamber with a tube connected to an elevated reservoir containing saline. The IOP is then elevated to typically 120 mm Hg (range, 90–160 mm Hg). In one study, the IOP was increased by inserting and inflating an arterial embolectomy catheter balloon retrobulbarly to simulate orbital hemorrhage.⁴³ This resulted in occlusion of the CRA in two of 16 monkeys.

Clamp

This method consisted of performing a lateral orbitotomy followed by clamping of the CRA at its site of entry into the optic nerve dural sheath. It was performed on monkeys in all nine studies using this method.

Ligation

For this procedure, one study used a clip, the rest used a ligature. For the large majority, the procedure of ligating the CRA in rodents included ligation of the optic nerve and other vessels (posterior ciliary artery). However, two studies using rodents reported applying ligature solely on the CRA,^{61,62} only one of them with a detailed description on how it was done.⁶² The optic nerve was exposed by blunt dissection after a lateral conjunctival dissection and removal of the lateral rectus muscle. The CRA was exposed by longitudinally opening the dural sheath surrounding the optic nerve using fine scissors. The suture on the CRA was positioned after the trifurcation of the ophthalmic artery into the CRA and two posterior ciliary arteries.⁶²

All three studies on monkeys placed a ligature on the CRA only.

Occluder/Probe

In studies using an occluder or a probe, the probe or occluder was either produced from a steel needle or from a glass probe tipped with a glass ball. For heat coagulation, the probe was made by sealing tungsten wire into a glass capillary tube with epoxy.

Two studies used a probe and in an identical fashion. A puncture was made through the superior lateral portion of the pars plana through which the blocker probe was inserted. BRAO was then produced by pressing the probe on a branch artery. By

Table 2. Parameters of Laser Photocoagulation for Each Study

Type of Occlusion	Photo-sensitizer	Laser	Wavelength, nm	Power, mW	Spot Size, μm	Duration, s	Number of Applications, <i>n</i>	Reference
BRAO	-	NA	NA	NA	NA	NA	NA	18
CRAO (and CRVO)	-	Argon	NA	900	500	0.2–1	20	33
CRAO (and CRVO)	-	Argon	NA	900	500	0.2–1	20	34
BRAO	-	Blue–green argon laser	NA	100–200	50	0.1–0.2	Median 44	10
BRAO	-	Argon dye laser	577	80	50	0.1	10–20	13
CRAO	Rose bengal, 20 mg/kg	Argon green laser	514	100	50	0.3	NA	32
BRAO	-	Argon laser	NA	150–250	100	0.5	3–10	14
CRAO	Rose bengal, 20 mg/kg	Argon green laser	532	100	75	0.4	NA	30
CRAO	Rose bengal, 0.1 mL	Diode laser	532	490	300	0.300	NA	35
RAO (all arteries)	Rose bengal, 50mg/kg	NA	532	650	75	0.5	NA	37
BRAO	Rose bengal, 100 μL 1%	Diode laser	532	NA	75	NA	NA	15
CRAO	Rose bengal, 20 mg/kg	NA	514	100 or 150	200	NA	NA	31
CRAO	Rose bengal, 0.05 mL of 2.5 mM	YAG laser	514	100 or 150	200	0.1	20	29
CRAO	Rose bengal, 20 mg/kg	NA	532	150	200	NA	NA	36
BRAO	-	Red laser light	NA	300	NA	0.3	NA	16
BRAO	Rose bengal, 40 mg/kg	Slit-lamp Krypton laser	NA	50	50	3.0	2–3	17

CRVO, central retinal vein occlusion; NA, not available/not applicable.

pressing the probe on the optic nerve, it occluded the entire retinal circulation.^{25,84}

Three studies used an occluder and followed the same procedure. That is, to produce a BRAO the ball was pressed onto an artery emerging from the optic disc.^{24,26,27}

In one study, including two cats, the probe was used to perform heat coagulation.²⁴ The success of occlusion was evaluated by inspecting the occluded vessel by direct ophthalmoscopy.

Embolization

Studies that applied embolization-based methods were carried out by injecting various substances in

either the carotid artery^{22,23,85} or the maxillary artery.^{19–21}

In three related studies, BRAO was produced in 6 of 27, 12 of 26, and 8 of 33 cases by injecting platelet aggregates, fibrin clots, or leucocyte aggregates, respectively.^{19–21} These experiments also produced microinfarctions and hemorrhages.

Ciulla et al.²² used human atherosclerotic material, the injection of which produced BRAO in five rabbits and CRAO in four rabbits out of a total 12 animals.

In one study, the injection of air produced BRAO in all animals if they were kept hypotensive.²³ However, the occlusions lasted less than 10 minutes.

Long-acting corticosteroids were injected in one

study.⁸⁵ Combined with epinephrine, this consistently produced RAO and choriocapillaris occlusion.

Endovascular Technique

Three studies using endovascular techniques were identified. All three studies were conducted by Morén et al.^{86,87,88} and used pigs as experimental animals. The arteries were catheterized using a transfemoral, endovascular approach.

In one study, transient and permanent vascular occlusions were performed using an angioplasty balloon catheter in the ophthalmic artery or a liquid embolic agent that was administered via an injection-catheter.⁸⁶ The liquid embolic agent could produce occlusion of either the ophthalmic artery or the main ciliary artery from which the retinal arteries branches. Occlusion of the main ciliary artery produced complete ischemia, in contrast to the ophthalmic artery, which only produced incomplete ischemia.

In the other two studies, vascular occlusion was produced by using coils in the ophthalmic artery.^{87,88}

Evaluation of Successful Occlusion

In total, 41 of 88 included studies validated their occlusion by the use of fundus examination, while 29 studies used ERG as a measure of the function of the retina. Thirty-three studies used angiography (either fluorescein angiography or indocyanine green angiography), and 33 studies used histopathology to evaluate differences in the architecture of the retina. Twelve studies did not use any of these methods.^{16,17,27,29,44–46,61,63–65} A few studies used other methods to validate or evaluate the occlusion, such as visual-evoked potential or observing whitening of the iris and the loss of the red reflex. Optical coherence tomography was not performed in any of the studies.

Duration of the Occlusion

When using a setup with ligation, clamp, or increased IOP, the duration of the occlusion was controllable. The applied durations are listed in Table 3. Typically, the occlusion lasted 30 to 90 minutes followed by a varied period of reperfusion.

Endovascular approach was permanent, except when using balloon catheter, in which case the artery was occluded for 1 hour.⁸⁶

When inducing an occlusion by laser, the duration of the occlusion has a methodologic limit as spontaneous reperfusion occurs at a point, either due to recanalization or development of collateral circulation. Ten of 23 studies using laser reported the duration of the occlusions (see Table 4). Large

differences existed between studies with the duration varying from 3 hours to 2 weeks before reperfusion. In many cases, there were no data on the exact time of reperfusion, but intervals, minimums, or maximums were given for the duration of the occlusion. One study induced reperfusion by infusion of recombinant tissue plasminogen activator.¹⁰

Studies using an occluder or probe maintained the occlusion for periods ranging from 10 minutes to 4 hours.^{24–27}

Constriction caused by endothelin-1 infusion was in one study reported to last for approximately 5 minutes after which the effect declines,¹⁶ other studies found it to last for at least 50 minutes.^{39,40} Injection in the subconjunctival space caused constriction for 30 minutes.⁴¹

One study using embolization by injecting leukocyte aggregates and subsequently exposing the animals to hypoxia reported the occlusions to last up to 8 days.²⁰ Studies using other agents reported occlusions lasting up to 166 seconds or 20 minutes.^{19,23}

Discussion

Experimental animal models offer a unique opportunity to investigate different aspects of RAO. However, caution is needed when findings are extrapolated to the disease in humans. In order to increase the usefulness and applicability of RAO experiments, it is of utmost importance to imitate the human disease as closely as possible. Ideally, the anatomy of the animal should resemble that of the human eye, the intervention should mimic the occlusion of the retinal artery meaning the occlusion of the retinal artery only, and avoid damage on other tissues or structures.

Imitating the disease requires thorough knowledge on the natural history of RAO. In this aspect, the duration and extent of the occlusion is of interest. In a fluorescein angiography study in which patients were seen 4.4 days in average after the onset of symptoms, only one in 62 patients with CRAO showed complete absence of dye in the retinal arteries.⁹⁸ However, the arteriovenous transit time was found to be prolonged in most cases. Hence, while there seems to be consensus that in the clinical setting some residual circulation remains, the mechanism is still debated. It has been suggested to be due to an incomplete obstruction by the embolus in the vessel.^{30,99,100} A study by Hayreh and Jonas⁵⁴ on clamping of the CRA in monkeys reported of fluorescein angiographies similar to that in humans showing residual circulation

Table 3. Duration of Occlusions and Reperfusion for Studies Using Ligation, Clamping, or High IOP

Ligation			Clamp		
Occlusion, Duration	Reperfusion, Duration	Reference	Occlusion, Duration	Reperfusion, Duration	Reference
NA	None	79	15–20, 45, 90 min, 2.25, 4.5 hr	Few hr–3 min	18
30, 60, 120 min, 4, 24 hr	None	80	15–280 min	Up to 22 wk	55
30 min	180 min	83	NA	NA	60
30–90 min	30 min–24 hr	82	At least 116 min	NA	58
90 min	4 or 24 hr	76	At least 97 min	Mean 64.5 mo	59
30 min	180 min	66	97–300 min	NA	54
30 min	120 min	67	97–240 min	2–16 wk	5
60 min	Up to 3 d	72	3 hr	6h	56
30 min	NA	68	97–240 min	112 ± 111 d	57
30 min	NA	69			
1, 5, 10, 20, 30, 60, 120 min	NA	81			
90 min	1, 3, 5 min, 24 hr	77			
30 min	240 min	70			
30 min	240 min	71			
60 min	6, 24, 72 hr	64			
60 min	7 d	73			
NA	NA	38			
90 min	120 min	61			
NA	NA	65			
60 min	5 d	74			
90 min	24 hr	78			
30 or 90 min	3 or 12 hr	62			
60 min	10 d	75			
30 min	14 d	63			

Table 3. Extended

High IOP		
Occlusion, Duration	Reperfusion, Duration	Reference
180 or 240 min	2, 4, or 6 wk	43
45 min	3–48 hr	88
Up to 60 min	7 d	87
45 min	7 d	63
45 m	6 hr–7 d	29
5 or 10 min	24 hr	85
50 min	0, 60 min, 6 or 24 hr	44
60 min	1, 3, 5, 7, 14 d	61
90 min	1 d	62
60 min	NA	45
60 min	0, 60 min, 6, 24 hr, 7 d	84

after CRAO. It was argued that it was due to anastomoses with the CRA distal to the occlusion allowing filling, that being cilioretinal capillary anastomoses and pial and intraneural anastomoses.⁵⁴ This mechanism is only possible if the site of occlusion is proximal to the site of these anastomoses (i.e., the dural sheath). Experimental methods using increased IOP, ligation of multiple vessels, and vasoconstriction causes complete obstruction of the vessel(s) leaving no residual circulation, in contrast to the clinical picture in man.

Due to time delay, the clinical findings at the very onset of the occlusion is largely unknown. Although it is uncertain when it begins, reperfusion ultimately occurs in the majority of clinical cases. Hence, one study found reperfusion to appear in all cases of

Table 4. Reported Duration of Artery Occlusion Induced by Laser Before Spontaneous Reperfusion^a

Species	Method	Site of Occlusion	Reported Duration of Artery Occlusion	Reference
Rodents	Light + rose bengal	BRAO	>60 min	8
Rodents	Laser + rose bengal	CRAO	~6 hr	31
Rodents	Laser + rose bengal	CRAO	3hr to >24 hr	30
Rabbits	Laser + rose bengal	RAO (all arteries)	8 hr–1 d	37
Rodents	Laser + rose bengal	CRAO	At least 24–48 hr	32
Rabbits	Light + rose bengal	BRAO (and CRVO)	<3 d	7
Rodents	White light + rose bengal	BRAO	Up to 3 d	9
Rabbits	Laser + phthalocyanine	Vein and artery branch + choroidal vessels	2–4 d	11
Rabbits	Laser + chloro-aluminum sulfonated phthalocyanine	Medullary ray (artery, vein, and choroidal vessels)	72 hr –1 wk	28
Rabbits and rodents	Laser targeted delivery + encapsulated photosensitizing agent	BRAO	At least 2 wk	12

^a For studies reporting information on the duration only.

RAO, although in only 16 of the 29 patients with visible emboli perfusion recovered within the first month.⁹⁷ A study on CRAO found only 15% of eyes to have transient CRAO (lasting several minutes to many hours), while 71% had permanent CRAO, and 14% had CRAO with cilioretinal artery sparing.¹⁰¹ In the vast majority of the experimental studies, the occlusion lasted only minutes to hours followed by either spontaneous or induced/intended reperfusion. Only the endovascular method produced permanent occlusion. Therefore, it could be argued there are dissimilarities between the majority of the experimental setups and the longer lasting CRAO in humans.

It has previously been argued in a study using laser-induced thrombus that animal models that depend on well-controlled reperfusion may produce pathogenic information that is less relevant to the clinical situation.³⁰ It is argued that there is improved clinical relevance in a CRAO model with an intraluminal thrombus that can resolve naturally and spontaneously and with long-term ischemia. On the other hand, such a setup is less standardized and reproducible.

Reperfusion following ischemia is thought to cause damage to the tissue.⁶ If reperfusion takes place after irreversible damage on the retina has already happened due to the ischemia, it may be less relevant to allow reperfusion to happen in an experimental model. This is especially true for studies investigating biochemical responses with the objective to search for potential mechanism of treatment.

A disadvantage of several of the models is that they affect vessels other than the retinal artery. Endothelin-1 causes constriction of all retinal vessels, including veins. One study investigated the choroidal blood flow following the administration of endothelin-1 in rabbits.⁴⁰ They found the choroidal blood flow to increase, maybe due to regulatory mechanisms. As for the method of increased IOP, even a moderate increase in IOP causes a reduction in blood flow in the choroid.^{40,102,103} In the majority of studies using ligation, the ciliary arteries were ligated as well. Injection of material to cause embolization was done in either the carotid or maxillary artery, which may very well have caused ischemia in tissues other than the retina. When using an occluder or probe only the inner retina is made ischemic. The same applies for clamp in monkeys, laser, and, to some extent, endovascular approach.

Some methods could produce features unrelated to RAO, too. Elevation of IOP may result in both vascular occlusion-induced ischemia and mechanical injury to the retina. Öz et al.⁴⁷ reported that their model of increased IOP, "...has no similarity or analogy to isolated vascular occlusion such as clinical central retinal artery occlusion or ophthalmic artery occlusion." Ligation often included ligation of the optic nerve. This induces mechanical and ischemic damage to the optic nerve and may also induce occlusion of the ciliary arteries resulting in choroidal ischemia. This may confound the cell degeneration attributed to ischemic damage from occlusion of the

CRA. Furthermore, ligation and clamping are invasive, requiring dissection of the orbit area. Using laser may cause damage due to the use of photosensitizer and/or the laser itself.⁶ Furthermore, it seems unavoidable to damage the optic nerve and possibly the central retinal vein if CRAO is produced by applying laser to the optic nerve.

Of all species used in these studies, the anatomy of the nonhuman primates resembles that of the human eye most closely, followed by that of pigs. On the contrary, the rabbit appears to be a poor choice in experimental models of human retinal artery occlusions.^{96,38} Besides from the anatomy and the resemblance with human eyes, other factors are to be considered in regard to the different species. The size of the animal and the eye is of importance. Smaller animals may be easier to handle and require smaller housing facilities. On the other hand, larger animals with eyes with the size of human eyes, such as the pig, are an advantage or necessity in surgical methods, such as endovascular approach or ligation of only the CRA. Other factors include availability of the species and economy.

If other researchers are to replicate previous animal studies and benefit from their experience, the method should be reproducible. Especially the embolization method causes varied results and only some of the experiments resulted in BRAO. In addition, there is limited experience with some methods as they were only reported in few studies (studies on occluder/probe, endovascular technique, embolization).

To ensure critical evaluation and transparency, studies should validate their method, ideally by fundus examination, angiography, and ERG. These results should then be reported. Multiple of the included studies did not use any of these common methods, and many of those that did, did not document their findings. This makes it difficult to compare studies as the evaluation of successful occlusion is so diverse.

Conclusion and Recommendations for Future Research

Although a broad range of approaches can be used to model RAO in animals, future research on RAO should use a suitable animal model, which is anatomically and physiologically similar to humans. Therefore, monkeys followed by pigs are to be preferred and conversely, the rabbit appears to be a

poor choice. In addition, an animal model of RAO must have an occlusion pattern that resembles occlusive mechanisms in the human eye. A number of animal models of RAO induce general ocular ischemia resembling ocular ischemic syndrome. Models that induce global ocular ischemia may not be well suited for studying RAO. We recommend methods that result in RAO without damages to adjacent ocular structures. Also, the duration and extent of the ischemic period should mimic that in RAO in humans. Although none of the described methods meet all of the criteria of a perfect model some methods seem to be superior compared with others. Though it is invasive, ligation or clamp may be a suitable model in larger animals as there is a potential to isolate and occlude the retinal artery only. Laser-induced occlusion is another suitable approach being noninvasive and involving the retinal artery only. However, our review demonstrates that reperfusion of the occlusion is likely to occur. IOP, vasoconstriction, and embolization may be less suitable models as the resulting ischemia is not specific or stable enough. Regardless of the model, documentation and validation by fundus photography and angiography are indispensable for a successful study.

As no existing model is ideal, the methods may supplement each other and model various specific aspects of the disease, and thereby each contribute to the understanding of the disease. Hence, a surgical or laser-induced occlusion allows the basic reaction of the tissue to the occlusion to be studied, although the formation of a thrombosis or embolus in humans may not be mimicked completely. However, future studies are needed to develop a model with an actual thromboembolism useful in the development of treatments targeting the thrombus or emboli itself, such as thrombolytics and surgical removal of the embolus.

Acknowledgments

Disclosure: **N. Vestergaard**, None; **L.J. Cehofski**, None; **B. Honoré**, None; **K. Aasbjerg**, None; **H. Vorum**, None

References

1. Tobalem S, Schutz JS, Chronopoulos A. Central retinal artery occlusion - rethinking retinal survival time. *BMC Ophthalmol.* 2018;18:101.

2. Hayreh SS, Podhajsky PA, Zimmerman MB. Retinal artery occlusion: associated systemic and ophthalmic abnormalities. *Ophthalmology*. 2009;116:1928–1936.
3. Dattilo M, Biousse V, Newman NJ. Update on the management of central retinal artery occlusion. *Neurol Clin*. 2017;35:83–100.
4. Bracken MB. Why animal studies are often poor predictors of human reactions to exposure. *J R Soc Med*. 2009;102:120–122.
5. Hayreh SS, Zimmerman MB, Kimura A, et al. Central retinal artery occlusion. Retinal survival time. *Exp Eye Res*. 2004;78:723–736.
6. Osborne NN, Casson RJ, Wood JPM, Chidlow G, Graham M, Melena J. Retinal ischemia: mechanisms of damage and potential therapeutic strategies. *Prog Retin Eye Res*. 2004;23:91–147.
7. Nanda SK, Hatchell DL, Tiedeman JS, Dutton JJ, Hatchell MC, McAdoo T. A new method for vascular occlusion. Photochemical initiation of thrombosis. *Arch Ophthalmol*. 1987;105:1121–1124.
8. Srienc AI, Biesecker KR, Shimoda AM, Kur J, Newman EA. Ischemia-induced spreading depolarization in the retina. *J Cereb Blood Flow Metab*. 2016;36:1579–1591.
9. Wilson CA, Hatchell DL. Photodynamic retinal vascular thrombosis. Rate and duration of vascular occlusion. *Invest Ophthalmol Vis Sci*. 1991;32:2357–2365.
10. Vine AK, Maguire PT, Martonyi C, Kincaid MC. Recombinant tissue plasminogen activator to lyse experimentally induced retinal arterial thrombi. *Am J Ophthalmol*. 1988;105:266–270.
11. Iliaki OE, Naoumidi II, Tsilimbaris MK, Pallikaris IG. Photothrombosis of retinal and choroidal vessels in rabbit eyes using chloroaluminum sulfonated phthalocyanine and a diode laser. *Lasers Surg Med*. 1996;19:311–323.
12. Ogura Y, Guran T, Takahashi K, Zeimer R. Occlusion of retinal vessels using targeted delivery of a platelet aggregating agent. *Br J Ophthalmol*. 1993;77:233–237.
13. Vorwerk CK, Hyman BT, Miller JW, et al. The role of neuronal and endothelial nitric oxide synthase in retinal excitotoxicity. *Invest Ophthalmol Vis Sci*. 1997;38:2038–2044.
14. Isono H, Kishi S, Kimura Y, et al. Observation of choroidal circulation using index of erythrocytic velocity. *Arch Ophthalmol*. 2003;121:225–231.
15. Yu D-YY, Cringle SJ, Yu PK, et al. Intraretinal oxygen distribution and consumption during retinal artery occlusion and graded hyperoxic ventilation in the rat. *Invest Ophthalmol Vis Sci*. 2007;48:2290–2296.
16. Hetu S, Pouliot MM, Cordahi G, et al. Assessment of retinal and choroidal blood flow changes using laser Doppler flowmetry in rats. *Curr Eye Res*. 2013;38:158–167.
17. Fukuda S, Okuda K, Kishino G, et al. In vivo retinal and choroidal hypoxia imaging using a novel activatable hypoxia-selective near-infrared fluorescent probe. *Graefes Arch Clin Exp Ophthalmol*. 2016;254:2373–2385.
18. van Heuven WA, Hayreh MS, Hayreh SS. Experimental central retinal vascular occlusion. Blood-retinal barrier alterations and retinal lesions. *Trans Ophthalmol Soc U K*. 1977;97:588–618.
19. Schroer H, Scheurer G, Behrens-Baumann W. Vascular occlusion of the retina—an experimental model. II. Platelet aggregates. *Graefes Arch Clin Exp Ophthalmol*. 1992;230:281–285.
20. Scheurer G, Praetorius G, Damerau B, Behrens-Baumann W. Vascular occlusion of the retina: an experimental model. I. Leukocyte aggregates. *Graefes Arch Clin Exp Ophthalmol*. 1992;230:275–280.
21. Behrens-Baumann W, Scheurer G, Schroer H. Pathogenesis of Purtscher’s retinopathy. An experimental study. *Graefes Arch Clin Exp Ophthalmol*. 1992;230:286–291.
22. Ciulla TA, Moulton R, Oberoi A, Miller JW. Retinal artery occlusion in rabbit eyes using human atheroma. *Curr Eye Res*. 1995;14:573–578.
23. Soga K, Fujita H, Andoh T, et al. Retinal artery air embolism in dogs: Fluorescein angiographic evaluation of effects of hypotension and hemodilution. *Anesth Analg*. 1999;88:1004–1010.
24. Braun RD, Linsenmeier RA. Retinal oxygen tension and the electroretinogram during arterial occlusion in the cat. *Invest Ophthalmol Vis Sci*. 1995;36:523–541.
25. Landers MB. Retinal oxygenation via the choroidal circulation. *Trans Am Ophthalmol Soc*. 1978;76:528–556.
26. Birol GG, Budzynski E, Wangsa-Wirawan ND, et al. Hyperoxia promotes electroretinogram recovery after retinal artery occlusion in cats. *Invest Ophthalmol Vis Sci*. 2004;45:3690–3696.
27. Birol G, Budzynski E, Wangsa-Wirawan ND, Linsenmeier RA. Retinal arterial occlusion leads to acidosis in the cat. *Exp Eye Res*. 2005;80:527–533.

28. Kliman GH, Puliafito CA, Grossman GA, Gregory WA. Retinal and choroidal vessel closure using phthalocyanine photodynamic therapy. *Lasers Surg Med*. 1994;15:11–18.
29. Kramer M, Dadon S, Hasanreisoglu M, et al. Proinflammatory cytokines in a mouse model of central retinal artery occlusion. *Mol Vis*. 2009;15:885–894.
30. Zhang Y, Cho C-H, Atchaneeyasakul L, et al. Activation of the mitochondrial apoptotic pathway in a rat model of central retinal artery occlusion. *Invest Ophthalmol Vis Sci*. 2005;46:2133–2139.
31. Goldenberg-Cohen N, Dadon S, Avraham B-CR, et al. Molecular and histological changes following central retinal artery occlusion in a mouse model. *Exp Eye Res*. 2008;87:327–333.
32. Daugeliene L, Niwa M, Hara A, et al. Transient ischemic injury in the rat retina caused by thrombotic occlusion-thrombolytic reperfusion. *Invest Ophthalmol Vis Sci*. 2000;41:2743–2747.
33. Textorius O, Nilsson SE, Skoog KO, et al. Studies on acute and late stages of experimental central retinal artery occlusion in the Cynomolgus monkey. I. Intensity-amplitude relations of the D.C. recorded ERG with special reference to the c-wave. *Acta Ophthalmol*. 1978;56:648–664.
34. Textorius O, Skoog KO, Nilsson SE. Studies on acute and late stages of experimental central retinal artery occlusion in the Cynomolgus monkey. II. Influence on the cyclic changes in the amplitude of the c-wave of the ERG and in the standing potential of the eye. *Acta Ophthalmol*. 1978;56:665–676.
35. Yu D-YY, Townsend R, Cringle SJ, et al. Improved interpretation of flow maps obtained by scanning laser Doppler flowmetry using a rat model of retinal artery occlusion. *Invest Ophthalmol Vis Sci*. 2005;46:166–174.
36. Gaydar V, Ezrachi D, Dratviman-Storobinsky O, et al. Reduction of apoptosis in ischemic retinas of two mouse models using hyperbaric oxygen treatment. *Invest Ophthalmol Vis Sci*. 2011;52:7514–7522.
37. Guo W, Cringle SJ, Su E-N, et al. Structure and function of myelinated nerve fibers in the rabbit eye following ischemia/reperfusion injury. *Curr Neurovasc Res*. 2006;3:55–65.
38. Ciulla TA, Pawlyk BS, Harris A, et al. Endothelin-1-mediated retinal artery vasospasm and the rabbit electroretinogram. *J Ocul Pharmacol Ther*. 2000;16:393–398.
39. Takei K, Sato T, Nonoyama T, et al. A new model of transient complete obstruction of retinal vessels induced by endothelin-1 injection into the posterior vitreous body in rabbits. *Graefes Arch Clin Exp Ophthalmol*. 1993;231:476–481.
40. Sato T, Takei K, Nonoyama T, Miyauchi T, Goto K, Hommura S. Increase in choroidal blood flow in rabbits with endothelin-1 induced transient complete obstruction of retinal vessels. *Graefes Arch Clin Exp Ophthalmol*. 1995;233:425–429.
41. Masuzawa K, Jesmin S, Maeda S, et al. A model of retinal ischemia-reperfusion injury in rats by subconjunctival injection of endothelin-1. *Exp Biol Med (Maywood)*. 2006;231:1085–1089.
42. Hayreh SS, Piegors DJ, Heistad DD, et al. Serotonin-induced constriction of ocular arteries in atherosclerotic monkeys. Implications for ischemic disorders of the retina and optic nerve head. *Arch Ophthalmol*. 1997;115:220–228.
43. Hargaden M, Goldberg SH, Cunningham D, et al. Optic neuropathy following simulation of orbital hemorrhage in the nonhuman primate. *Ophthalm Plast Reconstr Surg*. 1996;12:264–272.
44. Lee J-H, Shin JM, Shin Y-J, Chun M-H, Oh S-J. Immunohistochemical changes of calbindin, calretinin and SMI32 in ischemic retinas induced by increase of intraocular pressure and by middle cerebral artery occlusion. *Anat Cell Biol*. 2011;44:25–34.
45. Michalski D, Härtig W, Krügel K, et al. Region-specific expression of vesicular glutamate and GABA transporters under various ischaemic conditions in mouse forebrain and retina. *Neuroscience*. 2013;231:328–344.
46. Russo R, Varano GP, Adornetto A, et al. Rapamycin and fasting sustain autophagy response activated by ischemia/reperfusion injury and promote retinal ganglion cell survival. *Cell Death Dis*. 2018;9:981.
47. Oz O, Gürelik G, Akyürek N, Cinel L, Hondur A. A short duration transient ischemia induces apoptosis in retinal layers: an experimental study in rabbits. *Eur J Ophthalmol*. 2005;15:233–238.
48. Junk AK, Mammis A, Savitz SI, et al. Erythropoietin administration protects retinal neurons from acute ischemia-reperfusion injury. *Proc Natl Acad Sci U S A*. 2002;99:10659–10664.
49. Yoneda S, Tanihara H, Kido N, et al. Interleukin-1 β mediates ischemic injury in the rat retina. *Exp Eye Res*. 2001;73:661–667.
50. Yoneda S, Tanaka E, Goto W, et al. Topiramate reduces excitotoxic and ischemic injury in the rat retina. *Brain Res*. 2003;967:257–266.

51. Nucci C, Tartaglione R, Rombola L, Morrone LA, Fazzi E, Bagnetta G. Neurochemical evidence to implicate elevated glutamate in the mechanisms of high intraocular pressure (IOP)-induced retinal ganglion cell death in rat. *Neurotoxicology*. 2005;26:935–941.
52. Russo R, Cavaliere F, Berliocchi L, et al. Modulation of pro-survival and death-associated pathways under retinal ischemia/reperfusion: effects of NMDA receptor blockade. *J Neurochem*. 2008;107:1347–1357.
53. Igarashi TT, Miyake K, Kobayashi M, et al. Tyrosine triple mutated AAV2-BDNF gene therapy in a rat model of transient IOP elevation. *Mol Vis*. 2016;22:816–826.
54. Hayreh SS, Jonas JB. Optic disk and retinal nerve fiber layer damage after transient central retinal artery occlusion: an experimental study in rhesus monkeys. *Am J Ophthalmol*. 2000;129:786–795.
55. Hayreh SS, Weingeist TA. Experimental occlusion of the central artery of the retina. I. Ophthalmoscopic and fluorescein fundus angiographic studies. *Br J Ophthalmol*. 1980;64:896–912.
56. Kwon YH, Rickman DW, Baruah S, et al. Vitreous and retinal amino acid concentrations in experimental central retinal artery occlusion in the primate. *Eye (Lond)*. 2005;19:455–463.
57. Jonas JB, Hayreh SS, Tao Y. Clinicopathological correlation of parapapillary atrophy in monkeys with experimental glaucoma and temporary central retinal artery occlusion. *Indian J Ophthalmol*. 2014;62:219–223.
58. Jonas JB, Hayreh SS. Optic disk morphology in experimental central retinal artery occlusion in rhesus monkeys. *Am J Ophthalmol*. 1999;127:523–530.
59. Hayreh SS, Jonas JB. Ophthalmoscopic detectability of the parafoveal annular reflex in the evaluation of the optic nerve: an experimental study in rhesus monkeys. *Ophthalmology*. 2000;107:1009–1014.
60. Petrig BL, Riva CE, Hayreh SS. Laser Doppler flowmetry and optic nerve head blood flow. *Am J Ophthalmol*. 1999;127:413–425.
61. Siskova A, Wilhelm J. The effects of hyperoxia, hypoxia, and ischemia/reperfusion on the activity of cytochrome oxidase from the rat retina. *Physiol Res*. 2001;50:267–273.
62. Prasad SS, Kojic L, Wen YH, et al. Retinal gene expression after central retinal artery ligation: effects of ischemia and reperfusion. *Invest Ophthalmol Vis Sci*. 2010;51:6207–6219.
63. Shabanzadeh AP, D’Onofrio PM, Monnier PP, Koeberle PD. Neurosurgical modeling of retinal ischemia-reperfusion injury. *J Stroke Cerebrovasc Dis*. 2018;27:845–856.
64. Inatani M, Tanihara H, Oohira A, et al. Upregulated expression of neurocan, a nervous tissue specific proteoglycan, in transient retinal ischemia. *Invest Ophthalmol Vis Sci*. 2000;41:2748–2754.
65. Wang L, Cull G, Cioffi GA. Depth of penetration of scanning laser Doppler flowmetry in the primate optic nerve. *Arch Ophthalmol*. 2001;119:1810–1814.
66. Chiou GC, Li BH. Effects of dopamine antagonists on retinal B-wave recovery after retinal ischemia. *J Ocul Pharmacol*. 1993;9:179–185.
67. Chiou GC, Li BH, Wang MS, et al. Facilitation of retinal function recovery by natural products after temporary ischemic occlusion of central retinal artery. *J Ocul Pharmacol*. 1994;10:493–498.
68. Wu BN, Hong SJ, Sheu MM, Chen IJ, Liu SX, Chiou GC. Vaninolol: a novel compound for the treatment of glaucoma and ischemic retinopathy. *J Ocul Pharmacol Ther*. 1995;11:213–220.
69. Liu SX, Chiou GC, Varma RS. Improvement of retinal functions after ischemia with L-arginine and its derivatives. *J Ocul Pharmacol Ther*. 1995;11:261–265.
70. Liu SX, Kapingu MC, Wang MS, Chiou GC. Facilitation of retinal function recovery by coumarin derivatives. *J Ocul Pharmacol Ther*. 1997;13:69–79.
71. Liu SX, Xuan BO, Chen Z, et al. Nitric oxide donors: effects of S-nitrosoglutathione and 4-phenyl-3-furoxan carbonitrile on ocular blood flow and retinal function recovery. *J Ocul Pharmacol Ther*. 1997;13:105–114.
72. Barnett NL, Osborne NN. Redistribution of GABA immunoreactivity following central retinal artery occlusion. *Brain Res*. 1995;677:337–340.
73. Sakamoto YR, Nakajima TR, Fukiage CR, et al. Involvement of calpain isoforms in ischemia-reperfusion injury in rat retina. *Curr Eye Res*. 2000;21:571–580.
74. Barnett NL, Pow DV, Bull ND. Differential perturbation of neuronal and glial glutamate transport systems in retinal ischaemia. *Neurochem Int*. 2001;39:291–299.
75. Karaman S, Ozkan B, Yazir Y, et al. Comparison of hyperbaric oxygen versus iloprost treatment in an experimental rat central retinal

- artery occlusion model. *Graefes Arch Clin Exp Ophthalmol*. 2016;254:2209–2215.
76. Szabo ME, Droy-Lefaix MT, Doly M, et al. Modification of ischemia/reperfusion-induced ion shifts (Na⁺, K⁺, Ca²⁺ and Mg²⁺) by free radical scavengers in the rat retina. *Ophthalmic Res*. 1993;25:1–9.
 77. Szabo ME, Droy-Lefaix MT, Doly M. Direct measurement of free radicals in ischemic/reperused diabetic rat retina. *Clin Neurosci*. 1997;4:240–245.
 78. Szabo ME, Gallyas E, Bak I, et al. Heme oxygenase-1-related carbon monoxide and flavonoids in ischemic/reperused rat retina. *Invest Ophthalmol Vis Sci*. 2004;45:3727–3732.
 79. Levy NS, Adams CK. Slow axonal protein transport and visual function following retinal and optic nerve ischemia. *Invest Ophthalmol*. 1975;14:91–97.
 80. Radius RL, Anderson DR. Morphology of axonal transport abnormalities in primate eyes. *Br J Ophthalmol*. 1981;65:767–777.
 81. Roth S, Rosenbaum PS, Osinski J, et al. Ischemia induces significant changes in purine nucleoside concentration in the retina-choroid in rats. *Exp Eye Res*. 1997;65:771–779.
 82. Szabo ME, Droy-Lefaix MT, Doly M, et al. Ischemia and reperfusion-induced histologic changes in the rat retina. Demonstration of a free radical-mediated mechanism. *Invest Ophthalmol Vis Sci*. 1991;32:1471–1478.
 83. Crosson CE, Willis JA, Potter DE. Effect of the calcium antagonist, nifedipine, on ischemic retinal dysfunction. *J Ocul Pharmacol*. 1990;6:293–299.
 84. Alder VA, Ben-Nun J, Cringle SJ. PO₂ profiles and oxygen consumption in cat retina with an occluded retinal circulation. *Invest Ophthalmol Vis Sci*. 1990;31:1029–1034.
 85. Wilson RS, McGrew RN, White HJ. Bilateral retinal artery and choriocapillaris occlusion following the injection of long-acting corticosteroid suspensions in combination with other drugs: II. Animal experimental studies. *Ophthalmology*. 1978;85:975–985.
 86. Morén H, Undrén P, Gesslein B, Olivecrona GK, Andreasson S, Malmjö M. The porcine retinal vasculature accessed using an endovascular approach: a new experimental model for retinal ischemia. *Invest Ophthalmol Vis Sci*. 2009;50:5504–5510.
 87. Morén H, Gesslein B, Undrén P, et al. Endovascular coiling of the ophthalmic artery in pigs to induce retinal ischemia. *Invest Ophthalmol Vis Sci*. 2011;52:4880–4885.
 88. Morén H, Gesslein B, Undrén P, Andreasson S, Malmjö M. Angiography and multifocal electroretinography show that blood supply to the pig retina may be both ipsilateral and contralateral. *Invest Ophthalmol Vis Sci*. 2013;54:6112–6117.
 89. Mutlu F, Leopold IH. Structure of the retinal vascular system of the dog, monkey, rat, mouse and cow. *Am J Ophthalmol*. 1964;58:261–270.
 90. Bloodworth JMJ, Gutgesell HPJ, Engerman RL. Retinal vasculature of the pig. Light and electron microscope studies. *Exp Eye Res*. 1965;4:174–178.
 91. De Schaepdrijver L, Simoens P, Pollet L, Lauwers H, De Laey JJ. Morphologic and clinical study of the retinal circulation in the miniature pig. B: Fluorescein angiography of the retina. *Exp Eye Res*. 1992;54:975–985.
 92. Albrecht May C. Comparative anatomy of the optic nerve head and inner retina in non-primate animal models used for glaucoma research. *Open Ophthalmol J*. 2008;2:94–101.
 93. Ollivier FJ, Samuelson DA, Brooks DE, Lewis PA, Kallberg ME, Komáromy AM. Comparative morphology of the tapetum lucidum (among selected species). *Vet Ophthalmol*. 2004;7:11–22.
 94. Wen GY, Sturman JA, Shek JW. A comparative study of the tapetum, retina and skull of the ferret, dog and cat. *Lab Anim Sci*. 1985;35:200–210.
 95. Mutlu F, Leopold IH. Structure of retinal vascular system of cat and rabbit. *Am J Ophthalmol*. 1964;57:804–814.
 96. De Schaepdrijver L, Simoens P, Lauwers H, De Geest JP. Retinal vascular patterns in domestic animals. *Res Vet Sci*. 1989;47:34–42.
 97. Cho KH, Ahn SJ, Cho JH, et al. The characteristics of retinal emboli and its association with vascular reperfusion in retinal artery occlusion. *Invest Ophthalmol Vis Sci*. 2016;57:4589–4598.
 98. Brown GC, Magargal LE. Central retinal artery obstruction and visual acuity. *Ophthalmology*. 1982;89:14–19.
 99. McLeod D, Beatty S. Evidence for an enduring ischaemic penumbra following central retinal artery occlusion, with implications for fibrinolytic therapy. *Prog Retin Eye Res*. 2015;49:82–119.
 100. Furashova O, Matthé E. Retinal changes in different grades of retinal artery occlusion: an

- optical coherence tomography study. *Invest Ophthalmol Vis Sci.* 2017;58:5209.
101. Hayreh SS, Zimmerman MB. Fundus changes in central retinal artery occlusion. *Retina.* 2007;27:276–289.
102. Koss MC. Analysis of blood flow in the long posterior ciliary artery of the cat. *Invest Ophthalmol Vis Sci.* 1999;40:800–804.
103. Hayreh SS. Anatomy and physiology of the optic nerve head. *Trans Am Acad Ophthalmol Otolaryngol.* 1974;78:OP240–54.