



Aalborg Universitet

AALBORG UNIVERSITY
DENMARK

Drug-induced ECG changes

beyond the QT interval

Graff, Claus; Matz, Jørgen; Andersen, Mads Peter; Kanters, Jørgen K.; Nielsen, Jimmi; Xue, Joel Q.; Toft, Egon; Struijk, Johannes

Publication date:
2009

Document Version
Early version, also known as pre-print

[Link to publication from Aalborg University](#)

Citation for published version (APA):

Graff, C., Matz, J., Andersen, M. P., Kanters, J. K., Nielsen, J., Xue, J. Q., Toft, E., & Struijk, J. (2009). *Drug-induced ECG changes: beyond the QT interval*. Abstract from Danish Annual Congress in Biomedical Engineering, Brædstrup, Denmark.

General rights

Copyright and moral rights for the publications made accessible in the public portal are retained by the authors and/or other copyright owners and it is a condition of accessing publications that users recognise and abide by the legal requirements associated with these rights.

- Users may download and print one copy of any publication from the public portal for the purpose of private study or research.
- You may not further distribute the material or use it for any profit-making activity or commercial gain
- You may freely distribute the URL identifying the publication in the public portal -

Take down policy

If you believe that this document breaches copyright please contact us at vbn@aub.aau.dk providing details, and we will remove access to the work immediately and investigate your claim.

27. Danske medicotekniske landsmøde

Claus Graff¹, Jørgen Matz², Mads P. Andersen¹, Jørgen K. Kanters³, Jimmi Nielsen⁴, Joel Q. Xue⁵, Egon Toft¹, Johannes, J. Struijk¹.

¹Department of Health Science and Technology, Aalborg University

²H. Lundbeck A/S, Copenhagen

³Department of Cardiology P, Gentofte University Hospital

⁴Aalborg Psychiatric Hospital, Aarhus University Hospitals

⁵GE Healthcare, Milwaukee, WI

DRUG-INDUCED ECG CHANGES: BEYOND THE QT INTERVAL

Electrocardiographic QT interval prolongation is one of the most common causes of delays and non-approvals in drug development due to the qualitative relationship between this interval and Torsade de Pointes (TdP) arrhythmia. However, not all drugs that prolong the QT interval to the same extent carry the same risk for TdP. Other ECG indications, such as abnormal T-wave morphology, may play a role in differentiating between safe and unsafe drugs.

We used moxifloxacin (non-Torsadogenic) and d,l-sotalol (Torsadogenic) to investigate whether concurrent changes for QT and T-wave morphology could be used to describe the discrepancy in proarrhythmic risk between the two drugs. T-wave morphology changes (Δ MCS) were quantified using a composite measure of flatness, asymmetry and notches. QT interval changes (Δ QTcF) were measured using standard ECG software.

Our results provide evidence that these drugs have significantly different morphology-duration profiles at similar QT prolongations, figure 1. These findings could have important implications for cardiac safety evaluation of new medications because they challenge the current practice of using a fixed QT threshold as the limit for regulatory concern.

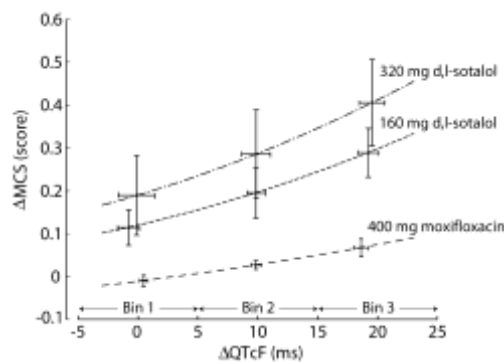


Fig. 1: The change in T-wave morphology (Δ MCS) for a given QT interval prolongation (Δ QTcF) appears to be drug and dose specific.