

Reduced gray matter brain volume and cortical thickness in adults with type 1 diabetes and neuropathy

Hansen, Tine Maria; Muthulingam, Janusiya Anajan; Brock, Birgitte; Drewes, Asbjørn Mohr; Juhl, Anne; Vorum, Henrik; Jakobsen, Poul Erik; Karmisholt, Jesper; Brock, Christina; Frøkjær, Jens Brøndum

Published in:
Neuroscience Research

DOI (link to publication from Publisher):
[10.1016/j.neures.2021.10.002](https://doi.org/10.1016/j.neures.2021.10.002)

Creative Commons License
CC BY 4.0

Publication date:
2022

Document Version
Publisher's PDF, also known as Version of record

[Link to publication from Aalborg University](#)

Citation for published version (APA):

Hansen, T. M., Muthulingam, J. A., Brock, B., Drewes, A. M., Juhl, A., Vorum, H., Jakobsen, P. E., Karmisholt, J., Brock, C., & Frøkjær, J. B. (2022). Reduced gray matter brain volume and cortical thickness in adults with type 1 diabetes and neuropathy. *Neuroscience Research*, 176, 66-72.
<https://doi.org/10.1016/j.neures.2021.10.002>

General rights


Copyright and moral rights for the publications made accessible in the public portal are retained by the authors and/or other copyright owners and it is a condition of accessing publications that users recognise and abide by the legal requirements associated with these rights.

- Users may download and print one copy of any publication from the public portal for the purpose of private study or research.
- You may not further distribute the material or use it for any profit-making activity or commercial gain
- You may freely distribute the URL identifying the publication in the public portal -

Take down policy

If you believe that this document breaches copyright please contact us at vbn@aub.aau.dk providing details, and we will remove access to the work immediately and investigate your claim.

Downloaded from vbn.aau.dk on: July 01, 2025



Reduced gray matter brain volume and cortical thickness in adults with type 1 diabetes and neuropathy

Tine Maria Hansen^{a,b}, Janusiya Anajan Muthulingam^{a,b}, Birgitte Brock^c,
Asbjørn Mohr Drewes^{b,d,e}, Anne Juhl^f, Henrik Vorum^{b,g}, Poul Erik Jakobsen^{e,h},
Jesper Karmisholt^{b,h}, Christina Brock^{b,d,e}, Jens Brøndum Frøkjær^{a,b,*}

^a Mech-Sense, Department of Radiology, Aalborg University Hospital, Hobrovej 18-22, 9000, Aalborg, Denmark

^b Department of Clinical Medicine, Aalborg University, Sønder Skovvej 15, 9000, Aalborg, Denmark

^c Steno Diabetes Center Copenhagen, Niels Steensens Vej 6, 2820, Gentofte, Denmark

^d Mech-Sense, Department of Gastroenterology & Hepatology, Aalborg University Hospital, Mølleparkvej 4, 9000, Aalborg, Denmark

^e Steno Diabetes Center North Denmark, Aalborg University Hospital, Sønder Skovvej 3E, 9000, Aalborg, Denmark

^f Department of Clinical Neurophysiology, Aalborg University Hospital, Ladegårdsgade 5, 9000, Aalborg, Denmark

^g Department of Ophthalmology, Aalborg University Hospital, Hobrovej 18-22, 9000, Aalborg, Denmark

^h Department of Endocrinology, Aalborg University Hospital, Mølleparkvej 4, 9000, Aalborg, Denmark

ARTICLE INFO

Keywords:

Diabetic neuropathy
Magnetic resonance imaging
Central nervous system
Peripheral nervous system
Brain atrophy
Diabetes

ABSTRACT

In this study we investigated brain morphology in adults with diabetic neuropathy. We aimed to characterize gray matter volume (GMV) and cortical thickness, and to explore associations between whole brain morphology and clinical characteristics. 46 adults with type 1 diabetes and distal symmetric peripheral neuropathy (DSPN) and 28 healthy controls underwent magnetic resonance imaging scans. GMV and cortical thickness were estimated using voxel-/surface-based morphometry. Associations between total GMV and clinical characteristics were explored. Adults with DSPN had reduced total GMV compared with controls (627.4 ± 4.1 mL vs. 642.5 ± 5.2 mL, $P = 0.026$). GMV loss was more pronounced for participants with painful neuropathy compared with controls (619.1 ± 8.9 mL vs. 642.4 ± 5.2 mL, $P = 0.026$) and for those with proliferative vs. non-proliferative retinopathy (609.9 ± 6.8 mL vs. 636.0 ± 4.7 mL, $P = 0.003$). Characteristics such as severity of neuropathy and decreased parietal N-acetylaspartate/creatinine metabolite concentration seem to be related to GMV loss in this cohort. Regional GMV loss was confined to bilateral thalamus/putamen/caudate, occipital and precentral regions, and decreased cortical thickness was identified in frontal areas. Since the observed total GMV loss influenced with clinical characteristics, brain imaging could be useful for supplementary characterization of diabetic neuropathy. The regional brain changes could suggest that some areas are more vulnerable in this cohort.

1. Introduction

Diabetic neuropathy is a serious complication to diabetes and affects both the peripheral and central nervous systems (Selvarajah et al., 2011). A reduction in brain gray matter volume (GMV) has been found in adults with type 1 diabetes and established diabetic polyneuropathy in comparison to adults with diabetes without neuropathy and healthy controls (Selvarajah et al., 2014). Furthermore, associations between GMV reductions and classical peripheral nerve testing have been reported, suggesting that presence of detectable peripheral diabetic

neuropathy is associated with total GMV (Selvarajah et al., 2014). Also, cortical atrophy has been identified in different disease stages of type 1 diabetes such as adolescents (Siller et al., 2017), adults with minimal diabetic complications (Musen et al., 2006) and adults with diabetic retinopathy (Wessels et al., 2006). These findings may indicate that hyper/hypoglycemia *per se* has an impact on total GMV (Musen et al., 2006), but also that brain atrophy may be associated with microvascular complications (Wessels et al., 2006) and neuropathy (Selvarajah et al., 2014).

In addition, regional GMV loss has been identified in specific brain

* Corresponding author at: Mech-Sense, Department of Radiology, Aalborg University Hospital, Hobrovej 18-22, 9000, Aalborg, Denmark.

E-mail address: jebf@rn.dk (J.B. Frøkjær).

<https://doi.org/10.1016/j.neures.2021.10.002>

Received 18 May 2021; Received in revised form 11 September 2021; Accepted 10 October 2021

Available online 14 October 2021

0168-0102/© 2021 The Author(s). Published by Elsevier B.V. This is an open access article under the CC BY license (<http://creativecommons.org/licenses/by/4.0/>).

regions (e.g., thalamus, the primary somatosensory cortex and supra-marginal gyrus), but to our knowledge only a few studies in relatively small sample sizes have investigated cortical thickness in adults with type 1 diabetes and polyneuropathy (Frøkjær et al., 2013; Selvarajah et al., 2019, 2014). Here, reduced cortical thickness in the right post-central gyrus was associated with the presence of peripheral neuropathy (Frøkjær et al., 2013), and reduced cortical thickness in the somatosensory cortex was shown in adults with severe painful distal symmetric polyneuropathy (DSPN) (Selvarajah et al., 2019).

Previously we also found that parietal N-acetylaspartate/creatine (NAA/cre) was associated to peripheral nerve dysfunction (Hansen et al., 2019) and that thalamic atrophy was associated with reduced thalamic NAA/cre in adults with DSPN (Hansen et al., 2021). The current study investigated this cohort further and we hypothesized that adults with type 1 diabetes and confirmed DSPN have decreased total GMV that was associated with clinical characteristics, severity of neuronal damage, and parietal NAA/cre ratio. The NAA/cre is a well-known marker for neuronal loss/dysfunction and thus could potentially be used as a surrogate marker for overall brain atrophy. We also hypothesized that regional GMV changes and reduced cortical thickness are present in the diabetes group compared to healthy controls. Thus, in a clinical well characterized cohort of adults with type 1 diabetes and severe DSPN, the primary aim was to characterize total GMV compared to healthy controls and explore associations with clinical characteristics and NAA/cre. Additionally, we aimed to characterize loss in regional GMV and identify areas with reduced cortical thickness compared to controls.

2. Materials and methods

2.1. Study population

Adults with type 1 diabetes were recruited at the Department of Endocrinology, Aalborg University Hospital, Denmark, between June 2014 and January 2017. Potential eligible patients were pre-screened based on a vibration perception threshold above 18 V (Bio-Medical Instruments, Newbury, OH, USA). Then DSPN was verified by neurophysiological testing according to the Toronto criteria (Tefsaye et al., 2010). Participants had a brain magnetic resonance imaging (MRI) scan at Department of Radiology, Aalborg University Hospital, Denmark, conducted no longer than one month apart from the neurophysiological assessment. Inclusion criteria were age above 18 years, verified diagnosis of type 1 diabetes for a minimum of 2 years (hemoglobin A1c (HbA1c) level $\geq 6.5\%$ [>48 mmol/mol]) and stable hyperglycemic medication. Exclusion criteria included type 2 diabetes, other neurological disorders than DSPN and estimated glomerular filtration rate < 60 mL/min/1.73m². Healthy participants were age-matched to the diabetes group and inclusion criteria was age above 18 years. Exclusion criteria included diabetes, neurological disorders and medication that could alter neuronal function.

Ethical approvals were obtained from Region Nordjylland, Denmark (N-20130077, N-20090008). All participants gave written informed consent prior to inclusion and were free to withdraw at any time. Data (diabetes cohort) used in this publication are secondary analyses performed on baseline data from a clinical trial investigating the anti-inflammatory effect of liraglutide (Brock et al., 2019), which was registered at EUDRA CT (ref 2013–004375-12) and clinicaltrials.gov (ref NCT02138045) and performed in accordance with International Council for Harmonization Good Clinical Practice and the Declaration of Helsinki.

2.2. Magnetic resonance imaging

A 3 T MRI-scanner (Signa HDxt, General Electrics, Milwaukee, WI, USA) was utilized to obtain a structural scan of the brain (with an eight-channel head coil). A high-resolution 3D T1-weighted anatomical scan

(BRAVO) was acquired covering the full head with field of view (FOV) 250 mm, echo time (TE) 3.6 ms, repetition time (TR) 9.0 ms, flip angle 14°, resolution 0.78 × 0.78 mm, matrix size 320 × 320 mm, slice thickness 1 mm, no gap.

2.3. MRI data processing

GMV and cortical thickness were estimated using voxel-based morphometry and surface-based morphometry analyses, respectively. Data were preprocessed and analyzed using the Computational Anatomy Toolbox (CAT12.2, r1290) implemented through SPM12 (Wellcome Trust Centre for Neuroimaging, London, UK). The voxel-based morphometry analysis was performed in the following steps: Normalization of the T1-weighted structural images to the Montreal Neurological Institute space using DARTEL and segmented into gray matter, white matter and cerebrospinal fluid (Ashburner et al., 2003). Bias correction was performed to remove intensity non-uniformities and images were normalized (1.5 × 1.5 × 1.5 mm), modulated and smoothed (8 mm Gaussian kernel). Statistical analysis was performed and regional GMV differences were estimated by a voxel-wise independent sample *t*-test with total intracranial volume and age as covariates. An absolute threshold mask of 0.1 was applied. Initial $P < 0.001$ uncorrected threshold was used and significance level of $P < 0.05$, uncorrected and family-wise error (FWE) corrected at the cluster level was applied for group comparisons. Significant clusters, which included thalamus have been published in a paper focusing on associations between thalamic volume and intra-thalamic metabolites, clinical/experimental characteristics of sensory function in this cohort (Hansen et al., 2021). The preprocessing steps for the surface-based morphometry analysis was identical to the voxel-based morphometry preprocessing, except that a projection-based thickness method was added to estimate cortical thickness using a fully automated method. Images were resampled into a template space and then smoothed with a 15 mm FWHM Gaussian kernel in order to analyze surface parameters. Group comparisons were performed using independent sample *t*-tests at $P < 0.001$ uncorrected threshold.

2.4. Clinical characteristics

Demographical data were collected and HbA_{1c} was assessed to characterize the diabetes cohort. Standardized peripheral nerve testing of the sural, peroneal, and tibial nerves were acquired and based on reference values from age-matched healthy from the local EMG laboratory a clinical neurophysiological composite score was calculated based on z-scores (Dyck et al., 1997).

Patients with painful neuropathy were identified using the interview part of the “Doleur neuropathique 4” (DN4) questionnaire where a cut-off value above or equal to 3 was used to identify painful DSPN (Spallone et al., 2012). Ophthalmological data was considered, and presence of proliferative/non-proliferative retinopathy was notified.

In short, parietal white matter NAA/cre was obtained from analysis of a magnetic resonance spectroscopy sequence (single voxel PRESS TR/TE = 2000/30 ms, size 15 × 15 × 20 mm). The post-processing analysis was performed in LCModel and more details are provided in our publication by Hansen et al. (Hansen et al., 2019).

2.5. Statistical analyses

Differences in characteristics between the diabetes group and healthy controls were assessed by independent-sample *t*-tests and chi-squared tests when appropriate. Mean ± standard deviation is presented unless otherwise stated. Univariate tests (ANCOVA) were used to compare differences in total GMV between groups (including subgroup analyses of painful/painless DSPN and proliferative/non-proliferative retinopathy) controlling for age and total intracranial volume as covariates and group as fixed factors. A full factorial model was used and

estimated marginal mean ± standard error of the mean was reported for total GMV, white matter volume and cerebrospinal fluid. The mean ± standard error and 95 % confidence interval (CI) for the group differences were provided. Furthermore, Pearson’s correlation analyses were used to investigate correlations between total GMV normalized for total intracranial volume and diabetic neuropathy severity assessed by the composite score, diabetes durations, age, HbA_{1c} and parietal NAA/cre ratio. Finally, total normalized GMV was further explored in a backward multiple regression analysis (cutoff $P < 0.1$) including all these characteristics. Statistical analyses were performed in IBM SPSS Statistics (IBM Corp. Released 2016. IBM SPSS Statistics for Windows, Version 25.0. Armonk, NY: IBM Corp.). $P < 0.05$ was considered significant.

3. Results

3.1. Demographics and data

48 adults with diabetes (38 men, mean age 50.0 ± 8.5 years) and 28 healthy controls (17 men, mean age 49.9 ± 11.9 years) were included. 46 MRI scans from diabetes subjects were included for analysis as one had claustrophobia and one recording was excluded due to poor data quality. Table 1 shows demographical and clinical data, partially previously published (Farmer et al., 2017; Hansen et al., 2021, 2019), and the key structural MRI brain estimates.

3.2. Total gray matter volume

Total GMV estimates are presented in Fig. 1. Total GMV estimates were significantly reduced in the group with diabetes and DSPN (627.4 ± 4.1 mL) compared to healthy controls (642.5 ± 5.2 mL) (-15.1 ± 6.6 mL, $F(1,70) = 5.2$, $P = 0.026$, 95 % CI for difference $[-28.3; -1.9$ mL]).

Total GMV estimates were significantly different between the subgroups (painful DSPN 619.1 ± 8.9 mL ($n = 10$), painless DSPN 629.7 ± 4.6 mL ($n = 36$) and controls 642.4 ± 5.2 mL, $F(2,69) = 3.2$, $P = 0.049$). The post-hoc test revealed a difference between participants with painful DSPN and controls (-23.3 ± 10.3 mL, $P = 0.026$, 95 % CI for difference $[-43.9; -2.8$ mL]), a borderline significant difference between participants with painless DSPN and controls (-12.6 ± 7.0 mL, $P =$

Table 1

Overview of demographical data, clinical data and structural brain measures.

	Adults with type 1 diabetes and DSPN, n = 48	Healthy controls, n = 28	P value
Sex (M/F)	38/10	17/11	0.08
Age (years)	50.0 ± 8.5	49.9 ± 11.9	0.98
BMI (kg/m ²)	28.3 ± 4.4	24.6 ± 2.6	0.001*
Diabetes duration (years)	32.2 ± 9.5		
HbA _{1c} (mmol/mol)	65.8 ± 10.2		
HbA _{1c} (%)	8.2 ± 0.9		
Painless DSPN, n (%)	36 (75)		
Painful DSPN, n (%)	12 (25)		
Non-proliferative DR, n (%)	33 (69)		
Proliferative DR, n (%)	15 (31)		
Neuropathy composite score	10.1 ± 4.1		
<i>Structural brain morphology</i>	n = 46	n = 28	
GMV (mL)‡	627.4 ± 4.1	642.5 ± 5.2	0.026*
WMV (mL)‡	559.6 ± 5.0	573.7 ± 6.4	0.085
CSF (mL)‡	374.8 ± 6.3	348.2 ± 8.0	0.011*
TIV (mL)	1606 ± 156	1621 ± 144	0.688

Notes: Data are expressed as mean ± standard deviations unless otherwise stated. * indicates significant findings, ‡adjusted for age and TIV and presented as mean ± standard error of the mean.

Abbreviations: DSPN: distal symmetric peripheral neuropathy; M: males; F: females; BMI: body mass index, DR: diabetic retinopathy; GMV: gray matter volume; WMV: white matter volume; CSF: cerebrospinal fluid; TIV: total intracranial volume.

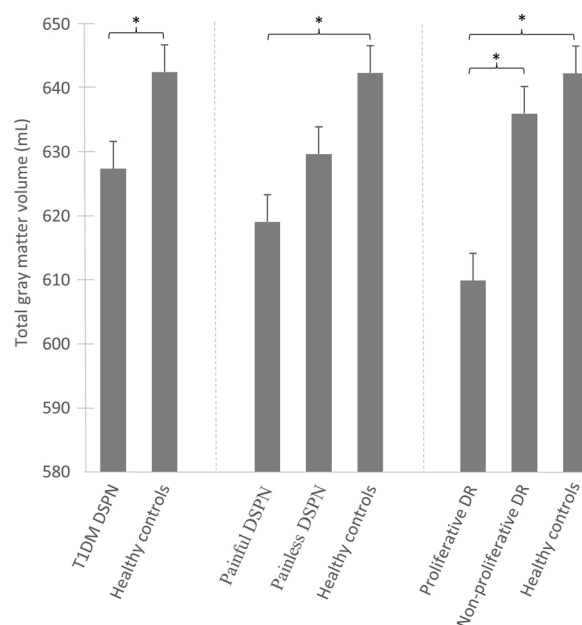


Fig. 1. Total GMV estimates (mean ± standard error) are shown for the group with type 1 diabetes (T1DM) and distal symmetric polyneuropathy (DSPN) ($n = 46$) compared to healthy controls ($n = 28$). The diabetes group was further divided into subgroups including painful DSPN ($n = 10$)/painless DSPN ($n = 36$) and proliferative diabetic retinopathy (DR)($n = 15$)/non-proliferative DR ($n = 31$) and compared to the healthy controls, respectively. * indicates significant findings with $P < 0.05$ (ANCOVA with age and total intracranial volume as covariates).

0.075, CI for difference $[-26.6; 1.3$ mL]), but no difference between participants with painful and painless DSPN (-10.7 ± 10.2 mL, $P = 0.30$, 95 % CI for difference $[-31.0; 9.7$ mL]).

Total GMV estimates were reduced in the subgroup where proliferative retinopathy was present (proliferative retinopathy 609.9 ± 6.8 mL ($n = 15$), non-proliferative retinopathy 636.0 ± 4.7 mL ($n = 31$) and controls 642.3 ± 4.9 mL, $F(2,69) = 7.7$, $P = 0.001$). The post-hoc test showed a difference between participants with proliferative retinopathy and controls (-32.4 ± 8.4 mL, $P < 0.001$, CI for difference $[-49.1; -15.6$ mL]), between participants with proliferative and non-proliferative retinopathy (-26.0 ± 8.4 mL, $P = 0.003$, CI for difference $[-42.9; -9.2$ mL]), but no differences between participants with non-proliferative retinopathy and controls (-6.3 ± 6.9 mL, $P = 0.36$, CI for difference $[-20.0; 7.4$ mL]).

The total GMV revealed associations with severity of polyneuropathy assessed by the neurophysiological composite score ($r = -0.46$, $P = 0.001$), diabetes duration ($r = -0.43$, $P = 0.003$), age ($r = -0.646$, $P < 0.001$) and parietal NAA/cre ($r = 0.43$, $P = 0.003$), but not with HbA_{1c} ($r = 0.16$, $P = 0.29$). In the backward multiple regression analysis increased age (coefficient: -0.17 %, $P < 0.001$), increased composite score (coefficient: -0.14 %, $P = 0.069$) and decreased parietal NAA/cre (coefficient: 3.7 %, $P = 0.096$) were independent predictors for GMV loss.

3.3. Regional gray matter volume and cortical thickness

In addition to our previously published results of reduced regional GMV in the diabetes cohort compared to controls in bilateral thalamic regions ($P_{FWE} \leq 0.001$) (Hansen et al., 2021), reduced regional GMV was also identified in the right inferior occipital gyrus ($P_{FWE} = 0.048$), left superior occipital gyrus ($P_{uncor} = 0.013$) and right precentral gyrus ($P_{uncor} = 0.026$), see Table 2 and Fig. 2. No regions showed increased GMV in the diabetes group as compared to healthy controls.

The diabetes group had reduced cortical thickness in comparison to

the controls in the left superior frontal gyrus/caudal middle frontal ($P_{FWE} < 0.001$), the right superior frontal gyrus ($P_{FWE} = 0.024$), the left pars opercularis ($P_{FWE} = 0.006$) and the right caudal middle frontal gyrus ($P_{FWE} = 0.018$), see Table 2 and Fig. 3. No regions showed increased cortical thickness in the diabetes group as compared to healthy controls.

4. Discussion

In this present study we found that adults with type 1 diabetes and confirmed distal symmetric peripheral neuropathy had reduced total gray matter volume as compared to healthy controls. The reduction was most pronounced in subgroups of participants with painful neuropathy and proliferative retinopathy. Furthermore, besides age as a predictor for gray matter volume loss, the severity of neuropathy and decreased parietal N-acetylaspartate/creatinine metabolite level were explanatory characteristics, even though the associations with brain atrophy were only borderline. Regional gray matter volume loss was confined to bilateral thalamus/putamen/caudate regions, occipital regions and right precentral gyrus, and decreased cortical thickness was identified in frontal areas.

4.1. Gray matter volume changes in general

Total and regional GMV loss have previously been identified in type 1 diabetes. Bednarik et al. reported total GMV to be decreased by 2.7 % in type 1 diabetes, whereas people with impaired awareness of hypoglycemia had a more pronounced decrease of 7.6 % compared to controls, plausibly due to long-term and recurrent neurotoxicity (Bednarik et al., 2017). In our study, GMV was reduced by 2.4 % in the diabetes group as compared to controls and markedly reduced by 5.0 % in the subgroup with proliferative retinopathy which is also a microvascular complication to long-term hyperglycemia exposures. Furthermore, our findings are supported by the general acceptance of proliferative retinopathy as a marker of general microangiopathy, and the severity of retinopathy has previously been associated to both structural brain changes (Musen et al., 2006; Wessels et al., 2006) and to micro bleedings (Woerdeman et al., 2014).

Total GMV loss has been observed in type 1 diabetes with diabetic neuropathy (with and without pain) as compared to subjects with diabetes without neuropathy and healthy subjects (Selvarajah et al., 2014). It was reported that GMV loss was associated with reduced peroneal nerve conduction velocity, increased neurophysiological composite scores and elevated vibration detection thresholds (Selvarajah et al., 2014). Our study showed a similar association between total GMV loss

and increased neurophysiological composite scores, which could indicate a co-existence of peripheral neuropathy and central neuropathies. A reduction in GMV has been shown in response to several conditions with chronic pain (Apkarian et al., 2004; Kumbhare et al., 2017). Albeit not significant, the mean GMV of the group with slight pain was lower in comparison to the subgroup with no pain. This could be due to the fact that the subgrouping into painless vs. painful subjects was based upon patient reported outcome of the DN4 questionnaire with a cut-off value of 3, and in the painful group the mean DN4 score was 3.8 reflecting a small proportion of slight pain. Furthermore, as this was explored in unequal sizes of subgroups (painful/painless participants), it could be suggested that these differences should be further investigated in larger cohorts where a subgroup of participants with higher pain intensities should be included. The observed reduction in the parietal NAA/creatinine metabolite ratio could indicate central neuronal dysfunction or loss (Hansen et al., 2019). Decreased parietal NAA/creatinine was associated with gray matter atrophy and thus could potentially be used as a simple marker to indicate overall neuronal integrity in diabetes. Since multiple measures are also known to be related to aging, it is difficult to clearly identify the role of aging from the role of diabetes induced neurodegeneration. The multiple regression analysis indicates that besides age as a strong predictor, other diabetes related factors could be explanatory variables for increased brain atrophy.

Overall, the reduction in total GMV may be unspecific in nature and seems to be influenced by several disease-related factors (Drewes et al., 2016; Seaquist, 2010). It could potentially reflect stages of diabetes-induced neurodegenerative processes, cerebral microvascular diseases, accelerated brain aging, or a combination of these mechanisms. However, future studies should be conducted to investigate these different mechanisms in further detail.

4.2. Regional brain changes

Gray matter loss was confined to several regional brain regions in this cohort. Besides our previous investigations showing changes in bilateral thalamus/putamen/caudate regions (Hansen et al., 2021), decreased volume was also found in occipital regions and in the right precentral gyrus. Thalamic atrophy is probably the most consistently reported regional volumetric finding in type 1 diabetes (Moulton et al., 2015), and more studies showed evidence of involvement of the thalamus in DSPN (Hansen et al., 2021; Selvarajah et al., 2008), which plausibly is related to altered conveyance of sensory transmission in the spino-thalamo-cortical tract in diabetic neuropathy. Specifically, our recent publication showed that thalamic atrophy in this cohort was associated with reduced thalamic metabolites, impaired large/small

Table 2

Regions with changes in gray matter volume and cortical thickness between adults with diabetes and DSPN and healthy subjects.

Region name	MNI coordinate x y z			Voxels	Z-score	$P_{uncorrected}$	P_{FWE}
<i>Regional gray matter loss</i>							
Thalamus/putamen/caudate, L #	-9	12	8	3178	5.17	<0.001*	<0.001*
Thalamus/putamen, R #	20	-3	8	1541	4.65	<0.001*	0.001*
Inferior occipital gyrus, R	21	-93	-5	633	3.91	0.006*	0.048*
Superior occipital gyrus, L	-26	-77	26	499	4.26	0.013*	0.100
Precentral gyrus, R	45	5	18	381	4.26	0.026*	0.194
<i>Cortical thickness reduction</i>							
Superior frontal gyrus/caudal middle frontal, L	29	28	41	473	4.42	<0.001*	<0.001*
Superior frontal gyrus, R	-14	40	47	133	3.88	0.012*	0.024*
Pars opercularis, L	53	12	12	176	4.55	0.003*	0.006*
Caudal middle frontal gyrus, R	-41	11	52	143	4.12	0.018*	0.009*

Notes: MNI (Montreal Neurological Institute) peak coordinates (x,y,z), cluster sizes (voxels), Z-scores and P-values for results of the SPM analyses are presented. The (x,y,z) peak coordinate represents the coordinate for the voxel with the highest statistical value for each cluster. All regions presented showed decreased volume and cortical thickness reduction for adults with diabetes and DSPN as compared to healthy controls. No regions showed increased volume for the diabetes group compared to healthy controls. * indicates significant findings with $P < 0.05$. # from Hansen et al. (Hansen et al., 2021).

Abbreviations: L: left; R: right; FWE: family-wise error corrected.

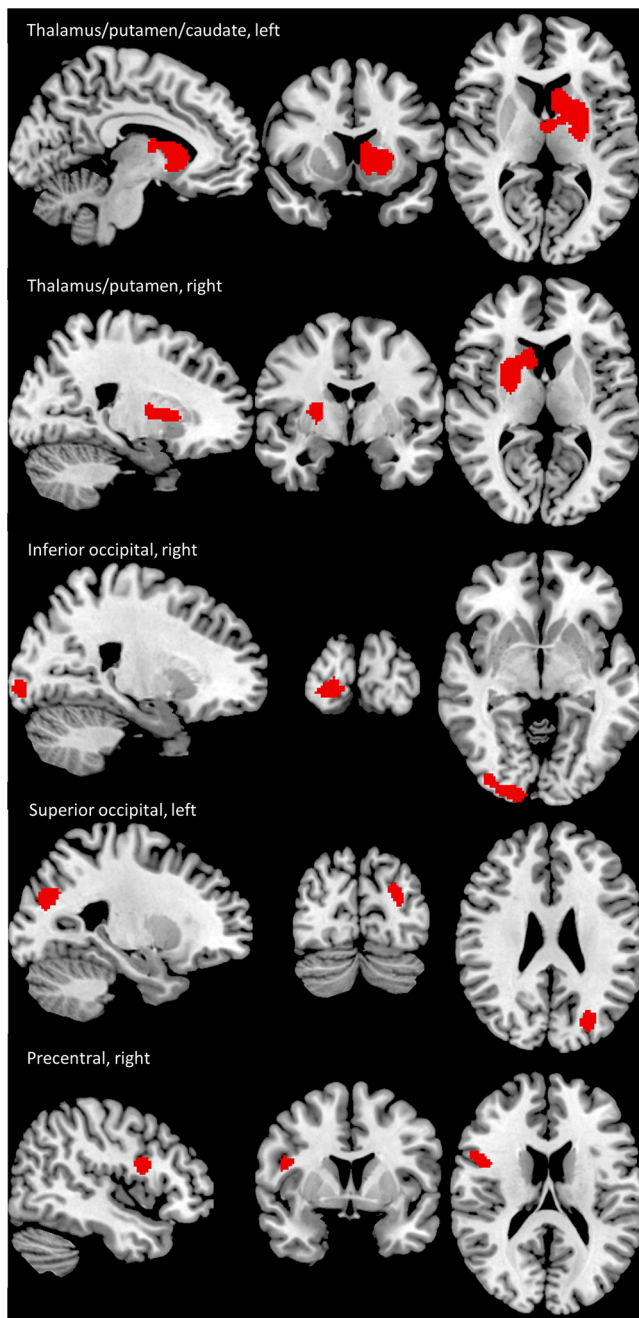


Fig. 2. Regions with decreased gray matter volume (illustrated in red) in adults with diabetes and distal symmetric peripheral neuropathy as compared to healthy subjects (For interpretation of the references to colour in this figure legend, the reader is referred to the web version of this article).

fiber function, and indirect measures of synaptic transmission (Hansen et al., 2021). In addition, we found GMV loss in occipital regions. Wessel et al. showed that patients with diabetic retinopathy had reduced gray matter density in the right inferior frontal gyrus and right occipital lobe in comparison to patients without retinopathy and healthy controls (Wessels et al., 2006). The authors suggested that this reduction was associated with microvascular origin rather than diabetes in itself, supported by the findings of no associations between reduced gray matter density and HbA_{1c}, diabetes duration, onset of diabetes or blood pressure (Wessels et al., 2006). In contrast to these findings, a study in type 2 diabetes revealed reduced occipital GMV in patients without retinopathy, where the authors concluded that GMV loss in occipital regions may be present in diabetic patients even before retinal damage

occurs (Ferreira et al., 2017). Our findings cannot explain the cause of GMV loss in the occipital lobe, but total GMV loss was more pronounced in the subgroup with proliferative retinopathy.

Our findings also showed GMV loss in the precentral region, which is consistent with a recent study reporting decreased precentral gyral thickness in painful DSPN (Selvarajah et al., 2019). The precentral gyrus is highly connected to the postcentral gyrus, hosting the final projections of the spino-thalamo-cortical tract. Accordingly, another study by Frøkjær et al. showed reduced postcentral cortical thickness in adults with peripheral neuropathy as compared to adults without peripheral neuropathy (Frøkjær et al., 2013). In our present study, we identified decreased cortical thickness in the superior and caudal middle frontal gyri and left pars opercularis as compared to healthy subjects. Reduced volume of the frontal lobe has been related to impaired awareness of hypoglycemia (Bednarik et al., 2017). The frontal lobe is also involved in regulation of blood glucose levels (DeVore and Harrison, 2017), and the findings may indicate that some of these patients could have impairment of the glycemic control.

4.3. Limitations

This study investigated a relatively large and homogeneous cohort of type 1 diabetes with confirmed DSPN. However, whether the observed brain changes are due to diabetes *per se*, the presence of diabetic neuropathy or microangiopathy leading to proliferative retinopathy cannot be concluded based on the existing cross-sectional design. Furthermore, the role of aging, including aging of the brain, body age or cognitive tasks should ideally be included in future studies as well as other disease related co-factors and clinical characteristics. Even though there was no significant difference between groups in gender, the diabetes group included relatively more men compared to the control group. Gender differences in head size was indirectly accounted for by adjusting for total intracranial volume. However, it could be relevant to investigate gender differences further in larger studies, as it for example in type 2 diabetes has been shown that females likely suffer from more brain complications than men (Hempel et al., 2012). In this study, associations between whole brain morphology and specific clinical characteristics were explored, but it would also be relevant to investigate regional atrophy and cortical thinning in relation to larger groups of well-defined diabetic phenotypes. Finally, further studies including longitudinal cohorts are needed to establish causalities between diabetes status and brain changes, taking potential co-factors and subgroups with and without diabetic complications into account.

5. Conclusions

Our study revealed loss of total gray matter brain volume in a cohort of adults with type 1 diabetes and confirmed distal symmetric peripheral neuropathy. Furthermore, regional atrophy and cortical thinning were present in multiple regions, including areas involved in sensory processing and occipital areas. The subgroups with painful neuropathy, proliferative retinopathy had increased total gray matter loss and besides age as a prominent factor, severe neuropathy and decreased parietal NAA/cre metabolite could be potential contributing factors. In conclusion, we confirmed that structural brain alteration is a key finding in diabetic neuropathy. Exploration of the brain in diabetes could play a key role in establishing a deeper understanding and better characterization of diabetic neuropathy. Such better phenotyping, including imaging biomarkers of the brain, could in the future help to understand neuropathy development, potentially identify early neuropathy, and optimize and monitor future interventions targeting the neuropathy.

Funding

The study was supported by the Novo Nordisk Scandinavia AS; and Empowering Industry and Research EIR Northern Jutland, Denmark.

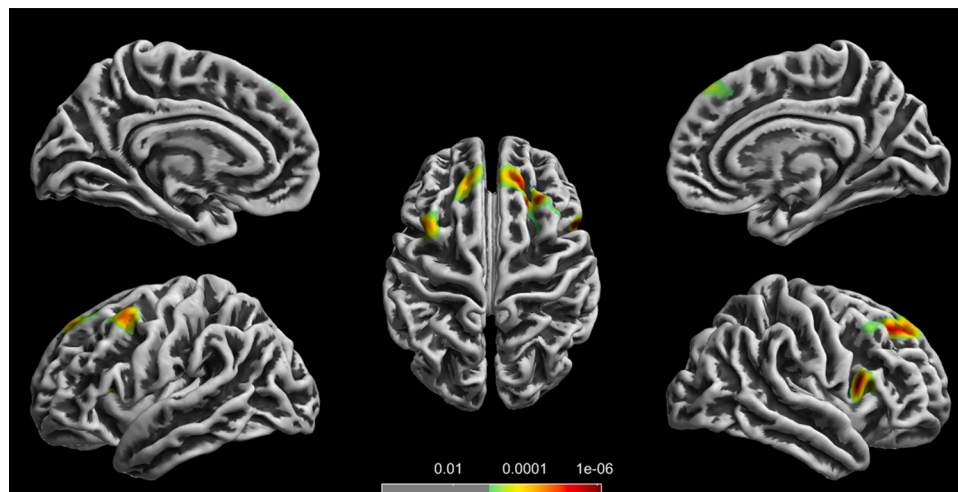


Fig. 3. Regions with decreased cortical thickness for adults with diabetes and distal symmetric peripheral neuropathy compared with healthy subjects. Red illustrates highest probability (For interpretation of the references to colour in this figure legend, the reader is referred to the web version of this article).

The study was investigator-initiated and -driven and the study sponsor was not involved in the design of the study; the collection, analysis, and interpretation of data; writing the report; and did not impose any restrictions regarding the publication of the manuscript.

Author contributions

Study design and original idea B.B., A.M.D., C.B., J.B.F.; Data collection and analysis T.M.H., J.A.M., B.B., A.M.D., A.J., H.V., P.E.J., J. K., C.B. and J.B.F.; Drafting of the manuscript T.M.H., J.A.M., C.B., and J.B.F.; B.B., A.M.D., A.J., H.V., P.E.J., J.K. contributed to the literature search preparation of the manuscript and critical revisions therein regarding important intellectual content. All authors have approved the final manuscript.

Declaration of Competing Interest

None.

Acknowledgments

K.K. Jensen, Department of Radiology, Aalborg University Hospital, Aalborg, Denmark is acknowledged for his assistance in MRI data collection.

References

- Apkarian, A.V., Sosa, Y., Sonty, S., Levy, R.M., Harden, R.N., Parrish, T.B., Gitelman, D. R., 2004. Chronic back pain is associated with decreased prefrontal and thalamic gray matter density. *J. Neurosci.* 24, 10410–10415. <https://doi.org/10.1523/JNEUROSCI.2541-04.2004>.
- Ashburner, J., Csernansky, J.G., Davatzikos, C., Fox, N.C., Frisoni, G.B., Thompson, P.M., 2003. Computer-assisted imaging to assess brain structure in healthy and diseased brains. *Lancet Neurol.* 2, 79–88. [https://doi.org/10.1016/s1474-4422\(03\)00304-1](https://doi.org/10.1016/s1474-4422(03)00304-1).
- Bednarik, P., Moheet, A.A., Grohn, H., Kumar, A.F., Eberly, L.E., Seaquist, E.R., Mangia, S., 2017. Type 1 diabetes and impaired awareness of hypoglycemia are associated with reduced brain gray matter volumes. *Front Neurosci.* 11 <https://doi.org/10.3389/fnins.2017.00529>.
- Brock, C., Hansen, C.S., Karmisholt, J., Møller, H.J., Juhl, A., Farmer, A.D., Drewes, A.M., Riahi, S., Lervang, H.H., Jakobsen, P.E., Brock, B., 2019. Liraglutide treatment reduced interleukin-6 in adults with type 1 diabetes but did not improve established autonomic or polyneuropathy. *Br. J. Clin. Pharmacol.* 85, 2512–2523. <https://doi.org/10.1111/bcp.14063>.
- DeVore, B.B., Harrison, D.W., 2017. Brain mechanisms in blood glucose mobilization and absorption: the role of the left and the right frontal regions in the regulatory control of blood glucose levels. *Diabetes Res.* 3, 17–19. <https://doi.org/10.17140/droj-3-131>.
- Drewes, A.M., Søfteland, E., Dimcevski, G., Farmer, A.D., Brock, C., Frøkjær, J.B., Krogh, K., Drewes, A.M., 2016. Brain changes in diabetes mellitus patients with gastrointestinal symptoms. *World J. Diabetes* 7, 14–16. <https://doi.org/10.4239/wjd.v7.i2.14>.
- Dyck, P.J., Davies, J.L., Litchy, W.J., O'Brien, P.C., 1997. Longitudinal assessment of diabetic polyneuropathy using a composite score in the Rochester Diabetic Neuropathy Study cohort. *Neurology* 49, 229–239. <https://doi.org/10.1212/wnl.49.1.229>.
- Farmer, A.D., Pedersen, A.G., Brock, B., Jakobsen, P.E., Karmisholt, J., Mohammed, S.D., Scott, S.M., Drewes, A.M., Brock, C., 2017. Type 1 diabetic patients with peripheral neuropathy have pan-enteric prolongation of gastrointestinal transit times and an altered caecal pH profile. *Diabetologia* 60, 709–718. <https://doi.org/10.1007/s00125-016-4199-6>.
- Ferreira, F.S., Pereira, J.M.S., Reis, A., Sanches, M., Duarte, J.V., Gomes, L., Moreno, C., Castelo-Branco, M., 2017. Early visual cortical structural changes in diabetic patients without diabetic retinopathy. *Graefes Arch. Clin. Exp. Ophthalmol.* 255, 2113–2118. <https://doi.org/10.1007/s00417-017-3752-4>.
- Frøkjær, J., Brock, C., Søfteland, E., Dimcevski, G., Gregersen, H., Simrén, M., M. Drewes, A., 2013. Macrostructural brain changes in patients with longstanding type 1 diabetes mellitus - a cortical thickness analysis study. *Exp. Clin. Endocrinol. Diabetes* 121, 354–360. <https://doi.org/10.1055/s-0033-1345120>.
- Hansen, T.M., Brock, B., Juhl, A., Drewes, A.M., Vorum, H., Andersen, C.U., Jakobsen, P. E., Karmisholt, J., Frøkjær, J.B., Brock, C., 2019. Brain spectroscopy reveals that N-acetylaspartate is associated to peripheral sensorimotor neuropathy in type 1 diabetes. *J. Diabetes Complicat.* 33, 323–328. <https://doi.org/10.1016/j.jdiacomp.2018.12.016>.
- Hansen, T.M., Frøkjær, J.B., Selvarajah, D., Muthulingam, J.A., Tesfaye, S., Juhl, A., Drewes, A.M., Jakobsen, P.E., Karmisholt, J., Brock, B., Brock, C., 2021. Reduced thalamic volume and metabolites in type 1 diabetes with polyneuropathy. *Exp. Clin. Endocrinol. Diabetes.* Online ahead of print.
- Hempel, R., Onopa, R., Convit, A., 2012. Type 2 diabetes affects brain health differentially in men and women. *Diabetes Metab. Res. Rev.* 28, 76–83. <https://doi.org/10.1002/dmrr.1230>.
- Kumbhare, D.A., Elzibak, A.H., Noseworthy, M.D., 2017. Evaluation of chronic pain using magnetic resonance (MR) neuroimaging approaches what the clinician needs to know. *Clin. J. Pain* 33, 281–290. <https://doi.org/10.1097/AJP.0000000000000415>.
- Moulton, C.D., Costafreda, S.G., Horton, P., Ismail, K., Fu, C.H., 2015. Meta-analyses of structural regional cerebral effects in type 1 and type 2 diabetes. *Brain Imaging Behav.* 9, 651–662. <https://doi.org/10.1007/s11682-014-9348-2>.
- Musen, G., Lyoo, I.K., Sparks, C.R., Weinger, K., Hwang, J., Ryan, C.M., Jimerson, D.C., Hennen, J., Renshaw, P.F., Jacobson, A.M., 2006. Effects of type 1 diabetes on gray matter density as measured by voxel-based morphometry. *Diabetes* 55, 326–333. <https://doi.org/10.2337/diabetes.55.02.06.db05-0520>.
- Seaquist, E.R., 2010. The final frontier: how does diabetes affect the brain? *Diabetes* 59, 4–5. <https://doi.org/10.2337/db09-1600>.
- Selvarajah, D., Wilkinson, I.D., Emery, C.J., Shaw, P.J., Griffiths, P.D., Gandhi, R., Tesfaye, S., 2008. Thalamic neuronal dysfunction and chronic sensorimotor distal symmetrical polyneuropathy in patients with type 1 diabetes mellitus. *Diabetologia* 51, 2088–2092. <https://doi.org/10.1007/s00125-008-1139-0>.
- Selvarajah, D., Wilkinson, I.D., Davies, J., Gandhi, R., Tesfaye, S., 2011. Central nervous system involvement in diabetic neuropathy. *Curr. Diab. Rep.* 11, 310–322. <https://doi.org/10.1007/s11892-011-0205-z>.
- Selvarajah, D., Wilkinson, I.D., Maxwell, M., Davies, J., Sankar, A., Boland, E., Gandhi, R., Tracey, I., Tesfaye, S., 2014. Magnetic resonance neuroimaging study of brain structural differences in diabetic peripheral neuropathy. *Diabetes Care* 37, 1681–1688. <https://doi.org/10.2337/dc13-2610>.
- Selvarajah, D., Wilkinson, I.D., Fang, F., Sankar, A., Davies, J., Boland, E., Harding, J., Rao, G., Gandhi, R., Tracey, I., Tesfaye, S., 2019. Structural and functional abnormalities of the primary somatosensory cortex in diabetic peripheral

- neuropathy: a multimodal MRI study. *Diabetes* 68, 796–806. <https://doi.org/10.2337/db18-0509>.
- Siller, A.F., Lugar, H., Rutlin, J., Koller, J.M., Semenkovich, K., White, N.H., Arbelaez, A. M., Shimony, J., Hershey, T., 2017. Severity of clinical presentation in youth with type 1 diabetes is associated with differences in brain structure. *Pediatr. Diabetes* 18, 686–695.
- Spallone, V., Morganti, R., D'Amato, C., Greco, C., Cacciotti, L., Marfia, G.A., 2012. Validation of DN4 as a screening tool for neuropathic pain in painful diabetic polyneuropathy. *Diabet. Med.* 29, 578–585. <https://doi.org/10.1111/j.1464-5491.2011.03500.x>.
- Tesfaye, S., Boulton, A.J., Dyck, P.J., Freeman, R., Horowitz, M., Kempner, P., Lauria, G., Malik, R.A., Spallone, V., Vinik, A., Bernardi, L., Valensi, P., Toronto Diabetic Neuropathy Expert Group, 2010. Diabetic neuropathies: update on definitions, diagnostic criteria, estimation of severity, and treatments. *Diabetes Care* 33, 2285–2293. <https://doi.org/10.2337/dc10-1303>.
- Wessels, A.M., Simsek, S., Remijnse, P.L., Veltman, D.J., Biessels, G.J., Barkhof, F., Scheltens, P., Snoek, F.J., Heine, R.J., Rombouts, S.A.R.B., 2006. Voxel-based morphometry demonstrates reduced grey matter density on brain MRI in patients with diabetic retinopathy. *Diabetologia* 49, 2474–2480. <https://doi.org/10.1007/s00125-006-0283-7>.
- Woerdeman, J., Van Duinkerken, E., Wattjes, M.P., Barkhof, F., Snoek, F.J., Moll, A.C., Klein, M., De Boer, M.P., IJzerman, R.G., Serné, E.H., Diamant, M., 2014. Proliferative retinopathy in type 1 diabetes is associated with cerebral microbleeds, which is part of generalized microangiopathy. *Diabetes Care* 37, 1165–1168. <https://doi.org/10.2337/dc13-1586>.