

T2*-weighted placental magnetic resonance imaging

a biomarker of placental dysfunction in small-for-gestational-age pregnancies

Hansen, Ditte N.; Sinding, Marianne; Petersen, Astrid; Christiansen, Ole B.; Uldbjerg, Niels; Peters, David A.; Frøkjær, Jens B.; Sørensen, Anne

Published in:

American journal of obstetrics & gynecology MFM

DOI (link to publication from Publisher):

[10.1016/j.ajogmf.2022.100578](https://doi.org/10.1016/j.ajogmf.2022.100578)

Creative Commons License

CC BY-NC-ND 4.0

Publication date:

2022

Document Version

Publisher's PDF, also known as Version of record

[Link to publication from Aalborg University](#)

Citation for published version (APA):

Hansen, D. N., Sinding, M., Petersen, A., Christiansen, O. B., Uldbjerg, N., Peters, D. A., Frøkjær, J. B., & Sørensen, A. (2022). T2*-weighted placental magnetic resonance imaging: a biomarker of placental dysfunction in small-for-gestational-age pregnancies. *American journal of obstetrics & gynecology MFM*, 4(3), Article 100578. <https://doi.org/10.1016/j.ajogmf.2022.100578>

General rights

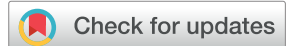Copyright and moral rights for the publications made accessible in the public portal are retained by the authors and/or other copyright owners and it is a condition of accessing publications that users recognise and abide by the legal requirements associated with these rights.

- Users may download and print one copy of any publication from the public portal for the purpose of private study or research.
- You may not further distribute the material or use it for any profit-making activity or commercial gain
- You may freely distribute the URL identifying the publication in the public portal -

Take down policy

If you believe that this document breaches copyright please contact us at vbn@aub.aau.dk providing details, and we will remove access to the work immediately and investigate your claim.

T2*-weighted placental magnetic resonance imaging: a biomarker of placental dysfunction in small-for-gestational-age pregnancies



Ditte N. Hansen, MD, PhD; Marianne Sinding, MD, PhD; Astrid Petersen, MD; Ole B. Christiansen, DMSc; Niels Uldbjerg, DMSc; David A. Peters, MSc, PhD; Jens B. Frøkjær, MD, PhD; Anne Sørensen, MD, PhD

BACKGROUND: The antenatal identification of placental dysfunction in small-for-gestational-age fetuses with normal fetal Doppler flows remains an obstetrical challenge. In a significant fraction of such pregnancies, placental dysfunction is revealed by clinical manifestations such as preeclampsia, preterm delivery, or severe small-for-gestational-age at birth or by abnormal findings in the postnatal placental histologic examination. Therefore, new methods to identify placental function directly in pregnancy at the time of small-for-gestational-age diagnosis is highly needed.

T2*-weighted placental magnetic resonance imaging is sensitive to changes in placental morphology and oxygenation and is thereby related to placental function. Previous studies have demonstrated that pregnancies complicated by low birthweight and preeclampsia are characterized by low placental T2* values. However, the specific performance of placental T2* in the prediction of placenta-related outcomes in small-for-gestational-age pregnancies with normal fetal Doppler flows remains to be explored.

OBJECTIVE: In small-for-gestational-age pregnancies with normal fetal Doppler flows, we aimed to evaluate T2*-weighted placental magnetic resonance imaging as an antenatal biomarker of placental dysfunction. In addition, we aimed to investigate the correlation between placental T2* and Doppler flow measurements of fetal and uterine arteries at the time of magnetic resonance imaging.

STUDY DESIGN: In this prospective cohort study, the inclusion criterion was suspected small-for-gestational-age (ultrasound estimated fetal weight Z-score ≤ -2.0 [2.3rd centile]) with normal fetal Doppler flows (middle cerebral artery pulsatility index Z-score > -2.0 and umbilical artery pulsatility index Z-score < 2.0). The T2*-weighted placental magnetic resonance imaging scan was performed at inclusion in a 1.5 T system. The outcomes was placental dysfunction at birth defined by low birthweight (Z-score ≤ -2.0), preeclampsia, preterm delivery (gestational age < 37 weeks), or abnormal placental histologic examination such as placental vascular malperfusion according to the Amsterdam Consensus Statement.

RESULTS: We included 92 pregnancies at 26+5 to 39+6 weeks gestation. The median time interval between the magnetic resonance imaging

scan and birth was 4.6 weeks (interquartile range, 2.7–7.8 weeks). At birth, 55% (51/92) of pregnancies revealed at least 1 sign of placental dysfunction; 49% (40/81) had abnormal placental histologic examination, 29% (27/92) were born with low birthweight, 13% (12/92) were delivered preterm, and 7% (6/92) had preeclampsia.

When adjusted for gestational age at magnetic resonance imaging, the placental T2* Z-score was a significant predictor of abnormal placental histologic examination (area under the curve, 0.73; $P=.001$), small-for-gestational-age at birth (area under the curve, 0.63; $P=.030$), preeclampsia (area under the curve, 0.88; $P=.005$), and preterm delivery (area under the curve, 0.81; $P=.001$).

The placental T2* was reduced in pregnancies with a combination of clinical manifestations and abnormal placental histologic examination (T2* Z-score = -1.52 ± 1.35 [mean \pm standard deviation]; $P=.0001$) and in clinically uneventful pregnancies with abnormal placental histologic examination (T2* Z-score = -0.79 ± 0.97 ; $P=.045$).

At the time of magnetic resonance imaging, the placental T2* Z-score showed a significant linear correlation with the uterine artery pulsatility index Z-scores ($r=-0.24$; $P=.016$) and the middle cerebral artery pulsatility index Z-scores ($r=0.29$; $P=.017$) but not with the umbilical artery pulsatility index Z-scores ($r=0.18$; $P=.17$) and the cerebroplacental ratio ($r=0.03$; $P=.77$).

CONCLUSION: This study indicates that placental dysfunction is frequent in small-for-gestational-age fetuses with normal fetal Doppler flows. In this cohort, T2*-weighted placental magnetic resonance imaging is a sensitive biomarker of placental dysfunction regardless of the clinical manifestations. This finding supports a paradigm shift in the conception of placental dysfunction that may cover a wide spectrum of clinical and subclinical manifestations.

Key words: Doppler flow, histologic examination, magnetic resonance imaging, placenta, placental dysfunction, placental, preterm delivery, T2* relaxation, transverse relaxation, vascular malperfusion

Introduction

The antenatal identification of placental dysfunction is of utmost clinical importance as it may improve neonatal outcomes through adequate fetal surveillance and timely delivery.^{1,2} The most frequently used biomarker of placental dysfunction is small-for-gestational-age (SGA) fetuses, which are estimated by ultrasound using different cut-offs, reflecting local standards or national agreements. Such SGA fetuses are further

characterized by ultrasound Doppler flow measurements of fetal circulation. It is well-described that abnormal fetal Doppler flows reflect fetal hypoxia and acidosis³, and abnormal fetal Doppler flows are considered as a late manifestation of severe placental dysfunction.² However, in less severe placental dysfunction, fetal Doppler flows may be within the normal range. This point is missing from the editing process, should therefore be: “However, in less severe

Cite this article as: Hansen DN, Sinding M, Petersen A, et al. T2*-weighted placental magnetic resonance imaging: a biomarker of placental dysfunction in small-for-gestational-age pregnancies. *Am J Obstet Gynecol MFM* 2022;4:100578.

2589-9333/\$36.00

© 2022 The Author(s). Published by Elsevier Inc. This is an open access article under the CC BY-NC-ND license (<http://creativecommons.org/licenses/by-nc-nd/4.0/>) <http://dx.doi.org/10.1016/j.ajogmf.2022.100578>

AJOG MFM at a Glance

Why was this study conducted?

In small-for-gestational-age (SGA) fetuses with normal fetal Doppler flows, placental dysfunction may be present. However, antenatal identification of the same is challenging.

Key findings

In 92 SGA pregnancies with normal fetal Doppler flows, T2*-weighted placental magnetic resonance imaging was performed shortly after the diagnosis of SGA. In 55% of pregnancies, placental dysfunction was revealed by the presence of clinical manifestations and/or abnormal placental histology. Placental T2* was a significant predictor of each of these outcomes.

What does this add to what is known?

Placental dysfunction is frequent among suspected SGA fetuses with normal fetal Doppler flows. Placental T2* is a sensitive biomarker of placental dysfunction regardless of the clinical manifestations.

placental dysfunction, fetal Doppler flows may be within normal range, and therefore the identification remains an obstetric challenge with current clinical methods.”

Placental dysfunction may lead to obstetrical complications such as low birthweight (BW), preeclampsia, and preterm delivery,^{4,5} but the ultimate evidence of placental dysfunction is the abnormal postnatal placental histologic examination.^{6–8} Placental histology has previously been challenged by inconsistencies in sampling strategies and diagnostic criteria. However, much of this debate has been overcome by the Amsterdam Placental Workshop Consensus Statement.⁹ However, the clinical significance of abnormal placental histology in the absence of clinical manifestations remains a matter of debate.

We hypothesize that T2*-weighted placental magnetic resonance imaging (MRI) is a biomarker of placental dysfunction in suspected SGA fetuses. The T2* value is a robust tissue constant that reflects not only tissue morphology but also tissue oxygenation, as it is sensitive to the concentration of deoxyhemoglobin in the tissue.¹⁰ This hypothesis is also supported by the association between low placental T2* values and placenta-related complications of pregnancy such as fetal growth restriction and gestational hypertensive disorders.^{11–14} However, the clinical performance of placental T2* in the

identification of placental dysfunction in SGA fetuses with normal fetal Doppler flows remains unexplored. This method is clinically relevant, as the T2* value can be obtained from the placenta with a 1-minute MRI scan, which has become available at most hospitals. Furthermore, the examination is now considered safe in pregnancy when performed at 1.5 to 3 Tesla.¹⁵

Therefore, we aimed to evaluate T2*-weighted placental MRI as a biomarker of placental dysfunctions such as low BW, preeclampsia, preterm delivery, and abnormal placental histologic examination in SGA fetuses with normal fetal Doppler flows. In addition, we aimed to investigate the correlation between placental T2* and the Doppler flow measurements of the fetal and uterine arteries at the time of MRI.

Materials and Methods

The study was conducted at Aalborg University Hospital from February 1, 2018 to November 13, 2019. The inclusion criteria were singleton pregnancies with an ultrasound estimated fetal weight (EFW) Z-score ≤ -2.0 of the expected for gestational age (GA)¹⁶ and normal Doppler flows (umbilical artery [UA] pulsatility index [PI] Z-score < 2.0 ¹⁷ and middle cerebral artery [MCA] PI Z-score > -2.0).¹⁷ The exclusion criteria were gestational age below 24 weeks of gestation, maternal age < 18 years, non-Danish speaking, severe

fetal malformation, and severe maternal claustrophobia.

Outcomes as placental dysfunction were defined as the following: (1) SGA at birth defined as BW Z-score ≤ -2.0 ¹⁶ (2.3rd centile), (2) preeclampsia defined in accordance with the International Society for the Study of Hypertension in Pregnancy international consensus criterion,¹⁸ (3) preterm delivery before 37+0 weeks of gestation, and (4) abnormal placental histologic examination with maternal or fetal vascular malperfusion.⁹

All the participating women gave written informed consent. The study was approved by The North Denmark Region Committee on Health Research Ethics, N-20170052. Data collection and handling were approved by a regional notification to the Danish Data Protection Agency, 2017-148. The data were collected and managed using Research Electronic Data Capture “REDCap”¹⁹ hosted at Aalborg University Hospital, North Denmark Region.

Ultrasound

Ultrasound scans were performed by Fetal Medicine Foundation-certified doctors and sonographers using GE Voluson™ E10 (GE Healthcare, Milwaukee, WI). All the pregnancies were dated by crown-rump length performed in the first trimester.²⁰ The EFW was derived using the Hadlock’s formula (head circumference, abdominal circumference, and femur length)²¹, and deviation from normal was calculated using the reference curve from Maršál et al.¹⁶ The Doppler flow measurements were registered as PI and were converted into Z-scores (GA-adjusted) using the reference curve by Parra-Cordero et al¹⁷ for both the UA and MCA and Gómez et al²² for the uterine artery (UtA). The cerebroplacental ratio was calculated as a ratio between the MCA and UA and was converted to Z-scores (GA-adjusted) using the reference by Baschat and Gembruch.²³

Magnetic resonance imaging

Placental MRI was performed in a 1.5 Tesla wide-bore 70 cm system (GE Optima™ MR450w, GE Healthcare,

Milwaukee, WI) using the anterior body array coil and the coil elements within the scanning table. The T2*-weighted placental MRI scan was obtained using 16 echoes (echo time [TE]₁₆: 3.0 msec –67.5 msec in steps of 4.3 msec, repetition time [TR]: 71.2 msec, flip angle: 30°, spacing: 20.0 mm, slice thickness: 8.0 mm, field of view [FOV]: 38.0 × 38.0 cm, frequency: 256, and phase: 160). Five slices were acquired oriented transversal of the placenta, each of them in a single breath hold of 12 seconds. The regions of interest (ROI) were manually drawn in the 3 slices with the best coverage of the entire placental cross-section using a “MATLAB-based” software developed inhouse (MathWorks, Natick, MA). Data analysis was performed prospectively by a single observer (D.N.H.), who was blinded to all the clinical outcomes; the obstetricians were blinded to the placental T2* value. Each MRI scan was evaluated for susceptibility artifacts and uterine contractions.²⁴ None of the 92 T2*-weighted MRI scans were excluded from the analysis. The T2* value was obtained using the average signal within each ROI, fitted as a function of the echo times using monoexponentially decaying function with the equilibrium magnetization (M₀) and T2* as a free parameter and a nonlinear least-squares fitting algorithm.²⁵ Placental T2* (msec) was calculated as a mean of 3 slices. The placental T2* values were converted to Z-scores adjusted for GA at MRI according to previously published normal reference values.¹¹

Biochemistry

All the participating women had blood samples taken on the day of MRI. The blood sample testing included testing for hemoglobin, sodium, potassium, creatinine, albumin, glycated hemoglobin, platelets, D-dimer, activated partial thromboplastin clotting time, international normalized ratio, fibrinogen, antithrombin, uric acid, lactate dehydrogenase, alanine aminotransferase, alkaline phosphatase, and bilirubin.

Placental histologic examination

The placental histologic examination was performed by a single experienced placenta pathologist (A.P.) according to the Amsterdam Consensus Statement.⁹ The pathologist was blinded to the MRI findings but not to the clinical outcomes. Abnormal placental histologic examination in this study was defined simply as vascular malperfusion of either maternal or fetal type. Placental findings indicating maternal vascular malperfusion (MVM) include placental hypoplasia (weight below 10th centile and/or thin umbilical cord (<8 mm at term or below 10th centile), infarctions, retroplacental hemorrhage, decidual arteriopathy, accelerated villous maturation, and distal villous hypoplasia. Fetal vascular malperfusion is because of any obstruction to the fetal blood flow (eg, umbilical cord lesions, hypercoagulability, cardiac dysfunction) and includes thrombosis and/or obliteration of the fetal vessels, fibrous avascular villi, and villous karyorrhexis.

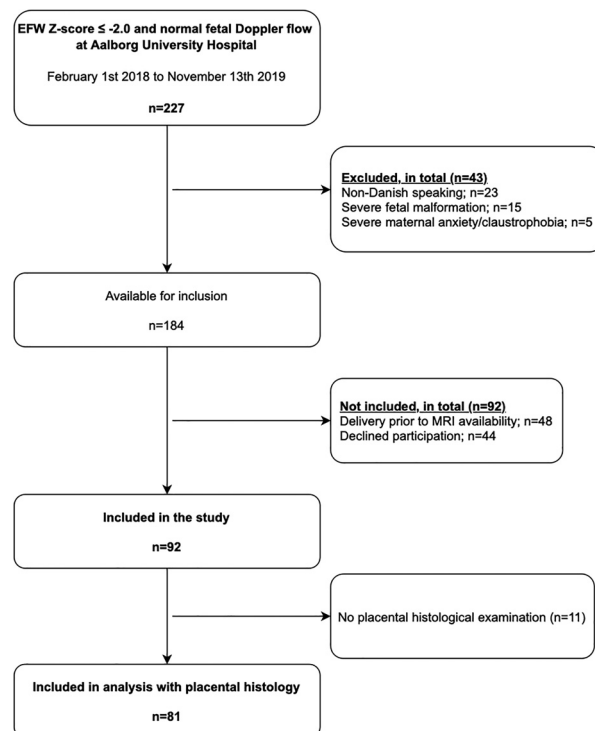
Statistical analyses

The predictive performance of placental T2* regarding the 4 placenta-related outcomes was investigated using logistic regression and receiver operating curves (ROC) and reported as area under the ROC curves (AUC). The mean GA-adjusted placental T2* values (Z-scores) were calculated for each subgroup of placental dysfunction and compared with normal pregnancies using the Student *t* test. Simple linear regression and Pearson's correlations coefficients were used to investigate the correlation between the placental T2* Z-score and the scores of each of the 3 Doppler flows; UA PI Z-score, MCA PI Z-score, and mean UtA PI Z-score. Statistical analyses were performed using Stata, version 15.1 (Stata Corp, College Station, TX). *P* values <.05 were considered statistically significant.

Results

During the study period, 227 pregnant women were eligible for enrollment. 43

FIGURE 1
Flowchart of the study population



EFW, estimated fetal weight; MRI, magnetic resonance imaging.

Hansen. Placental T2* in small-for-gestational-age pregnancies. *Am J Obstet Gynecol MFM* 2022.

TABLE 1
Characteristics of the study population

Characteristics	Total cohort N=92
Maternal characteristics	
Maternal age (y)	29 (26.5–34)
Pregestational maternal BMI (kg/m ²)	23.1 (20.6–26.6)
Smoking at first trimester scan	16/92 (17.4)
Nullipara	42/92 (45.7)
Pregestational coagulation disease	0/92
Maternal diabetes	8/92 (8.7)
Pregnancy at time of inclusion	
EFW deviation at time of inclusion (%) ^a	–24.8 (–27.0 to –23.2)
Umbilical artery PI Z-score ^b at inclusion	0.103 (–0.569 to 1.116)
Middle cerebral artery PI Z-score ^b at inclusion	–0.179 (–0.821 to 0.454)
Cerebroplacental ratio Z-score ^c at inclusion	–0.146 (–1.012 to 0.402)
GA at inclusion (wk)	30.3 (27.9–33.2)
Pregnancy at time of MRI	
EFW deviation at time of MRI (%) ^a	–22.9 (–27.1 to –19.0)
Abnormal uterine artery Doppler flow ^d (mean PI Z-score>2.000) at time of MRI	13/85 (15.3)
GA at MRI (wk)	33.5 (30.6–36.0)
Time between MRI and birth (wk)	4.6 (2.7–7.8)
Delivery characteristics	
GA at birth (wk)	39.0 (37.8–40.1)
Birthweight (g)	2730 (2440–2975)
Birthweight deviation ^a (%)	–20.0 (–22.5 to –14.2)
Extreme small-for-gestational-age (≤–33%)	8/92 (8.7)
Boys	33/92 (35.9)
Vaginal delivery	66/92 (71.7)
Induction of delivery	38/92 (41.3)
Acute cesarean delivery	8/92 (8.7)

The data are presented as median (interquartile range) or number (percent).

BMI, body mass index; EFW, estimated fetal weight; GA, gestational age; MRI, magnetic resonance imaging; PI, pulsatility index.

Measurements were adjusted for GA (percent or Z-scores) using the following references:

^a Maršál et al,¹⁶ ^b Parra-Cordero et al,¹⁷ ^c Baschat and Gembruch,²³ and; ^d Gómez et al.²²

Hansen. Placental T2* in small-for-gestational-age pregnancies. *Am J Obstet Gynecol MFM* 2022.

women were excluded, and 184 were available for inclusion. 44 declined participation, and 48 delivered before MRI. Accordingly, 92 participants were included in this study (Figure 1). The maternal characteristics and obstetrics outcomes for the recruited and non-recruited women are presented in Supplementary, Table S1.

Placental MRI was performed at gestational week 26+5 to 39+6, and the median time interval between this MRI and birth was 4.6 weeks (interquartile range, 2.7–7.8 weeks) (Table 1). T2*-weighted placental images are added in Supplementary, Figure S1, and a scatter plot demonstrating the T2* value as a function of GA is provided in Supplementary, Figure S2.

At birth, 55% (51/92) of the women revealed at least 1 of the outcomes related to placental dysfunction; 29% (27/92) revealed low birthweight, 7% (6/92) preeclampsia, 13% (12/92) preterm birth, and 49% (40/81) abnormal placental histologic examination. The cases of preterm deliveries are described in detail in Supplementary, Table S2.

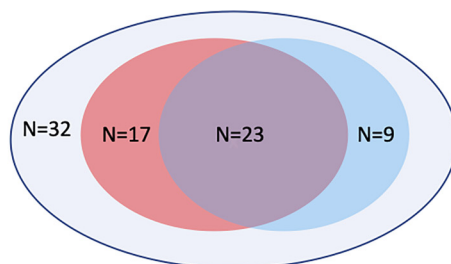
Several pregnancies showed a combination of outcomes related to placental dysfunction. The proportion of abnormal placental histologic examination was 73.1% in SGA at birth, 81.8% in preterm deliveries, 100% in pregnancies complicated by preeclampsia, and 21.0% in clinically uneventful pregnancies (Figure 2 and Supplementary, Table S3).

Figure 2 illustrates the distribution of outcomes among the 81 pregnancies that underwent placental histologic examination. In the 49 pregnancies complicated by placental dysfunction (clinical manifestations and/or abnormal placental histologic examination), the placental T2* was significantly reduced (Z-score: -1.10 ± 1.22 [mean \pm standard deviation]) when compared with the 32 normal pregnancies (Z-score: -0.14 ± 1.09), $P=.0006$. In the 9 pregnancies with clinical manifestations of placental dysfunction but normal placental histologic examination, the placental T2* remained within the normal range (Z-score: -0.58 ± 1.01); $P=.29$. In contrast, in the 17 pregnancies with abnormal placental histologic examination without clinical manifestations, the placental T2* was significantly reduced (Z-score: -0.79 ± 0.97); $P=.045$. Pregnancies with a combination of clinical manifestations and abnormal placental histologic examination showed the most significant reduction in placental T2* (Z-score: -1.52 ± 1.35); $P=.0001$.

The predictive performance of the placental T2* Z-score in relation to the outcomes related to placental dysfunction was evaluated by ROC curves, and the results were as follows: AUC=0.88 for preeclampsia ($P=.005$), AUC=0.81 for preterm delivery ($P=.001$), AUC=0.73 for abnormal placental histologic examination ($P=.001$), AUC=0.72 for placental dysfunction ($P=.002$), and AUC=0.63 for low BW ($P=.030$) (Figure 3).

FIGURE 2

Placenta-related outcomes in pregnancies with placental histologic examination (n = 81)



Area	N = 81	Placenta T2* Z-score Mean (SD)	p-value
Purple: Abnormal placental histological examination and clinical manifestations	23	-1.52 (1.35)	0.0001
Red: Isolated abnormal placental histological examination	17	-0.79 (0.97)	0.045
Blue: Isolated clinical manifestations	9	-0.58 (1.01)	0.287
Red+Blue+Purple: Clinical manifestations and/or abnormal placental histological examination	49	-1.10 (1.22)	0.0006
Grey: Normal placental histological examination and no clinical manifestations	32	-0.14 (1.09)	Reference
No histology	N = 11		
No clinical manifestations	9	-0.68 (1.33)	0.220
Clinical manifestations	2	-1.44 (1.43)	0.114

Grey area: Normal placental histologic examination and no clinical manifestations (reference group). *Red area:* abnormal placental histologic examination. *Blue area:* clinical manifestations of placental dysfunction. *Purple area:* abnormal placental histologic examination and clinical manifestations of placental dysfunction.

SD, standard deviation.

Hansen. Placental T2* in small-for-gestational-age pregnancies. *Am J Obstet Gynecol MFM* 2022.

A linear correlation was demonstrated between the placental T2* Z-score and the UtA PI Z-score ($r=-0.24$; $P=.016$) and MCA PI Z-score ($r=0.29$; $P=.017$) but not with UA PI Z-score ($r=0.18$; $P=.17$) or cerebroplacental ratio Z-score ($r=0.03$; $P=.77$) at the time of MRI (Figure 4).

Discussion

Principal findings

In a cohort of SGA fetuses with normal fetal Doppler flows, placental dysfunction was revealed in more than half of the pregnancies. In this cohort, antenatal T2*-weighted placental MRI was a significant predictor of placenta-related

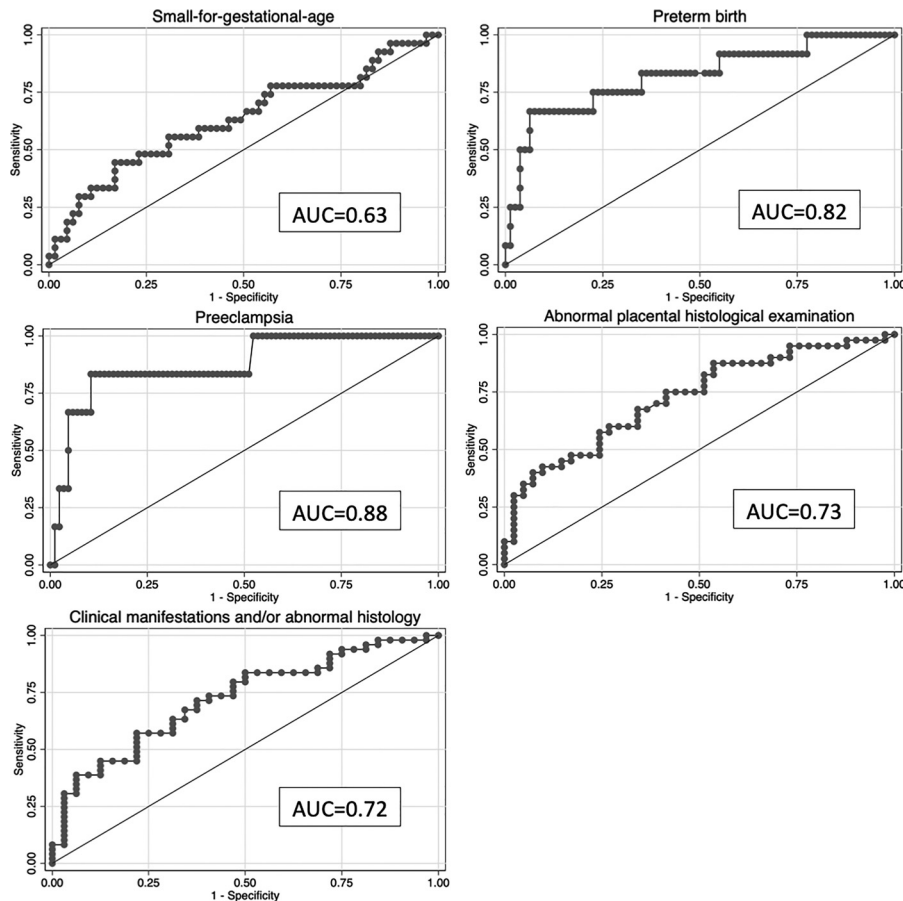
outcomes such as placental vascular malperfusion, SGA at birth, preeclampsia, and preterm delivery. Placental T2* was a sensitive biomarker of placental dysfunction before abnormal fetal Doppler findings regardless of the clinical manifestations. Thus, placental T2* has the potential to complement Doppler flow measurements and thereby improve the identification of placental dysfunction in SGA fetuses.

Strengths and limitations

Placental T2* examination was conducted in accordance with a protocol that has been meticulously evaluated,^{11,26} and the placental histologic examination was

performed by a single, trained pathologist using the Amsterdam criteria; the pathologist was blinded to the placental T2* values. The inclusion of placental histologic examination in this study allows for the identification of subclinical placental dysfunction, which is a major strength of this study. Of the 227 patients eligible for inclusion, only 92 were included. However, only minor differences were demonstrated between the recruited and nonrecruited patients, as the pregestational body mass index was lower and abnormal MCA PI before delivery was present more in the nonrecruited group. Accordingly, the proportion of placental pathology among the suspected SGA

FIGURE 3
ROC curves for placental T2* and outcomes related to placental dysfunction



Clinical manifestations and/or abnormal placental histology includes clinical manifestations such as either small-for-gestational-age at birth, and/or preeclampsia, and/or preterm birth <37 weeks of gestation, and/or abnormal placental histologic examination.

AUC, area under the ROC curve; ROC, receiver operating characteristics.

Hansen. Placental T2* in small-for-gestational-age pregnancies. *Am J Obstet Gynecol MFM* 2022.

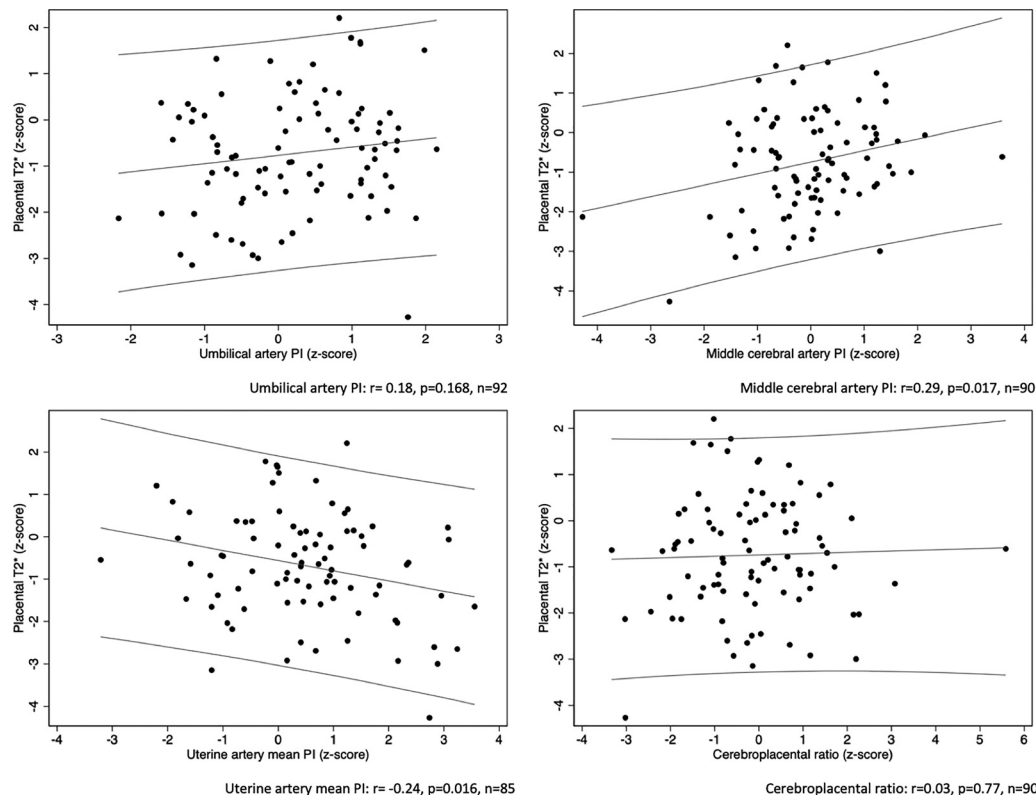
fetuses with normal Doppler flows may be slightly underestimated in this study. As demonstrated by T2*-weighted placental images, there is no visual differences between the cases at equivalent GA. Previous publication has demonstrated visual differences between extreme cases of placental dysfunction and normal controls.¹¹ However, such visual findings are not apparent in this cohort of less pathologic pregnancies. Therefore, the T2* value needs to be estimated to separate the groups. This highlights the strength of the quantitative T2* value, which can be easily obtained.

The limitations were that the pathologist, in accordance with the clinical routine at the department, was not blinded

to the obstetrical outcomes. The MRI scans were performed at a wide range of gestations, and 46% were conducted after 34 weeks of gestation. As the predictive performance of placental T2* may change with the GA at MRI, this may have affected our results. In 11 pregnancies, the placenta was not sent for histologic examination postpartum. Most of these pregnancies (n=9/11) were clinically uneventful pregnancies with normal BWs. In these pregnancies, placental histologic examination was not performed for clinical purposes, and the staff was not aware that the patient was enrolled. For the 2 cases with clinical manifestations, 1 was delivered in another hospital and 1 was simply missed by the staff. In

addition, the placental histologic examination was dichotomized as being either normal or abnormal, according to placental vascular malperfusion. In a larger setting, the placental histologic examination should be described and analyzed with greater details and thereby further divided into gradings of severity. In this study, we used an SGA cutoff Z-score ≤ -2.0 (2.3rd centile), which is in accordance with our national guidelines.²⁷ We could have used another SGA cutoff, such as 10th centile, regardless of the fetal Doppler flow measures.²⁸ However, had we used such a cutoff, the proportion of pregnancies truly complicated by placental dysfunction in this study would have been markedly decreased.

FIGURE 4
Correlation between placental T2* and Doppler flow measurements



The linear relation between placental T2* Z-score and UA PI Z-score (left top), MCA PI Z-score (right top), uterine artery mean PI Z-score (left bottom), and cerebroplacental ratio (right bottom) measured at time of MRI and 95% prediction interval. Pearson correlation coefficient (r). Z-scores are adjusted for gestational age using the following references: Placental T2*: Sinding et al,¹¹ UA PI and MCA PI: Parra-Cordero et al,¹⁷ uterine artery mean PI: Gómez et al²² and cerebroplacental ratio: Baschat and Gembruch.²³

MCA, middle cerebral artery; PI, pulsatility index; UA, umbilical artery.

Hansen. Placental T2* in small-for-gestational-age pregnancies. *Am J Obstet Gynecol MFM* 2022.

Results

In this study, placental dysfunction was revealed in 55% of pregnancies. The most frequent finding was abnormal placental histologic examination, and the proportion of abnormal placental histologic examination was higher in pregnancies with clinical manifestations of placental dysfunction. However, abnormal placental histologic examination was also seen in pregnancies without clinical manifestations of placental dysfunction. In this group, the placental T2* was significantly reduced. This finding underlines that abnormal placental histologic examination should be regarded a sign of placental dysfunction even when the pregnancy is uneventful

and fetal weight is within the normal range. This finding is important, as it highlights that placental dysfunction may be more frequent than previously assumed. However, the short- and long-term consequences of such subclinical placental dysfunction need to be further investigated. Moreover, subclinical placental dysfunction should be considered in the evaluation of future biomarkers of placental dysfunction.

The placental T2* Z-score was a predictor of SGA at birth. However, the performance of placental T2* in this current study (AUC=0.63) is much lower than in a previous study using exactly the same placental MRI protocol (AUC=0.92).¹² This difference may be

related to different populations of the 2 studies. The previous study included a wide range of pregnancies, some of them complicated by severe placental dysfunction. In contrast, in the current study, we included only SGA pregnancies with normal fetal Doppler flows. The inclusion of less severe cases of placental dysfunction tends to challenge the predictive performance of placental T2*.

According to our data, the placental T2* Z-score is a predictor of preeclampsia. This finding is in line with previous case-control studies demonstrating a lower placental T2* value in cases of preeclampsia and chronic hypertension when compared with normal

controls.^{13,29} We found abnormal placental histologic examination in all cases of preeclampsia, which underlines the high degree of placental pathology in preeclampsia.

Placental T2* was also a predictor of preterm delivery, and most of the pregnancies with preterm delivery also revealed abnormal placental histologic examination (9/11, as 1 case had no placental histologic examination). Within this group of preterm delivery, 67% were delivered because of placenta-related complications of pregnancy. The remaining 33% had preterm premature rupture of membranes (PPROM). PPRM may not be directly related to placental dysfunction. However, previous literature has demonstrated associations with vascular lesions, for example, accelerated villous maturation, which is also part of MVM.^{5,30}

According to our data, placental T2* can identify placental dysfunction in SGA pregnancies with normal fetal Doppler flows. This finding suggests that placental T2* is more sensitive to placental dysfunction than current fetal Doppler flow measurements. We demonstrated a significant correlation between placental T2* and the PIs of MCA and UtA. Surprisingly, we failed to demonstrate any correlation between placental T2* and the cerebroplacental ratio, which may be a result of a nonsignificant correlation between the placental T2* and UA PI.

The placental T2* and Doppler flow measurements may reflect the same placental pathology to some extent. However, the correlations are weak, indicating that the methods may also reflect different aspects of placental dysfunction. Changes in the T2* values reflect altered tissue morphology and tissue hypoxia,¹⁰ whereas UtA PI reflects the resistance of the spiral arteries, which is also related to placental perfusion but not directly related to placental hypoxia.^{8,31,32} The MCA PI reflects the fetal redistribution of blood flow because of fetal hypoxia,³ and therefore shows a significant correlation with placental T2*. However, the UA PI reflects downstream resistance of the fetoplacental vasculature, which may

not be affected in mild cases of placental dysfunction. Therefore, a direct marker of placental function such as placental T2* may be more sensitive to early stages of placental dysfunction than fetal Doppler flow measurements. In this study, we reported Doppler flow measurements such as PI Z-score rather than the binary outcome, normal or abnormal. The correlation between placental T2* and the PI Z-scores for MCA and UtA underlines the high value of a continuous scale to reflect the broad spectrum of placental dysfunction in this cohort.

Clinical implications

Placental dysfunction has a wide range of clinical and subclinical manifestations and may accordingly be more frequent than previously anticipated.

This study suggests that the antenatal identification of placental dysfunction among SGA fetuses with normal fetal Doppler flows may be improved by T2*-weighted placental MRI.

The clinical implementation of placental MRI may be challenged by limited availability and high cost. However, these practical aspects may be outweighed by the clinical gain of this method, and accordingly, they should not limit research in this promising field.

Research implications

Our findings indicate that placental T2* may be more sensitive to placental dysfunction than fetal Doppler flow measurements. The timing of changes in placental T2* in relation to the progression in placental dysfunction and changes in fetal Doppler flow measurements needs to be further elucidated by longitudinal studies of high-risk pregnancies starting in the early second trimester.

The clinical value of placental T2* needs to be explored in other clinical cohorts such as pregnancies complicated by diabetes^{33–35} and late-onset placental dysfunction.^{36,37} In such pregnancies, the predictive performance of fetal Doppler flow is particularly limited, and additional methods focusing directly on placental function are highly

needed to improve the antenatal identification of placental dysfunction. In such pregnancies, the benefit of a direct placental marker such as T2* may be even higher than what we observed in this current cohort of SGA pregnancies.

In this study, subclinical placental dysfunction such as abnormal placental histologic examination in clinical uneventful pregnancies was revealed by T2*-weighted placental MRI. The clinical relevance of such findings and the prognostic value of the antenatal detection of this condition needs to be explored. Our study underlines that placental dysfunction is a wide spectrum of diseases. New studies are needed to investigate the clinical significance of subclinical placental dysfunction.

Conclusion

Our study demonstrates that T2*-weighted placental MRI is a sensitive biomarker of placental dysfunction in SGA pregnancies. Placental T2* can identify placental dysfunction when fetal Doppler flows are normal, even in the absence of clinical manifestations. Thus, this finding supports a paradigm shift in the conception of placental dysfunction *in vivo*. Placental dysfunction includes a wide range of clinical and subclinical manifestations, and placental dysfunction may be more frequent than previously assumed. Our findings highlight the strength of biomarkers focusing directly on placental function to complement methods focusing on fetal size and fetal well-being. ■

ACKNOWLEDGMENTS

We would like to thank radiographers Kenneth Krogh Jensen, BSc and Louise Bach Jensen, BSc Aalborg University Hospital, for their expert assistance with the magnetic resonance imaging examinations and their professional feedback. In addition, we would like to thank histotechnicians at the Department of Pathology, Aalborg University Hospital for tissue processing of the placentas. We would also like to acknowledge all the midwives and doctors at the Department of Obstetrics and Gynecology, Aalborg University Hospital for their assistance in patient recruitment and collecting placentas postpartum.

Supplementary materials

Supplementary material associated with this article can be found in the online version at doi:10.1016/j.ajogmf.2022.100578.

References

- Lindqvist PG, Molin J. Does antenatal identification of small-for-gestational age fetuses significantly improve their outcome? *Ultrasound Obstet Gynecol* 2005;25:258–64.
- Baschat AA. Planning management and delivery of the growth-restricted fetus. *Best Pract Res Clin Obstet Gynaecol* 2018;49:53–65.
- Baschat AA. Fetal growth restriction - from observation to intervention. *J Perinat Med* 2010;38:239–46.
- Gordijn SJ, Beune IM, Ganzevoort W. Building consensus and standards in fetal growth restriction studies. *Best Pract Res Clin Obstet Gynaecol* 2018;49:117–26.
- Romero R, Kusanovic JP, Chaiworapongsa T, Hassan SS. Placental bed disorders in preterm labor, preterm PROM, spontaneous abortion and abruptio placentae. *Best Pract Res Clin Obstet Gynaecol* 2011;25:313–27.
- Kovo M, Bar J, Schreiber L, Shargorodsky M. The relationship between hypertensive disorders in pregnancy and placental maternal and fetal vascular circulation. *J Am Soc Hypertens* 2017;11:724–9.
- Parra-Saavedra M, Crovetto F, Triunfo S, et al. Association of Doppler parameters with placental signs of underperfusion in late-onset small-for-gestational-age pregnancies. *Ultrasound Obstet Gynecol* 2014;44:330–7.
- Burton GJ, Jauniaux E. Pathophysiology of placental-derived fetal growth restriction. *Am J Obstet Gynecol* 2018;218:S745–61.
- Khong TY, Mooney EE, Ariel I, et al. Sampling and definitions of placental lesions: Amsterdam placental workshop group consensus statement. *Arch Pathol Lab Med* 2016;140:698–713.
- Chavhan GB, Babyn PS, Thomas B, Shroff MM, Haacke EM. Principles, techniques, and applications of T2*-based MR imaging and its special applications. *RadioGraphics* 2009;29:1433–49.
- Sinding M, Peters DA, Frøkjær JB, et al. Placental magnetic resonance imaging T2* measurements in normal pregnancies and in those complicated by fetal growth restriction. *Ultrasound Obstet Gynecol* 2016;47:748–54.
- Sinding M, Peters DA, Frøkjær JB, et al. Prediction of low birth weight: comparison of placental T2* estimated by MRI and uterine artery pulsatility index. *Placenta* 2017;49:48–54.
- Slator PJ, Hutter J, Palombo M, et al. Combined diffusion-relaxometry MRI to identify dysfunction in the human placenta. *Magn Reson Med* 2019;82:95–106.
- Sørensen A, Hutter J, Seed M, Grant PE, Gowland P. T2*-weighted placental MRI: basic research tool or emerging clinical test for placental dysfunction? *Ultrasound Obstet Gynecol* 2020;55:293–302.
- American College of Radiology Committee on MR Safety. ACR manual on MR safety. 2020. Available at: <https://www.acr.org/-/media/ACR/Files/Radiology-Safety/MR-Safety/Manual-on-MR-Safety.pdf>. Accessed October 31, 2021.
- Marsál K, Persson PH, Larsen T, Lilja H, Selbing A, Sultan B. Intrauterine growth curves based on ultrasonically estimated foetal weights. *Acta Paediatr* 1996;85:843–8.
- Parra-Cordero M, Lees C, Missfelder-Lobos H, Seed P, Harris C. Fetal arterial and venous Doppler pulsatility index and time averaged velocity ranges. *Prenat Diagn* 2007;27:1251–7.
- Brown MA, Magee LA, Kenny LC, et al. The hypertensive disorders of pregnancy: ISSHP classification, diagnosis & management recommendations for international practice. *Pregnancy Hypertens* 2018;13:291–310.
- Harris PA, Taylor R, Thielke R, Payne J, Gonzalez N, Conde JG. Research Electronic Data Capture (REDCap)—a metadata-driven methodology and workflow process for providing translational research informatics support. *J Biomed Inform* 2009;42:377–81.
- Robinson HP, Fleming JEE. A critical evaluation of sonar “crown-rump length” measurements. *Br J Obstet Gynaecol* 1975;82:702–10.
- Hadlock FP, Harrist RB, Sharman RS, Deter RL, Park SK. Estimation of fetal weight with the use of head, body, and femur measurements—a prospective study. *Am J Obstet Gynecol* 1985;151:333–7.
- Gómez O, Figueras F, Fernández S, et al. Reference ranges for uterine artery mean pulsatility index at 11–41 weeks of gestation. *Ultrasound Obstet Gynecol* 2008;32:128–32.
- Baschat AA, Gembruch U. The cerebroplacental Doppler ratio revisited. *Ultrasound Obstet Gynecol* 2003;21:124–7.
- Sinding M, Peters DA, Frøkjær JB, Christiansen OB, Uldbjerg N, Sørensen A. Reduced placental oxygenation during subclinical uterine contractions as assessed by BOLD MRI. *Placenta* 2016;39:16–20.
- Marquardt DW. An algorithm for least-squares estimation of nonlinear parameters. *J Soc Ind Appl Math* 1963;11:431–41.
- Sinding M, Peters DA, Poulsen SS, et al. Placental baseline conditions modulate the hyperoxic BOLD-MRI response. *Placenta* 2018;61:17–23.
- Gjerris AC, Pinborg A, Shalimi A-C, et al. Guideline on intrauterine growth restriction. 2014. Available at: <http://static.quarespace.com/static/5467abcce4b056d72594db79/546e7748e4b0d969a4f6cf10/546e7746e4b0d969a4f6cc60/1395263284000/FGR.pdf?format=original>. Accessed October 31, 2021.
- ACOG Practice Bulletin No. 204 summary: fetal growth restriction. *Obstet Gynecol* 2019;133:390–2.
- Ho AEP, Hutter J, Jackson LH, et al. T2* placental magnetic resonance imaging in preterm preeclampsia: an observational cohort study. *Hypertension* 2020;75:1523–31.
- Morgan TK. Role of the placenta in preterm birth: a review. *Am J Perinatol* 2016;33:258–66.
- Burton GJ, Redman CW, Roberts JM, Moffett A. Pre-eclampsia: pathophysiology and clinical implications. *BMJ* 2019;366:l2381.
- Sebire NJ, Sepulveda W. Correlation of placental pathology with prenatal ultrasound findings. *J Clin Pathol* 2008;61:1276–84.
- Madsen H. Fetal oxygenation in diabetic pregnancy. With special reference to maternal blood oxygen affinity and its effectors. *Dan Med Bull* 1986;33:64–74.
- Scifres CM, Parks WT, Feghali M, Caritis SN, Catov JM. Placental maternal vascular malperfusion and adverse pregnancy outcomes in gestational diabetes mellitus. *Placenta* 2017;49:10–5.
- Thunbo MØ, Sinding M, Bogaard P, et al. Postpartum placental CT angiography in normal pregnancies and in those complicated by diabetes mellitus. *Placenta* 2018;69:20–5.
- Parra-Saavedra M, Crovetto F, Triunfo S, et al. Placental findings in late-onset SGA births without Doppler signs of placental insufficiency. *Placenta* 2013;34:1136–41.
- Parra-Saavedra M, Simeone S, Triunfo S, et al. Correlation between histological signs of placental underperfusion and perinatal morbidity in late-onset small-for-gestational-age fetuses. *Ultrasound Obstet Gynecol* 2015;45:149–55.

Author and article information

From the Department of Clinical Medicine, Aalborg University, Aalborg, Denmark (Drs Hansen, Christiansen, Frøkjær, and Sørensen); Department of Obstetrics and Gynecology, Aalborg University Hospital, Aalborg, Denmark (Drs Hansen, Sinding, Christiansen, and Sørensen); Department of Pathology, Aalborg University Hospital, Aalborg, Denmark (Dr Petersen); Department of Obstetrics and Gynecology, Aarhus University Hospital, Aarhus, Denmark (Dr Uldbjerg); Department of Clinical Engineering, Central Denmark Region, Aarhus, Denmark (MSc, PhD, Peters); Department of Radiology, Aalborg University Hospital, Aalborg, Denmark (Dr Frøkjær).

Received Nov. 2, 2021; revised Jan. 12, 2022; accepted Jan. 27, 2022.

The authors report no conflict of interest.

This study was funded by The Health Research Foundation of North Denmark Region, reference number 2017-001222 (D.N.H.) and The Axel Muusfeldts Fund, reference number 2017-831 (D.N.H.). None of the funding sources have access to data or claim any rights to the results of this study. The funding sources had no involvement in study design, data collection, interpretation of data, writing the manuscript, or the decision to publish this study.

Corresponding author: Ditte N. Hansen, MD, PhD. ditte_n_hansen@hotmail.com